

Amusia due to Right Temporoparietal Infarct

H. Richard McFarland, MD, David Fortin, MD

● An accomplished organist, who could neither read nor write music, suddenly lost his ability to play familiar melodies as the result of an infarction of the right superior temporal and supramarginal gyri. Although the patient had minor difficulty recognizing familiar melodies and coordinating his hands, he had mainly an expressive instrumental amusia. This case provides further evidence of right hemispheric dominance for musical execution, relatively independent of musical knowledge and training.

(Arch Neurol 1982;39:725-727)

Amusia is an impaired capacity for musical activity.¹ Sensory (receptive) amusia comprises an inability to hear, read, or understand music (musical agnosia), whereas motor (expressive) amusia is difficulty in singing or writing music or in instrumental performance.² The patient described herein was not trained in theory or sight reading but was able to reproduce on the organ melodies he heard. He experienced expressive, instrumental amusia as the result of a right temporoparietal lobe infarct.

REPORT OF A CASE

A 78-year-old, right-handed man enjoyed good health until June 4, 1980, when without warning he sneezed eight times in succession and thereafter was unable to play the organ. Although he could still strike notes and form some chords, he could neither place them into a melodious sequence nor make his right and left hands coordinate properly. Two weeks later, when he was seen in neurologic consultation, he admitted to being less alert, forgetting familiar names, and enunciating improperly. On neurologic examination he was alert, oriented, and had a mild degree of dysarthria. His BP was 165/90 mm Hg and his pulse was irregular. Minimal astereognosis was found in the left hand. He had a fine action tremor and a hesitancy in walking. The remainder of the neurologic examination results were normal. The EEG showed focal slowing in the right temporoparietal region. Computed tomographic (CT) scan of the head June 20 showed an acute right temporoparietal cerebral infarct with luxury perfusion. A

second CT scan on July 11 demonstrated a cerebral infarct in the region of the right superior temporal and supramarginal gyri (Figs 1 through 3). A complete speech and language evaluation on July 2 revealed no dyspraxia or dysarthria. Results of the Boston Diagnostic Aphasia Examination were normal. He was able to recite rhymes, sing a song, and imitate rhythm. He had mild difficulty drawing figures in perspective and copying stick figures. An audiometric screening test was given in a non-sound-treated room, and his hearing sensitivity was within normal limits for his age. On Oct 1, the patient was tested (by H.R.M.) at the organ using the Dorgeuille

test battery.³ He had considerable difficulty reproducing rhythmic patterns of simple and universally familiar melodies on the organ. Although he perceived the melody in his mind, he could not make his hands correctly reproduce the melody. What he produced was garbled and did not sound correct to him. He also had some difficulty identifying familiar melodies, but no difficulty discriminating sounds or identifying types of music or musical instruments. He did recognize his favorite melodies as familiar. He was able to play his favorite melodies at this time, albeit with numerous missed notes and chords and poor syncopation. One year after his

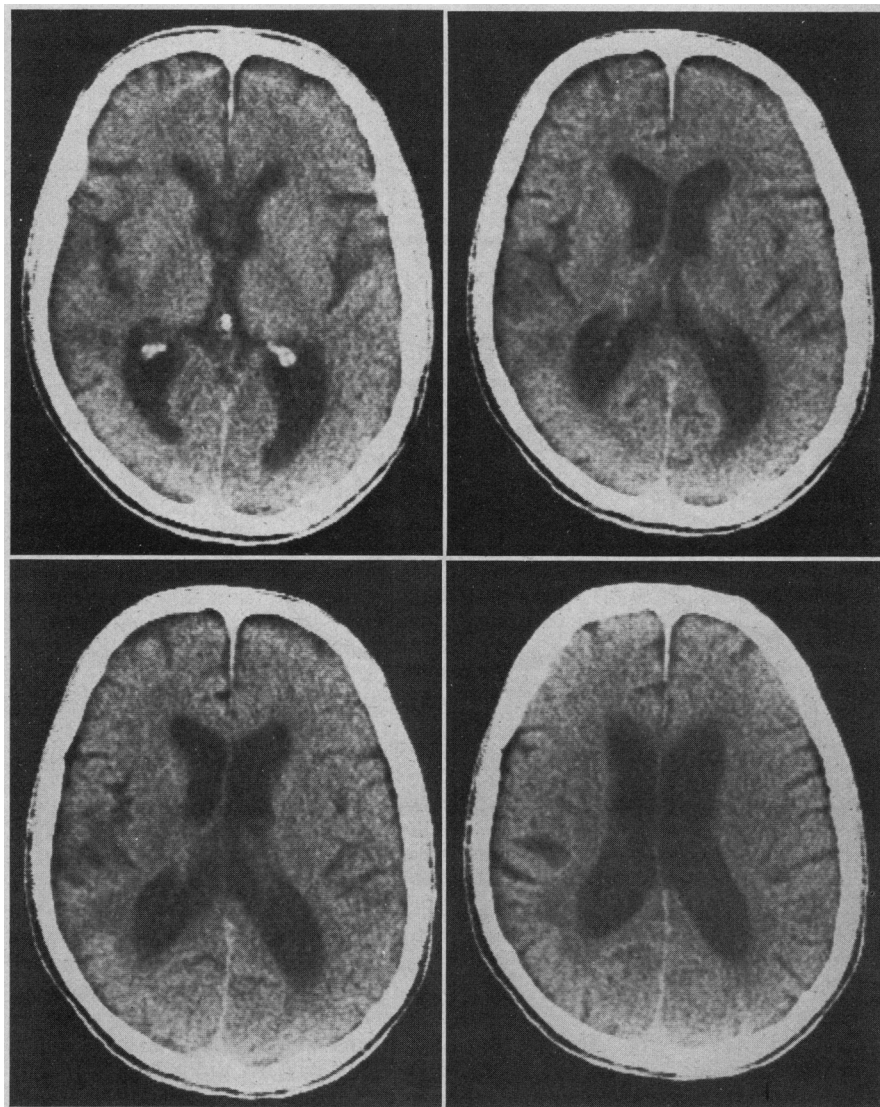


Fig 1.—Non-contrast-enhanced images from 55 to 70 mm above orbitomeatal line obtained July 11, 1980, showing irregular, radiolucent lesion in right temporoparietal region adjacent to sylvian fissure involving superior temporal and supramarginal gyri.

Accepted for publication Dec 31, 1981.

From the Departments of Neurology (Dr McFarland) and Radiology (Dr Fortin), St Luke's Hospital, Kansas City, Mo, and the Department of Neurology, University of Kansas Medical Center, Kansas City (Dr McFarland).

Reprint requests to 4320 Wornall Rd, Suite 620, Kansas City, MO 64111 (Dr McFarland).

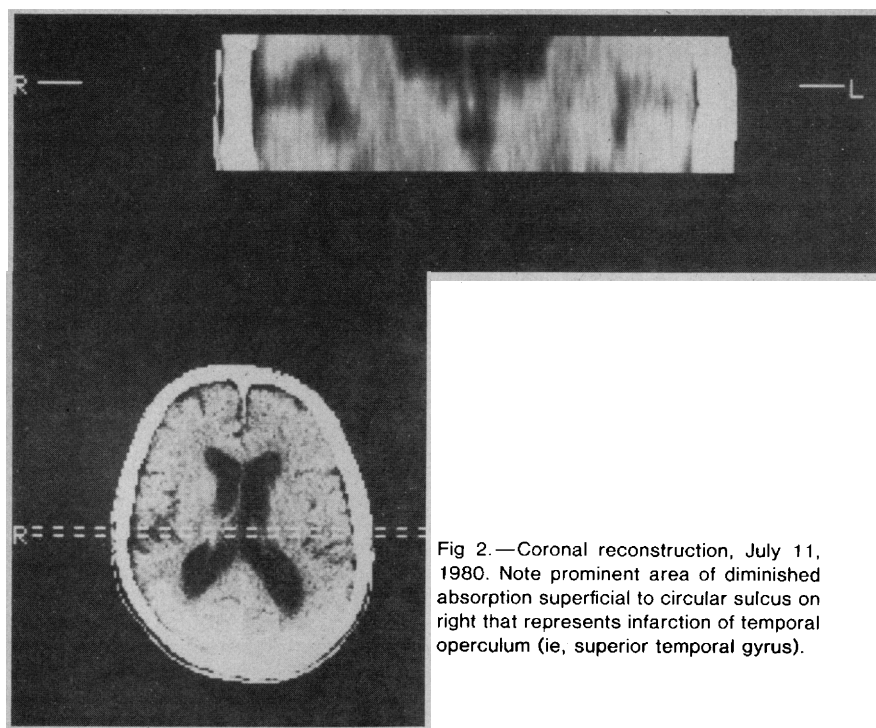


Fig 2.—Coronal reconstruction, July 11, 1980. Note prominent area of diminished absorption superficial to circular sulcus on right that represents infarction of temporal operculum (ie, superior temporal gyrus).

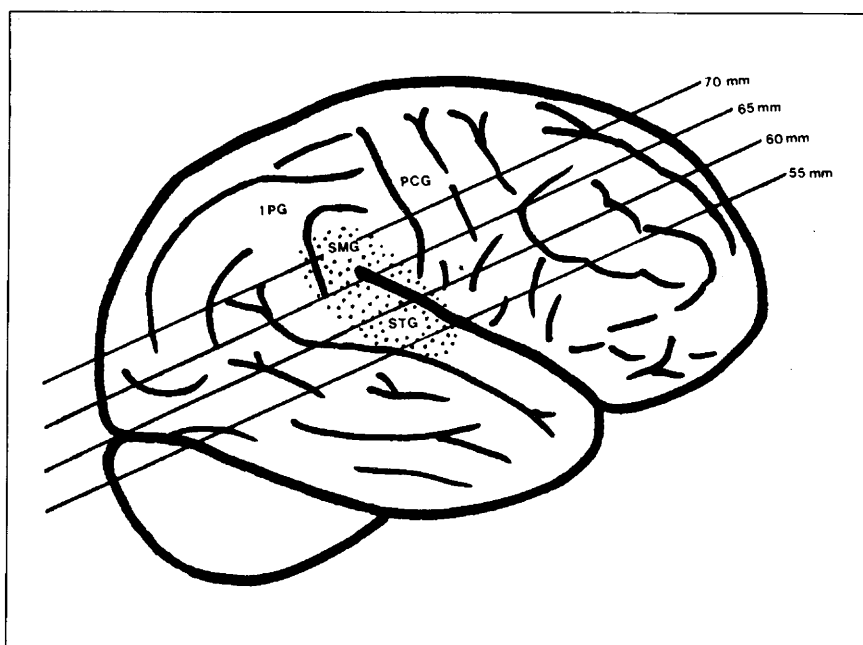


Fig 3.—Schematic localization of four slices of examination of July 11, 1980 (shown in Fig 2); stippled area represents lesion. IPG indicates inferior parietal gyrus; PCG, posterior central gyrus; SMG, supramarginal gyrus; and STG, superior temporal gyrus.

stroke, he refrains from playing the organ because his production is inaccurate and not melodious.

COMMENT

Penfield and Perot⁴ found that musical hallucinations were evoked with stimulation of the superior or lateral surface of the first temporal convolution on either side, but more on the right than on the left. Follow-

ing right temporal lobectomy for epilepsy, Milner⁵ recognized an impairment of certain kinds of auditory discrimination, comparison of tonal patterns and judgment of tonal quality. This pattern did not occur after left temporal lobectomies. After right temporal lobectomy, Shankweiler⁶ noted deterioration of melody recognition. Grison⁷ described a number of

patients with right hemispheric disease who could not identify melodies. Right hemispheric lesions have resulted in difficulty with musical perception and rhythm appreciation.⁸⁻¹⁰ Following right carotid amobarbital injection into right-handed subjects, Gordon and Bogen¹¹ observed transient expressive amusia. Benton's³ analysis of the clinical literature suggests that pure expressive amusia with preservation of receptive functions and without aphasia is most likely to be associated with lesions of the right hemisphere. Recently Damasio and Damasio¹² accepted the right hemisphere as dominant for musical execution and perception, independent of musical knowledge and training.

Conversely, left temporoparietal lesions may not produce amusia.⁵ Assal¹³ described a pianist who suffered from Wernicke's aphasia and word deafness following an embolic lesion of the left temporoparietal region who did not have any defect in his musical ability. (For a recent review of this subject, see Brust.¹⁴)

The patient was a "naïve" musician and not musically educated. Beaver and Chiarello¹⁵ called attention to the possibility that, according to the subject's contact with music, different nervous structures may be engaged in the processing of musical stimuli and that a melody, regardless of its being composed by a series of isolated notes, may be either perceived in terms of its overall melodic contour or as an organized arrangement of components. Beaver and Chiarello concluded that naïve listeners and musicians do, in fact, perceive melodies in a gestalt fashion and that the processing is predominantly in the right hemisphere.

In conclusion, lesions of the right hemisphere may cause both motor and sensory amusia. The case described provides further evidence that the right hemisphere is dominant for musical execution.

References

1. Wertheim N: Is there an anatomical localization for musical faculties? in Critchley M, Henson PA (eds): *Music and the Brain*. London, William Heinemann Medical Books Ltd, 1977, pp 282-297.
2. Henson RA: Neurological aspects of musical experience, in Critchley M, Henson PA (eds): *Music and the Brain*. London, William Heinemann Medical Books Ltd, 1977, pp 3-21.
3. Benton AL: The amusias, in Critchley M, Henson PA (eds): *Music and the Brain*. London, William Heinemann Medical Books Ltd, 1977, pp 378-397.
4. Penfield W, Perot P: The brain's record of auditory and visual experience. *Brain* 1963;86:595-696.

5. Milner B: Laterality effects in audition, in Mountcastle VB (ed): *Hemispheric Relations and Cerebral Dominance*. Baltimore, Johns Hopkins Press, 1962, pp 107-195.

6. Shankweiler D: Effects of temporal lobe damage on perception of dichotically presented melodies. *J Comp Physiol Psychol* 1966;62:115-119.

7. Grison B: *Une etude sur les alterations musicales au cours des lesions hemispheriques*, thesis. Paris, 1972.

8. Kohl GF, Tschabitscher H: Über einen Fall von Amusie. *Wein Z Nervenheilkd Grenzgebiete*

1953;6:219-230.

9. Pittrich H: *Sensorische Amusie mit paramusie nach rechtsseitiger Temporalverletzung*, film. Göttingen, Germany, Göttingen Institute für den Wissenschaften Film, 1956.

10. Potzl O: Zur Pathologie der Amusie. *Z Gesamte Neurol Psychiatr* 1939;165:187-195.

11. Gordon HW, Bogen JE: Hemispheric lateralization of singing after intracarotid sodium amylorbarbitone. *J Neurol Neurosurg Psychiatry* 1974;37:727-738.

12. Damasio H, Damasio AR: Musical faculty and cerebral dominance, in Critchley M, Henson

PA (eds): *Music and the Brain*. London, William Heinemann Medical Books Ltd, 1977, pp 141-155.

13. Assal G: Aphasie de Wernicke sans amusie chez un pianiste. *Rev Neurol* 1973;129:251-256.

14. Brust JCM: Music and language: Musical alexia and agraphia. *Brain* 1980;103:367-392.

15. Beaver TJ, Chiarello RJ: Cerebral dominance in musicians and non-musicians. *Science* 1974;185:537.

Hypermagnesemic Periodic Paralysis

Treatment With Digitalis and Lithium Carbonate

Wendelin Emser, MD

● An 18-year-old man suffering from a hereditary hyperkalemic periodic paralysis showed, in addition, a hypermagnesemic periodic paralysis with a 2.5-fold increase in serum magnesium level. All other serum electrolyte levels were normal. The hypermagnesemic periodic paralysis seems to have been caused by a disturbance of the renal tubular system. Thus, magnesium-stimulated paralysis was prevented by treatment with lithium carbonate and digitalis, which blocked the active ion transport.

(*Arch Neurol* 1982;39:727-730)

An 18-year-old man was ordered to report to an army recruiting station but sought medical advice because he believed himself to be unfit for military service. The young man, his mother, brother, and sister, and other relatives (Fig 1) had a hyperkalemic periodic paralysis^{1,2} with myotonic signs. This combination has also been reported in other patients.^{3,6}

The short-lasting hyperkalemic weakness did not bother the young man. It was the occurrence of longer-lasting and severe paralyzes that worried him, since none of the other family members showed these symptoms.

REPORT OF A CASE

The patient had his first attack of periodic paralysis at the age of 6 years. The attacks were mild, lasted ten to 20 minutes, started with lingual myotonia, lid-lag, and

myotonic signs in the face, and sometimes spread to limb muscles before the actual paresis occurred. The attacks were hyperkalemic.

When the patient was 12 years old, another type of periodic paralysis began. It was much more prolonged and more severe, had no preceding myotonic symptoms, occurred every four to six weeks, and lasted six to eight days. Typically, the weakness started without other symptoms when he awoke; the patient noticed a weakness of the distal muscles of the lower extremities, especially of those muscles responsible for foot elevation; this resulted in a foot-slapping gait.

During the course of one to two days and in conjunction with the increasing serum magnesium level, the weakness spread to the forearm muscles such that the patient had difficulty making a fist. Often the proximal leg muscles became affected, and the patient had difficulties in walking up stairs and in coming up from a squatting position. The weakness thus manifested itself for about three to four days. The recovery from this periodic paralysis spanned two days but the muscles first affected were the last to improve. During recovery, the patient believed that he had to urinate more often. The trunk muscles were seldom involved, being affected at the most once a year. In this case, elevation from a lying or squatting position was severely impeded. Sometimes, even after feet and hand extensors were affected, the paralysis ceased and showed no further signs of progression.

Respiratory, facial, and esophageal muscles were never affected. The patient never noticed any symptoms of the developing paralysis or any other discomfort.

Physical activities or other exogenous factors, such as nutrition, did not provoke this periodic paralysis. The patient was not taking any medication. If, by chance, he had driven a bicycle or strained his arms shortly before the weakness appeared, the used muscles then were affected more severely.

During the course of the paralysis, only weak reproducible reflexes were found during neurological examination. The patient could not stand on his heels or toes (Fig 2), coming up from a squatting position was clearly difficult, chair climbing was difficult, and hand strength was strongly reduced (Fig 3). The affected muscles had a weak tone and were not sensitive to pressure. Otherwise the neurological findings were normal.

Relatives of the patient (Fig 1) were available for questioning and examination. None of them complained about experiencing the same paralysis experienced by the patient. The relatives with hyperkalemic periodic weakness would only allow a serum electrolyte determination; this test produced normal magnesium values. No relatives were willing to subject themselves to further detailed clinical examination because they all felt well and their mild hyperkalemic periodic paralysis did not cause them any discomfort.

Between attacks, the patient showed no abnormalities on neurological examination, poorly developed reflexes, no myotonia after grasp or percussion, and no lid-lag; only a percussion myotonia of the tongue was detected.

LABORATORY FINDINGS

The ECG was normal between attacks; however during attacks high T waves appeared. Between attacks electromyography at the upper extremities showed "pseudomyotonic" discharges (bizarre high frequency) for 5 to 10 s with spontaneous activity known in patients with hyperkalemic paralysis.⁷ The muscles' volitional potentials were normal.

During hypermagnesemic periodic paralysis, neither spontaneous activity nor myotonic discharges could be detected. Investigations of the ulnar and median nerves with repetitive stimulation⁸ did not show a myasthen-

Accepted for publication Feb 15, 1982.

From the Department of Neurology, University Hospital, Homburg, Saar, West Germany.

Reprint requests to Neurologische Universitätsklinik, Universität des Saarlandes, 6650 Homburg/Saar-FRG (West Germany) (Dr Emser).