

Basilar Artery Occlusion in a Case of Duchenne Muscular Dystrophy

Toyojiro Matsuishi, MD, Eiji Yano, MD, Kenjiro Terasawa, MD,
Ikuya Nonaka, MD, Osamu Ishihara, MD,
Yoichiro Yamaguchi, MD and Toshio Okudera, MD

This is a report of a case of Duchenne muscular dystrophy (DMD), with multiple infarcts in the territories of the basilar artery. He developed abrupt vomiting and transient left hemiparesis at the age of 4 years. The episodes were seen 3 times between 4-year-1-month to 5-year-1-month old. Transaxial computerized tomography (CT) revealed multiple, well-defined but irregularly marginated areas of low density centered in the mid- and upper pons, right cerebral peduncle and thalamus. A right vertebral angiogram illustrated the narrowed basilar artery. The rectus femoris muscle was biopsied at the age of 4-year-1-month which showed marked variation in fiber size, myonecrosis with phagocytosis, central nuclei, and adipose and connective tissue proliferation, which were consistent with those seen in DMD. It remains unknown whether the basilar artery occlusion was an incidental event in this particular case or closely related to the disease process of DMD.

Matsuishi T, Yano E, Terasawa K, Nonaka I, Ishihara O, Yamaguchi Y, Okudera T. Basilar artery occlusion in a case of Duchenne muscular dystrophy. Brain Dev 1982;4:379-84

Progressive muscular dystrophy is a genetically determined disorder with progressive degeneration of skeletal muscle but with no structural abnormality in the central or peripheral nervous system [1]. However, recent clinical

studies revealed a number of cases of central nervous system involvement in DMD. In contrast to much clinical evidence, no significant pathological changes in the central nervous system have been described; the motor neurons of brain and spinal cord are said to be normal [2-4]. Although mental subnormality is quite common in DMD [1-4], whether or not mental retardation is related to anatomical abnormalities remains unknown. Only one paper described abnormal neuronal migration (heterotopic neurons) in the brains of markedly mentally retarded patients with DMD [4]. Slight cerebral atrophy may be observed on computerized tomography [5]; however, there is no remarkable change in the brain stem [2-5]. While the cause of vascular occlusion in the present case remains to be solved, we decided to describe this unusual case to draw further attention to the probable vascular abnormality in DMD.

From the Department of Pediatrics and Child Health, Kurume University School of Medicine, Kurume, Fukuoka (TM, EY, KT, OI, YY); Division of Neuro-muscular Research, National Center for Nervous, Mental and Muscular Disorders, Kodaira, Tokyo (IN); Department of Radiology, University of Fukuoka, Fukuoka (TO).

Received for publication: February 15, 1982.
Accepted for publication: June 28, 1982.

Key words: Duchenne muscular dystrophy, mental retardation, sensory deafness, basilar artery occlusion.

Correspondence address: Dr. Toyojiro Matsuishi, Department of Pediatrics, Kurume University School of Medicine, 67 Asahi-machi, Kurume, Fukuoka 830, Japan.

Case Report

A 4 years and 1 month old Japanese boy was admitted to our hospital because of episodes of vomiting, dehydration and general malaise. There was no consanguineous marriage. Neither muscular or metabolic disorders nor patient with mental retardation or deaf were known in the family. He was born at full term by vaginal delivery complicated by umbilical cord strangulation and moderate asphyxia. His birth weight was 3,050 gm.

His developmental milestones were slightly delayed; he obtained head control at 5 months, rolled over at 6 months, sat alone at 7 months, and learned to walk at 18 months when he was already noted to have Gowers' sign. He fell easily and was unable to run fast. His muscular condition progressively worsened. At the age of 4 years and 1 month he presented recurrent vomiting, dehydration, and left hemiparesis of sudden onset which prompted to be brought him to Kurume University Hospital. On admission, he was a slender boy with generalized muscle wasting and left hemiparesis. Height was 95.7 cm (-1.1 SD) and weight 13.8 kg (-1.2 SD). He was alert but had mental retardation (DQ: below 50) and sensory deafness. He had moderate generalized muscle weakness and stood up with Gowers' maneuver. When lying in the supine position, he was unable to raise his head because of notable neck muscle weakness. Enlargement of muscles, particularly the calves, was observed. Tendon jerks were accelerated with positive pyramidal signs on the left. There was no sensory deficit. Neither fasciculation nor percussion myotonia was noted. The other cranial nerves and ocular fundi were intact (Fig 1).

Laboratory examination showed normal urinalysis and CBC. Serum creatine kinase (CK) was 918 IU (normal; less than 40), aldolase 36 mU/ml (normal range; 0.5-3.1), lactic dehydrogenase 2366 WU (normal; less than 400), s-GOT 113 Karmen U/L, s-GPT 182 Karmen U/L, and alkaline phosphatase 9.9 U (normal; less than 10). Serum electrolytes and serum protein were within normal limits. The other results of blood chemistry included total cholesterol of 196 mg/dl, fasting glucose of 90 mg/dl and thyroxine of 12.0 µg/dl (normal range; 6.4-13.0). Acid base balance and lactate were normal. A chest X-ray was unremarkable.

Antinuclear antibody and LE cells were negative. A virological and bacteriological study showed elevated serum *Mycoplasma pneumoniae* titers (CF of $\times 64$, PHA $\times 160$; after 2 weeks, CF $\times 16$, PHA $\times 160$). ECG showed left ventricular hypertrophy, the sleep EEG was normal, and EMG showed a myopathic pattern. The cerebrospinal fluid was normal.

A routine transaxial CT scan without contrast media revealed multiple, well-defined but irregularly marginated small low density areas located in the mid- and upper pons, predominantly on the right side (Fig 2). Low density areas were also visible in the right cerebral peduncle and thalamus. These foci showed almost the same CT density as that of CSF. The pons was not enlarged and the pontine cistern was not narrowed. The shape and location of the fourth ventricle were within normal limits. There was no displacement or deformity of the

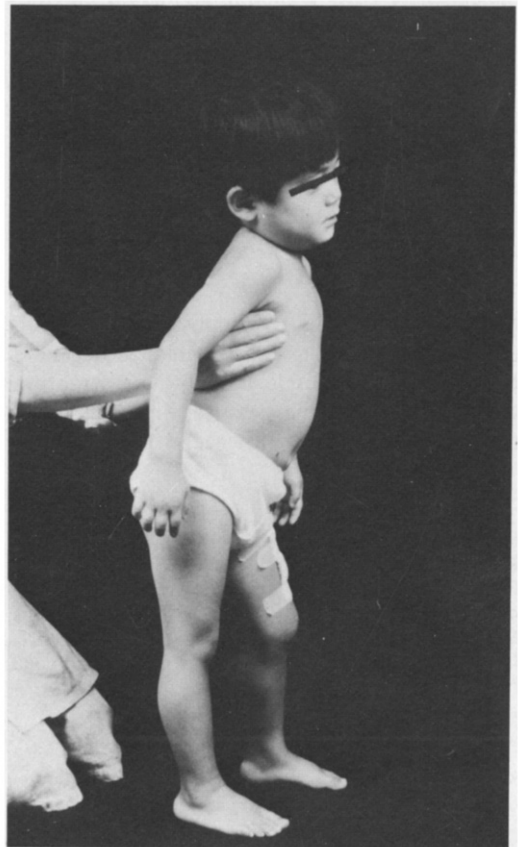


Fig 1 Patient at the age of 4 years, representing lordosis and generalized muscle wasting.

lateral and third ventricles. A right vertebral angiogram illustrated narrowing and irregularity in the proximal portion of the basilar artery (Fig 3). The above findings were thought to be caused by vascular lesion, probable multiple infarcts in the territory of the perforating branches originated from the proximal portion of the basilar artery.

A muscle biopsy specimen obtained from the left rectus femoris was stained by a battery of histochemical methods. The most striking findings in the present biopsy included a marked variation in fiber size, degenerative changes in muscle fibers, central nuclei, phagocytosis of necrotic muscle fibers, and adipose and connective tissue proliferation (Fig 4A). On ATPase

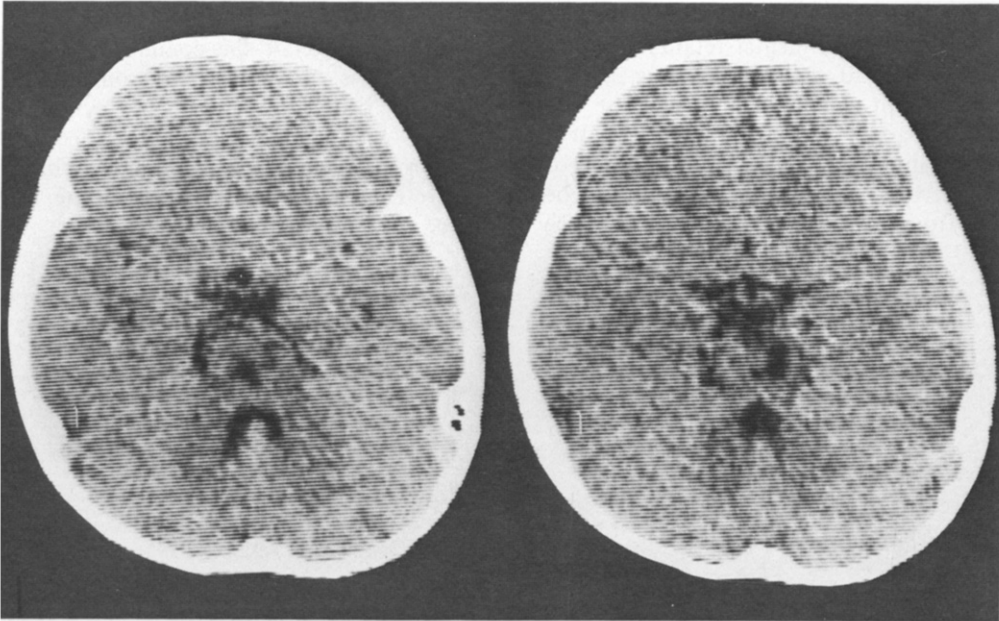


Fig 2 CT scan showing multiple, well-defined low density areas in the mid- and upper pons, cerebral peduncle on the right side.

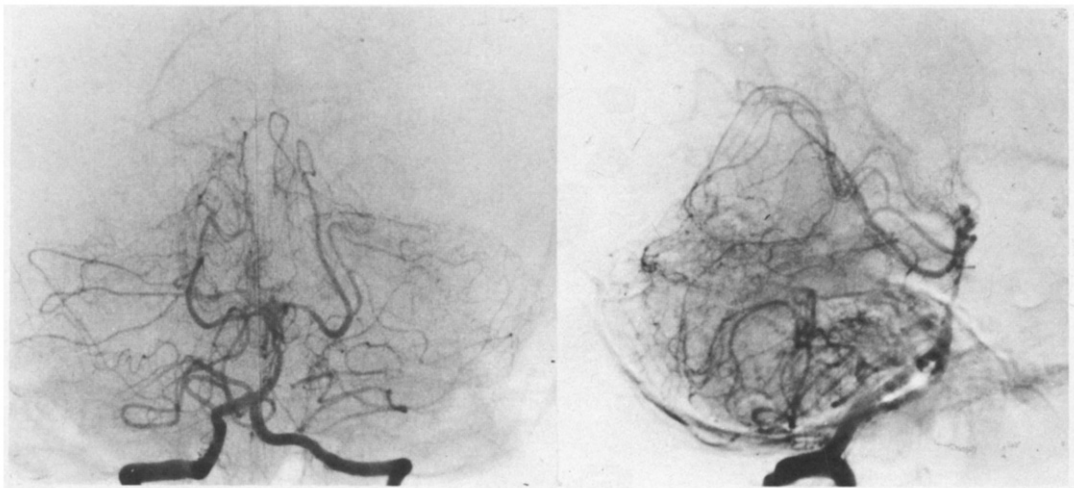


Fig 3 A right vertebral angiogram illustrates narrowed basilar artery in the proximal portion.

staining, both type 1 and type 2 fibers were seen to be involved (Fig 4B).

After discharge, he developed two similar mild attacks in one year, but with no significant neurological sequelae.

Discussion

From the clinical history, and pathological findings of the biopsied muscle, there is little doubt that the patient had been suffering from DMD. He had severe mental retardation with a DQ of below 50, sensory deafness, and in addition, abrupt vomiting and transient left spastic hemiparesis starting from the age of 4 years and 1 month. The recurrent symptoms of central nervous system were thought to be resulted from basilar artery occlusion which

was confirmed by vertebral angiogram and CT examinations.

The cause of the vascular change in the present case remains unknown. Although the serum PHA and CF titers of *Mycoplasma pneumoniae* were significantly elevated, no sufficient evidence was obtained to firmly judge whether or not he had any infectious process in the central nervous system.

The syndrome of vertebrobasilar insufficiency had been well described in adults [6] and in fact is one of the commonest neurological illnesses. In adults, atheroma is the commonest cause [6, 7], but the syndrome has been seen in association with cervical spondylosis, dissecting aneurysm and syphilitic aortitis. The subclavian steal syndrome will produce an identical clinical manifestation.

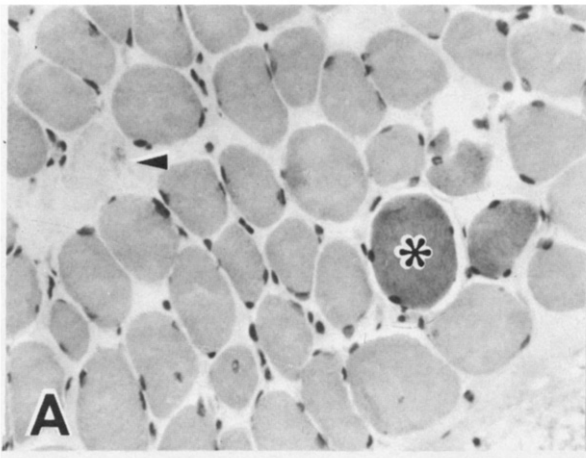
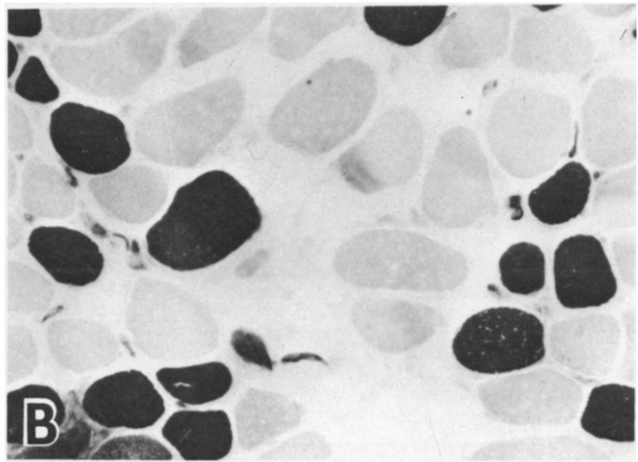


Fig 4 In the biopsied muscle, there are remarkable variation in fiber size, scattered necrotic (arrow head) and opaque fibers (asterisk), and adipose and connective tissue replacement. Both type 1 and type 2 fibers are involved. A; HE, B; routine ATPase A, B $\times 200$.



In contrast to the well-documented and frequent occurrence of vertebrobasilar occlusive disease in adults, to our knowledge only six cases have previously been reported in childhood. Two autopsied cases described by Fowler [8] revealed basilar artery occlusion and focal softening in the midbrain and thalamus. The other cases in the literature included an example of spontaneous basilar artery thrombosis of unknown etiology, occurring in a previously well child at six years of age [9]. Ouvrier et al [7] found only three cases of occlusive disease of the vertebrobasilar system in 162 patients with cerebrovascular disease. One patient had recurrent episodes of vertigo for several months, and later developed dysarthria, ataxia and hemiparesis together with fluctuating ocular paresis. Arteriography showed widespread changes in the vertebrobasilar system similar to those seen in "arteritis." The cause in their second case was not established. The third case developed sudden coma in the course of bacterial endocarditis and angiography showed an attenuated basilar artery presumably due to embolism. These conditions seem to be rare in childhood.

In our case, the angiogram showed a partially occluded basilar artery with an irregular and beaded contour predominantly seen in the proximal portion. Since the finding was somewhat similar to that seen in "arteritis" [10], the possibility of a focal inflammatory process in the artery caused by *Mycoplasma pneumoniae* remains to be considered.

Although the pathogenesis of DMD is unknown, three major hypotheses for the induction of myonecrosis have been proposed; membrane, neurogenic and vascular theories. The major proponent of the vascular theory is now Engel and his associates, who was led to the concept of a vascular disorder by the observation of aggregated necrotic muscle fibers in the biopsies [11, 12]. The appearance of these group lesions suggested that they might arise from occlusion of or at least inadequate flow in small vessels within muscle. Similar lesions were reproduced in animals by injection of minute plastic spheres or by ligation of the aorta [12]. Clinically, Boranic et al [13] described vascular changes, epilepsy, oligophrenia and a peptic ulcer in a 10-year-old boy with progressive muscular dystrophy. They speculated that these coincidental clinical symptoms

might have resulted from impaired blood supply not only to the muscle and gastrointestinal tract but also to the central nervous system. Despite the many clinical and pathological possibilities of inadequate blood supply in small vessels in DMD [11, 13, 14], no vascular change in major vessels as seen in the present case has been described. Therefore it remains to be solved as to whether the vascular occlusion in the basilar artery in the present case was an incidental event caused by an inflammatory or other etiological process, or closely related to the basic defect in DMD.

References

1. Dubowitz V. *Muscle disorders in childhood*. London-Philadelphia-Toronto: WB Saunders, 1978:22-42.
2. Rowland LP, Layzer R. X-linked muscular dystrophies. In: Vinken PJ, Bruyn GW, eds. *Handbook of clinical neurology*. Vol 40. Amsterdam-New York-Oxford: North Holland Pub Co., 1979:349-87.
3. Dubowitz V, Crome L. The central nervous system in Duchenne muscular dystrophy. *Brain* 1969;92:805-8.
4. Rosman NP. The cerebral defect and myopathy in Duchenne muscular dystrophy. *Neurology* 1970;20:329-35.
5. Yoshioka M, Okuno T, Honda Y, Nakano Y. Central nervous system involvement in progressive muscular dystrophy. *Arch Dis Child* 1980; 55:589-94.
6. Marshall J. A survey of occlusive disease of the vertebrobasilar arterial system. In: Vinken PJ, Bruyn GW, eds. *Handbook of clinical neurology*. Vol 12. Amsterdam-New York-Oxford: North Holland Pub Co., 1972:1-36.
7. Ouvrier RA, Hopkins IJ. Occlusive disease of the vertebrobasilar arterial system in childhood. *Dev Med Child Neurol* 1970;12:186-92.
8. Fowler M. Two cases of basilar artery occlusion in childhood. *Arch Dis Child* 1962;37:78-81.
9. Dooley JM, Smith KR. Occlusion of the basilar artery in a six years old boy. *Neurology* 1968; 18:1034-6.
10. Banker BQ. Cerebral vascular diseases in infancy and childhood. I. Occlusive vascular disease. *J Neuropathol Exp Neurol* 1961;20:127-40.
11. Engel WK, Hawley RJ. Focal lesions of muscle in peripheral vascular disease. *Neurology* 1977;215: 161-8.
12. Mendell JR, Engel WK, Derrer EC. Increased plasma enzyme concentrations in rats with functional ischemia of muscle provide a possible

- model of Duchenne muscular dystrophy. *Nature* 1972;239:522-4.
13. Boranić M, Žeškov P, Šantel D, Ivkovič T. Vascular changes, epilepsy, oligophrenia and peptic ulcer in a child with progressive muscular dystrophy. *Period Biol* 1981;83:251-5.
14. Kohler J. Blood vessel structure in Duchenne muscular dystrophy. 1. Light and electron microscopic observations in resting muscle. *Neurology* 1977;27:861-8.