

NOTE

OCULOMOTOR DISTURBANCES IN BALINT'S SYNDROME: ANATOMOCLINICAL FINDINGS AND ELECTROOCULOGRAPHIC ANALYSIS IN A CASE

Floriano Girotti, Clara Milanese, Marina Casazza, Antonio Allegranza, Franco Corridori and Giuliano Avanzini

(Istituto Neurologico "C. Besta," Milano)

INTRODUCTION

Peculiar oculomotor disorders that occur in patients with bilateral cortical lesions are usually reported under the eponym of Balint's syndrome, which is defined as a combination of paralysis of visual fixation, optic ataxia and disturbance of visuo-spatial attention. Actually, the first complete report of the typical oculomotor symptomatology was by Holmes (1918) in patients with bilateral gunshot hemispherical wounds. In most of the subsequent observations (Hécaen, Ajuriaguerra, Rouques, David and Dell, 1950; Hécaen and Ajuriaguerra, 1954; Luria, 1959; Waltz, 1961; Saraux, Esteve, Graveleau and Goupil, 1962; Luria, Pravdina-Vinarskaya and Yarbuss, 1963; Godwin-Austen, 1965; Michel, Jeanerod and Devic, 1965; Tyler, 1968; Sorgato, 1976; Damasio and Benton, 1979; Hausser, Robert and Giard, 1980) the clinical picture was seldom complete, more often it consisted of only some of the typical signs. In all of the cases the diagnostic marker was the peculiar oculomotor symptomatology, which is reviewed in Table I. Differences in terminology sometimes make it difficult to identify the specific elements common to all the cases. Moreover, the differentiation with otherwise defined oculomotor syndromes (visual disorientation [Godwin-Austen, 1965], oculomotor apraxia [Cogan and Adams, 1953], and "simultanagnosia" [Luria et al., 1963]) is not always clear.

It therefore seemed of interest to report the oculomotor findings of a patient who presented disturbances of visual orientation and was studied with the electrooculographic (EOG) technique. The results are discussed with respect to the anatomical lesions shown by the postmortem examination.

CASE REPORT

The patient, a 67-year-old man, was admitted to our hospital in September 1979, after the sudden onset of a left hemiparesis. In 1975 the patient had occasionally complained of dizziness and moderate unsteadiness, which did not prevent him from working regularly as a commercial agent. In 1978 a visual deficit affecting the right hemifield suddenly occurred; it was associated with a transitory memory failure and unsteadiness. A cerebral CT scan performed in another hospital showed a left parieto-occipital malacic area. The patient recovered from right hemianopia in almost 1 month and began working again. In June 1979 a new visual disturbance appeared: the patient could identify familiar objects, such as cigarettes laying on his table, only with great difficulty, and he

saw them distorted. Peculiar perceptive changes were reported by his relatives: while watching a car race on television, the patient could distinguish an advertisement on the screen, but he neither "saw" nor identified the rapidly running racing cars. On other occasions he could not clearly see people with him in the room, but he accurately identified an electrical switch placed at some meters distance from him.

In June 1979 a further cerebral CT scan performed elsewhere showed two hypodense areas localized respectively in the right occipito-basal and the left parieto-occipital hemispherical regions. At the end of August 1979 an acute left hemiparesis prompted the admission to our hospital.

On admission blood pressure was 160/90 mm Hg, and heart rate 64 beats/minutes. Neurological examination showed a left hemiparesis more severe at the upper extremity; deep reflexes were hyperactive on the same side, a left Babinsky sign was present. Tactile and painful stimuli were appreciated normally, and there was no loss of vibratory or position sense.

The head and eyes deviated toward the right, and the gaze often seemed locked in fixation. The pupillary reflex to light was normal on both sides. There was a complete paralysis of upward gaze, while downward movement following the finger of the examiner could normally be elicited. Convergence movement was absent. The optokinetic nystagmus in the vertical and horizontal plane was abolished. The oculocephalic reflexes (doll's-eye movements) in response to brisk downward and upward head movements were normally elicitable. Horizontal movements toward the left could not be elicited, either by verbal command or by displacing a target. Spontaneous, leftward to and from horizontal movements were occasionally observed. When he was asked to move his eyes toward an eccentric target in his right hemifield, he looked "blindly" for it in wandering-like fashion, and was unable to find it. Only sometimes did he succeed randomly in reaching the target. On other occasions we observed an exaggerated fixation, with difficulty to divert his gaze from the primary to a right eccentric position. We also noticed an important disturbance in the manual localization of objects under visual control: this trouble, defineable as "optic ataxia," could be evaluated only for the right upper extremity due to the severe left paresis. Localization of objects by finger pointing was consistently inaccurate in both visual hemifields. The movement was hesitant and started 7-8 seconds after the target's presentation. The misposition was subsequently adjusted by corrective movements.

The patient's condition remained stationary for 3 weeks, then he died suddenly from a pulmonary embolism.

Neuropsychological Evaluation

The patient was alert and there was no impairment of consciousness, language or memory. He always recognized and read single letters; he succeeded in reading a single word only with difficulty, but he was not able to read an entire sentence. He could copy single letters, but neither words nor sentences. His signature was very irregular and almost illegible. In the drawing test he correctly copied only single geometric figures, such as triangles or squares. These figures were badly oriented with regard to their axis and displaced on the sheet of paper: in fact, they were often placed close to the models or on the right side of the sheet.

The patient easily recognized familiar objects (such as keys, pipe, scissors etc.) when presented one by one, but he failed in this task (or he found great difficulty in performing it) when these objects were presented together. The performance

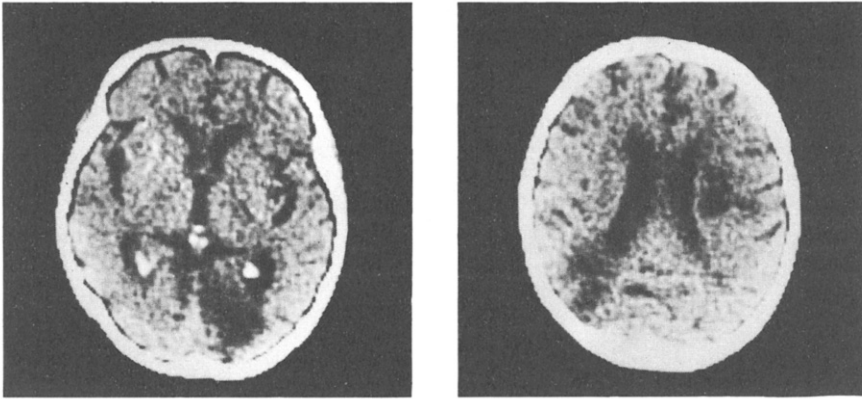


Fig. 1 — CT scan showing three hypodense areas in the left and right occipital lobe and the right periventricular white matter.

improved when his attention was focused by pointing to the object. He correctly identified 20 elemental figures (such as a dog, house, tree or flower) and discriminated well the fundamental colors.

There were no defects in recognizing sounds and their localization within the extracorporeal space. The body parts were correctly recognized and named.

Instrumental Tests

Conventional perimetry revealed a bilateral superior hemianopia and a defect in the right lower quadrant, with sparing of the central vision.

A CT brain scan (Figure 1), performed at the same time, showed a moderate widening of the lateral and third ventricles, the cortical sulci and the subarachnoid spaces. Three hypodense areas were evident, in the left parieto-occipital lobe, the right occipital lobe and the right periventricular area, at the level of the middle horn.

Postmortem Examination

The brain weighed 1200 g. The basal arteries showed signs of severe arteriosclerosis; the left vertebral artery appeared much more reduced than the contralateral one. A left occipital area of metamalacic sclerosis involving the middle lateral gyrus was noted (Figure 2a). This area extended anteriorly to the boundary of the middle temporal gyrus. The angular gyrus was not involved. The gyri surrounding the left calcarine fissure were irregularly retracted, sparing the occipital pole. The lower half of the striated area was the most severely involved; the lesion extended anteriorly into the lingual gyrus and the deep white matter.

A large depression due to a metamalacic sclerosis was also evident on the inferior surface of the right occipital lobe, particularly on the posterior half of the fusiform gyrus (Figure 2b). This lesion measured antero-posteriorly almost 4 cm

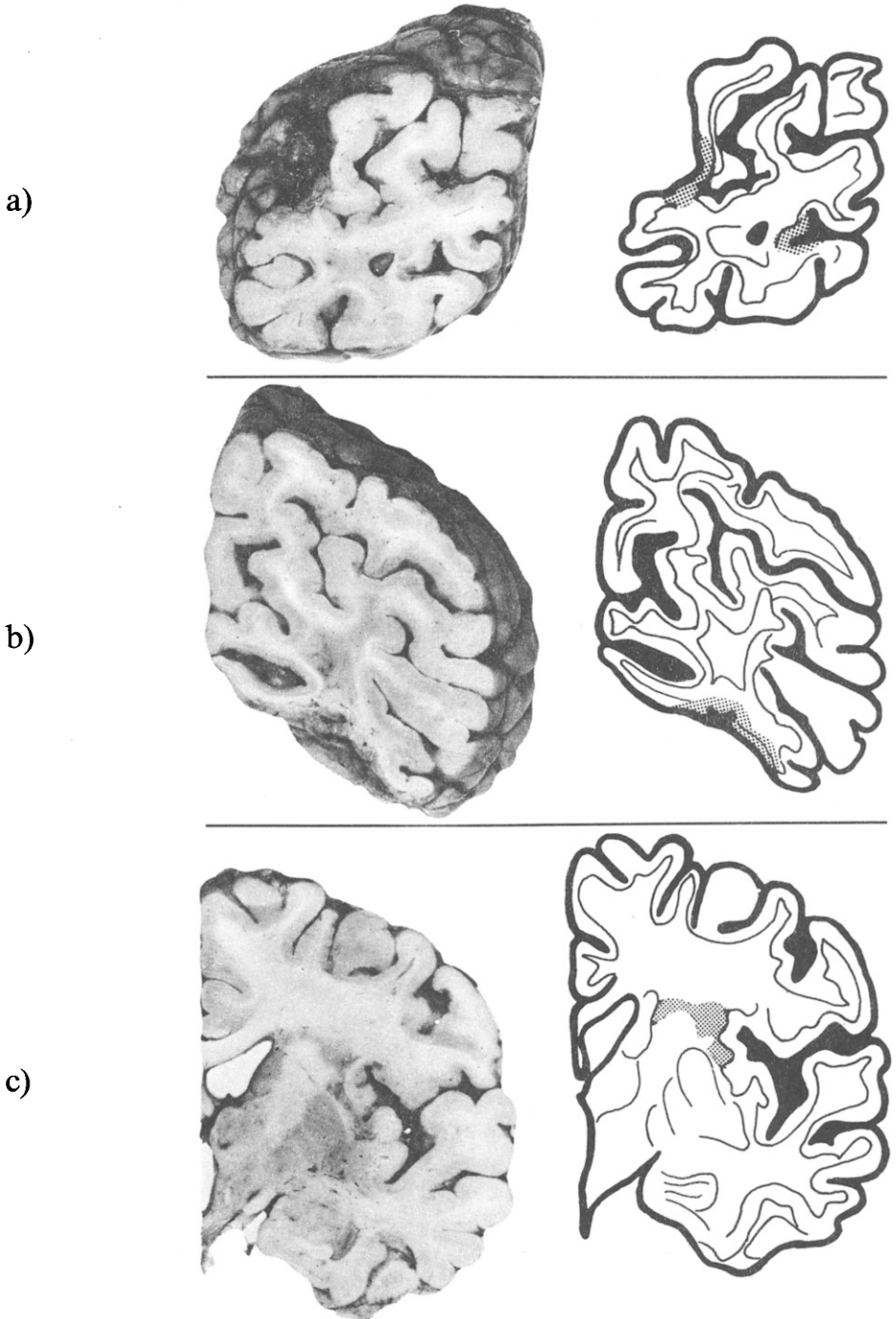


Fig. 2 — Coronal sections showing malacic areas in the left (a) and right (b) occipital lobes and the white matter at the boundary between the right internal capsule and centrum semi-ovale (c).

in diameter but did not reach the right occipital pole; it extended into the severely damaged lingual gyrus and the inferior lip of the calcarine cortex.

Anterior coronal sections showed multiple small malacic areas that affected the right superior peri-insular bank and the boundary between the right internal capsule and the ipsilateral centrum semiovale (Figure 2c). The right occipital horn was enlarged because of severe atrophy of the ipsilateral lingual gyrus. The cerebellum and the brainstem showed a moderate diffuse atrophy, but no signs of focal lesions.

EOG Recording

During the examination the patient was sitting on a chair with a headholder, in front of a semicircular screen, in semidarkness. Binocular recording was performed with Beckman electrodes, coupled with a D.C. amplifier, and visualized on a cathode ray oscilloscope. Horizontal refixation saccades were elicited by a spot of light (brightness 0.222 candles, subtended diameter 0.5 degree), lit randomly on a screen at 30 degrees to either side of center. The following saccadic parameters were considered (see Figure 3): (1) the latency of the saccade (or reaction time); (2) the visual search time, i.e., the time required to reach the eccentric target; (3) the number of saccades required to reach the target; (4) the amplitude of every single eye movement; (5) the intersaccadic interval, in the case of corrective saccades.

Smooth pursuit movements were elicited by a target moving at a speed of 15 degrees/second on the screen, from the central fixation point to an eccentric position and back in both hemifields. In response to passive head movements, doll's-eye movements of normal amplitude were elicited in both hemifields (Figure 4a). All other kinds of eye movements were completely abolished in the left hemifield. The EOG analysis was therefore limited to the right hemifield. In this direction, saccades of small amplitude (mean value 11.7 ± 3.08 degrees) were

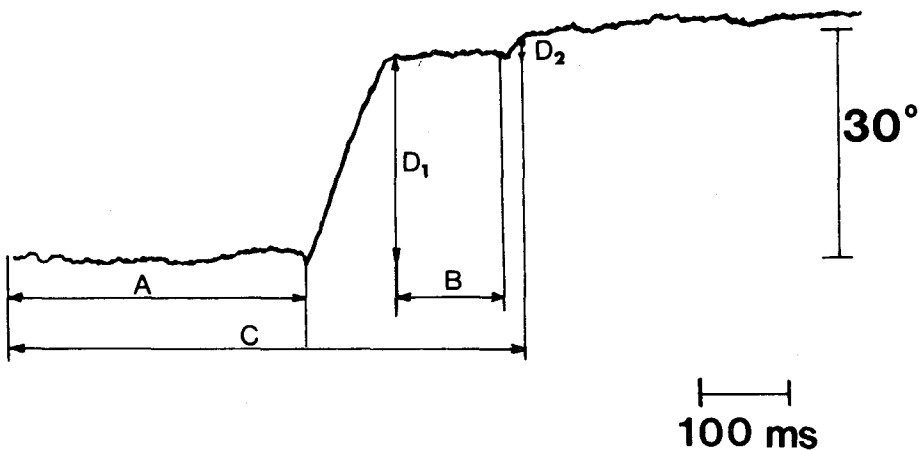


Fig. 3 — EOG recording of a refixation saccade evoked by a light target lit on 30 degrees on the right (arrowhead) in a normal control subject. A, reaction time. B, intersaccadic interval. C, search time. D_1 and D_2 , amplitude (degrees) of the main and corrective saccades.

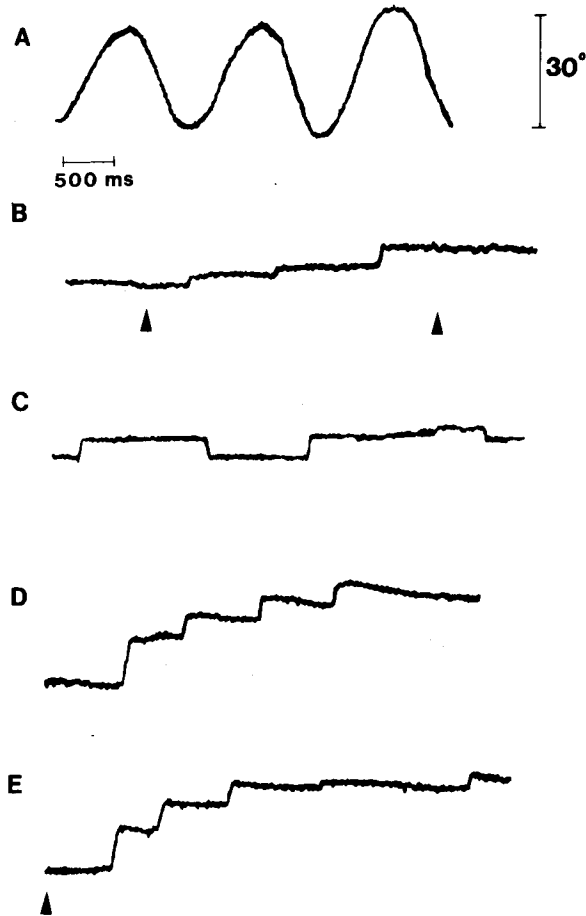


Fig. 4 — Horizontal ocular movement recorded from the patient. A, reflex eye movements evoked by horizontal, 30 degrees, passive head displacements on both sides (doll's-eye movements). B, movement elicited by a light spot moving from center to right, 15 degrees/second (arrowhead). C, spontaneous flicker during central fixation. D, saccades elicited by verbal command. E, refixation saccade elicited by light target lit 30 degrees on the right (arrowhead).

elicited by verbal command (Figure 4d). A spot of light slowly driven in the horizontal plane along the screen from the center to 30 degrees on the right failed to elicit any smooth pursuit movement. Occasional saccades that occurred during the test were always inadequate to match the eye and spot position (Figure 4b). Rightward refixation saccades (Figure 4e) showed an increased latency (mean 1318 ± 918 msec.; controls 332 ± 100) and a complex form consisting of 4-5 subsequent steps (mean amplitude 6.47 ± 4.6 degrees) with an intersaccadic interval of 1033 ± 650 msec. Two-step refixation saccades are occasionally seen also in our control population; however, the amplitude of the second (corrective) movement does not exceed 1/10 of the total amplitude with an intersaccadic interval of 110 ± 49 msec.

The target position was attained only in 52% of the trials after a search time of 3499 ± 1231 msec. (controls 492 ± 165 msec.). In the remaining cases the stimulus evoked erratic saccades, to and fro, with failure to reach the target even 6 seconds or more after target presentation. The performance did not significantly improve after repeated identical trials. The stability of central fixation was markedly affected by small saccades (mean amplitude 3.6 ± 1.2 degrees) leading the eyes back and forth around the central point (Figure 4c).

DISCUSSION

Our patient presented with an oculomotor symptomatology that mainly involved voluntary eye movements and oculomotor orientation. Optic ataxia and impairment of visual perception, which affected discrimination of complex forms and their orientation in space, were also present. These findings are discussed with reference to the main oculomotor disorders reported in Balint's syndrome (see Table I). According to the literature, the most characteristic sign is the "wandering gaze": visual fixation is randomly achieved after many erratic exploratory movements. It reflects the inability to bring into the foveal region a peripheral retinal image by a proper amplitude-designed saccade.

In our patient refixation saccades and saccades on verbal command were abolished in both upward and leftward directions. On the right, refixation saccades were markedly impaired and failed to attain the target in almost half of the trials. In 52% of the trials visual fixation was achieved by an irregular sequence of low amplitude saccades. The interposed latencies, variable in duration, were always larger than those of corrective saccades observed in normal control subjects (see also Becker and Fuchs, 1969).

Focal lesions of the putative brainstem oculomotor centers for vertical (mesencephalic reticular formation [Buttner-Ennever and Henn, 1978]) and horizontal (paramedian pontine reticular formation [Cohen and Henn, 1972]) saccades were ruled out by necropsy. On the other hand, extensive cortical lesions were found in the occipital lobe of both sides with prevalent involvement of the right hemisphere. In addition, an area involving the white matter of the right frontal lobe was also present. The impairment of refixation and saccades on verbal command may therefore be related to a defect of oculomotor programming activity that takes place at the cortical level and/or to a disruption of corticofugal pathways that mediate motor commands to the subcortical oculomotor centers. In agreement with the telencephalic origin of oculomotor disturbances observed in our patient is the preservation of occasional saccadic movements occurring in a spontaneous-like fashion.

With regard to pursuit eye movements, the EOG recording demonstrated their complete abolishment in the horizontal plane, in agreement with anatomoclinical observations that indicate a putative role of the occipital lobe in the control of pursuit movements (Aschoff, 1974; Larmande, Prier, Masson and Cambier, 1980). Usually, the loss of pursuit gain, caused by the occipital lesion, is compensated for by small compensatory saccades, which result in a stepwise course of the smooth pursuit. The concomitant impairment of saccades made such a compensatory mechanism impossible in our case.

In evaluating the oculomotor troubles observed in our patient, the possible influence of visual field defect has to be considered. Although a precise map of visual field was difficult to obtain, it is conceivable that targets located beyond 30 degrees from the midline were within the blind area. However, we know that

TABLE I
Oculomotor Symptomatology Reported in the Literature for Balint's Syndrome

Reference	Voluntary saccadic movements		Spontaneous saccades	Smooth pursuit	Reflex movements	Convergence	Fixation spasm
	Refixation saccades	Saccades on verbal command					
Balint, 1909	NR	Absent	Present	NR	Present	NR	Present
Holmes, 1918	1) Wandering gaze	Present	Present	Altered	NR	Absent	NR
	2) Wandering gaze	Present	Present	NR	NR	Absent	NR
	3) Wandering gaze	Present	Present	Absent	NR	Absent	NR
	4) Wandering gaze	Present	Present	NR	NR	Absent	NR
	5) Wandering gaze	Present	Present	Absent	NR	Absent	Present
	6) NR	Present	Present	Altered	NR	Absent	NR
Hécaen et al., 1950	1) Absent	Absent	Present	Absent	NR	NR	Present
Hécaen and Ajuriaguerra, 1954	1) Wandering gaze	Present	Present	Altered	NR	NR	Present
	2) Wandering gaze	Present	Present	Altered	NR	NR	NR
	3) Wandering gaze	Present	Present	Absent	Present	NR	NR
Luria, 1959	1) Wandering gaze	Present	NR	NR	Nystagmus	NR	NR
Waltz, 1961	1) Wandering gaze	Present	Present	Altered	Present	NR	NR
	2) Wandering gaze	Present	Present	Altered	Present	NR	Present
	1) Wandering gaze	NR	Present	Altered	Present	NR	NR
Saraux et al., 1962	1) Wandering gaze	NR	Present	Normal	NR	NR	NR
Luria et al., 1963	1) Wandering gaze	Present	NR	Altered	NR	NR	NR
Godwin-Austen, 1965	1) Wandering gaze	Present	Present	Altered	Present	Absent	Present
Michel et al., 1965	1) Wandering gaze	Present	Present	NR	NR	NR	NR
Tyler, 1968	1) Wandering gaze	Present	Present	NR	NR	NR	Present
Sorgato, 1976	1) Wandering gaze	NR	Present	NR	NR	NR	Present
	2) NR	NR	NR	NR	NR	NR	NR
Damasio and Benton, 1979	1) NR	NR	Present	NR	NR	NR	NR
Hausser et al., 1980	1) NR	Absent	Present	Absent	NR	NR	Present

NR, no reference made to this parameter.

lesions of the visual cortex in humans do not completely abolish the visual function in the hemianopic field as defined by the standard perimetric test (Pöppel, Held and Frost, 1973; Weiskrantz, Warrington, Sanders and Marshall, 1974; Barbur, Ruddock and Waterfield, 1980). This "residual vision" mediated by cortical parastriated areas (Weiskrantz et al., 1974) and/or subcortical (collicular) structures (Perenin and Jeannerod, 1978; Zihl, 1980) enables the subject to perform goal-directed eye movements in the hemianopic field. The severe impairment of oculomotor orientation in our patient cannot therefore simply be accounted for by the visual-field defect. A more complex defect affecting the location of objects with respect to spatial coordinates seems to have been involved. The ensuing impairment of "panoramic vision" (Denny-Brown and Chambers, 1976; Denny-Brown and Fischer, 1976) may explain the peculiar pattern of random ocular movements that occurred during attempts of fixation, which persisted unchanged even after repeated trials. Evidence of such a defect of spatial representation was also supplied by the failure to orient figures in space and to discriminate figures composed of several subunits.

Spasmodic fixation is a term that designates the inability to move the eyes away from an object the patient is looking at (Holmes, 1938). It is often considered one of the main elements of Balint's syndrome, although it is not consistently found in this condition (see Table I). On the other hand, spasmodic fixation has been reported in otherwise defined pathological situations such as ocular motor apraxia (Cogan and Adams, 1953) in the pathogenesis of which frontal lobes are usually implicated. The EOG recording performed in our case, as well as in other preceding reports (Karpov, Meerson and Tonkonogh, 1979), showed an ocular flicker that resulted in an instability of eye position during spasmodic fixation.

Optic ataxia is also considered a consistent sign in Balint's syndrome (Hausser et al., 1980). In our patient this symptom was evident when he was asked to point with the right finger to a luminous target (the left arm was not evaluable because of paresis). Spasmodic fixation and optic ataxia might both be viewed merely as a consequence of the impairment of "panoramic vision." However, on the basis of anatomic-clinical observations they have been more specifically related to a lesion of association occipito-frontal pathways, which mediate the transfer of information from sensory to motor districts (Rondot, de Recondot and Ribadeau-Dumas, 1977; Hausser et al., 1980). This raises the problem of a correlation between clinical symptomatology and the anatomical picture in our patient.

According to the postmortem examination, the main lesion involved the occipital cortex and the underlying white matter of both sides. The lesions partially involved the lower lip of the striated cortex (area 17) bilaterally, sparing the occipital pole. A more extensive damage was evident in surrounding areas 18 and 19. In particular, these cortical regions were involved mainly in their basal aspect on the right side, whereas on the left both the ventral and dorsal aspects of areas 18 and 19 were included.

The damage of the inferior striated cortex was responsible for the predominant impairment of the upper visual field. In addition, it may explain the selective defect of vertical upward eye movements. According to Wagman's (1964) experiments on cortical stimulation, downward and upward ocular movements are respectively controlled by superior and inferior lips of the calcarine fissure.

For a discussion of the visuospatial and oculomotor defects, the bilateral

involvement of areas 18 and 19 is particularly relevant, according to previous anatomo-clinical observations. To our knowledge 8 cases (Holmes, 1918; Hécaen et al., 1950; Hécaen and Ajuriaguerra, 1954; Waltz, 1961; Michel et al., 1965; Hausser et al., 1980) have undergone postmortem examination after the first report by Balint (1909). A common finding to all these cases was a bilateral involvement of the parieto-occipital region. However, in most of them the lesion extended anteriorly, making it difficult to define the critical area for the visuo-motor defect.

From this point of view our case is particularly interesting because of the relatively well-defined occipital topography of the lesion, with sparing of the parietal region of the angular gyrus, which, according to Holmes (1918), is considered critical for visuo-spatial orientation. According to the clinical history, a selective impairment of "panoramic vision" was already present 3 months before admission to our hospital, when the CT scan failed to show any definite lesion outside the bilateral occipital region. The more anterior lesion shown by the subsequent CT scan and confirmed by the postmortem examination must have occurred at the same time as the last episode (with left hemiparesis) at the time of our examination. It is reasonable to assume that leftward gaze paralysis was part of the motor syndrome that resulted from this stroke.

Since the lesion involved the white matter underlying insular cortex, it may also have interrupted association fibers traveling in this region. This may account for some of the symptoms observed in our patient. In fact, frontal lesions have been implicated in difficulty in initiating eye movements (Botez, 1979). Spasmodic fixation might therefore be compared to the oculomotor apraxia according to Cogan's definition (1952). However, it is noteworthy that the "spasm of fixation" has been induced in monkeys by bilateral experimental lesions strictly confined to areas 18 and 19 (Denny-Brown and Chambers, 1976; Denny-Brown and Fischer, 1976). It is viewed in this case as a release symptom due to a loss of a normal competitor, i.e., panoramic vision.

It therefore seems justified to conclude that the possible contribution of a lesion involving the frontal lobe and/or the occipito-frontal association pathways is unnecessary to produce the oculomotor defect that characterizes Balint's syndrome. Loss of visual fixation, wandering gaze, spasmodic fixation and optic ataxia may all be accounted for by the loss of panoramic vision due to a bilateral impairment of areas 18 and 19.

ABSTRACT

A 67-year-old man had repeated cerebral ischemic attacks, which resulted in a clinical picture combining paralysis of visual fixation, optic ataxia and impairment of visuospatial orientation, consistent with the definition of Balint's syndrome. Postmortem examination showed multiple lesions involving the occipital cortex of both sides and the white matter underlying the right insular cortex. EOG recording demonstrated a marked impairment of refixation saccades and saccades on verbal command. Smooth pursuit movements were completely abolished. Visual fixation was randomly achieved after many erratic exploratory movements and steadily maintained on the target (spasmodic fixation). During spasmodic fixation, EOG recording detected an ocular flicker resulting in a continuous instability of eye position. It is suggested that these findings may all be accounted for by the loss of panoramic vision due to a bilateral impairment of cortical areas 18 and 19.

REFERENCES

- ASCHOFF, J.C. (1974) *Reconsideration of the oculomotor pathway*, in *The Neurosciences: Third Study Program*, ed. by F.O. Schmitt and F.G. Worden, MIT Press, Cambridge.
- BALINT, R. (1909) *Seelenlähmung des "Schauens", optische Ataxie, räumliche Störung der Aufmerksamkeit*, *M Schr. Psychiatr. Neurol.*, 25, 51-81.
- BARBUR, L.J., RUDDOK, K.H., and WATERFIELD, A.V. (1980) *Human visual responses in the absence of the geniculo-calcarine projection*, *Brain*, 103, 905-928.
- BECKER, W., and FUCHS, A.F. (1969) *Further properties of the human saccadic system: Eye movements and correction saccades with and without visual fixation points*, *Vision Res.*, 9, 1247-1258.
- BOTEZ, M.I. (1979) *Optic ataxia and apraxia of gaze*, *Neurology*, 29, 1319-1320.
- BUTTNER-ENNEVER, J.A., and HENN, V. (1978) *A cell group associated with vertical eye movements in the rostral mesencephalic reticular formation of the monkey*, *Brain Res.*, 151, 31-47.
- COGAN, D.G., and ADAMS, R.D. (1953) *A type of paralysis of conjugate gaze (ocular motor apraxia)*, *Arch. Ophthalmol.*, 50, 434-442.
- COHEN, B., and HENN, V. (1972) *Unit activity in the pontine reticular formation associated with eye movements*, *Brain Res.*, 46, 403-410.
- DAMASIO, A.R., and BENTON, A.L. (1979) *Impairment of hand movements under visual guidance*, *Neurology*, 29, 170-178.
- DENNY-BROWN, D., and CHAMBERS, R.A. (1976) *Physiological aspects of visual perception. I. Functional aspects of visual cortex*, *Arch. Neurol.*, 33, 219-227.
- , and FISCHER, E.G. (1976) *The subcortical visual direction of behavior*, *Arch. Neurol.*, 33, 228-242.
- GODWIN-AUSTEN, R.B. (1965) *A case of visual disorientation*, *J. Neurol. Neurosurg. Psychiatr.*, 28, 453-458.
- HAUSSER, C.O., ROBERT, F., and GIARD, N. (1980) *Balint's syndrome*, *Can. J. Neurol. Sci.*, 7, 157-161.
- HÉCAEN, H., and AJURIAGUERRA, J. (1954) *Balint's syndrome (psychic paralysis of visual fixation) and its minor forms*, *Brain*, 77, 373-400.
- , —, ROUQUES, L., DAVID, M., and DELL, M.D. (1950) *Paralysie psychique du regard de Balint au cours de l'évolution d'une leucoencéphalite type Balò*, *Rev. Neurol.*, 83, 81-104.
- HOLMES, G. (1918) *Disturbances of visual orientation*, *Br. J. Ophthalmol.*, 2, 449-468, 506-516.
- (1938) *The cerebral integration of the ocular movements*, *Br. Med. J.*, 2, 107-112.
- KARPOV, B.A., MEERSON, Y.A., and TONKONOGH, I.M. (1979) *On some peculiarities of the visuomotor system in visual agnosia*, *Neuropsychologia*, 17, 281-294.
- LARMANDE, P., PRIER, S., MASSON, M., and CAMBIER, J. (1980) *Perturbations de la poursuite oculaire et lésions pariéto-occipitales unilatérales*, *Rev. Neurol.*, 136, 345-353.
- LURIA, A.R. (1959) *Disorders of "simultaneous perception" in a case of bilateral occipitoparietal brain injury*, *Brain*, 82, 437-449.
- , PRAVDINA-VINARSKAYA, E.M., and YARBUSS, A.L. (1963) *Disorders of ocular movement in a case of simultanagnosia*, *Brain*, 86, 219-228.
- MICHEL, F., JEANNEROD, M., and DEVIC, M. (1965) *Trouble de l'orientation visuelle dans les trois dimensions de l'espace*, *Cortex*, 1, 441-466.
- PERENIN, M.T., and JEANNEROD, M. (1978) *Visual function within the hemianopic field following early cerebral hemidecortication in man. I. Spatial localization*, *Neuropsychologia*, 16, 1-13.
- PÖPPEL, E., HELD, R., and FROST, D. (1973) *Residual visual function after brain wounds involving the central visual pathways*, *Nature*, 243, 295-296.
- RONDOT, P., de RECONDOT, J., and RIBADEAU-DUMAS, J.L. (1977) *Visuomotor ataxia*, *Brain*, 100, 355-376.
- SARAUX, H., ESTEVE, P., GRAVELEAU, D., and GOUPIL, H. (1962) *Le syndrome de Balint et apraxie oculo-motrice*, *Ann. Oculist.* 195, 456-472.

- SORGATO, P. (1976) *Analisi neuropsicologica delle complicanze cerebrali a lungo termine dell'eclampsia*, Riv. Patol. Nerv. Ment., 97, 371-384.
- TYLER, H.R. (1968) *Abnormality of perception with defective eye movements (Balint's syndrome)*, Cortex, 4, 154-171.
- WAGMAN, I.N. (1964) *Eye movements induced by electric stimulation of cerebrum in monkeys and their relationship to bodily movements*, in The Oculomotor System, ed. by M.B. Bender, Harper and Row, New York.
- WALTZ, A.G. (1961) *Dyspraxias of gaze*, Arch. Neurol., 5, 638-647.
- WEISKRANTZ, L., WARRINGTON, E.K., SANDERS, M.D., and MARSHALL, J. (1974) *Visual capacity in the hemianopic field following a restricted occipital ablation*, Brain, 97, 709-728.
- ZIHL, J. (1980) *"Blindsight": Improvement of visually guided eye movements by systematic practice in patients with cerebral blindness*, Neuropsychologia, 18, 71-77.

Floriano Girotti, M.D., Istituto Neurologico "C. Besta", Via Celoria 11, 20133 Milano, Italy.