

Short report

Transient global amnesia due to left temporal haemorrhage

GIANLUCA LANDI, MARIA CRISTINA GIUSTI, MARIO GUIDOTTI

From the Neurological Clinic, University of Milan, Milan, Italy

SUMMARY In a patient with transient global amnesia, computed tomography demonstrated a left temporal haemorrhage sparing the hippocampal region.

The syndrome of transient global amnesia is characterised by a sudden and reversible loss of short-term memory associated with a retrograde amnesia. Although several pathological conditions,¹⁻³ including tumours,⁴⁻⁶ have been reported in association with transient global amnesia, most authors attribute the amnesic attacks to transient ischaemia involving the medial temporal lobes.⁷⁻⁹ We observed a patient who had an episode of transient global amnesia in association with left temporal haemorrhage. This is an addition to the recognised pathological conditions associated with transient global amnesia.

Case report

A 75-year-old right-handed man was brought to hospital because of the abrupt onset of memory loss while he was walking in the street. Although he retained personal identity, he could not recall the events of the preceding two days and persistently asked where he was and why he was there. He repeated the same questions again and again, and showed complete inability to retain new information and to register memory traces for current events. Verbal expression, comprehension and repetition of sentences were preserved. Neurological examination was otherwise normal, except for a slightly broad-based gait and a tendency to retropulsion on Romberg's test. Past medical history was unremarkable. An ECG showed sinus tachycardia with sporadic ventricular extrasystoles. Blood pressure on admission was 220/100 mm Hg, but during the following days it dropped to 160/80 mm Hg without treatment. The remainder of the general examination was negative. Blood chemistry, skull and chest radiographs

were normal. An EEG showed bitemporal slow waves, predominant on the left side.

After 18 hours this condition resolved slowly, leaving a permanent retrograde amnesia for the preceding day. Neurological examination was normal. On the third hospital day, a CT-scan showed a small haemorrhage in the left temporal lobe; no mass effect was observed (fig (a)). The patient complained of headache and dexamethasone, 4 mg six hourly, was given. He gradually improved, and therapy was tapered and then stopped during the next week. A new CT scan, performed on the 15th hospital day, showed that the temporal lesion had become hypodense (fig (b)); no abnormal enhancement was observed after intravenous contrast injection. A third CT scan, 10 days later, was unchanged, and the patient was discharged. On follow-up 14 months later, neurological examination was normal, and no residual impairment of memory performance was observed. A CT scan with contrast enhancement was normal.

Discussion

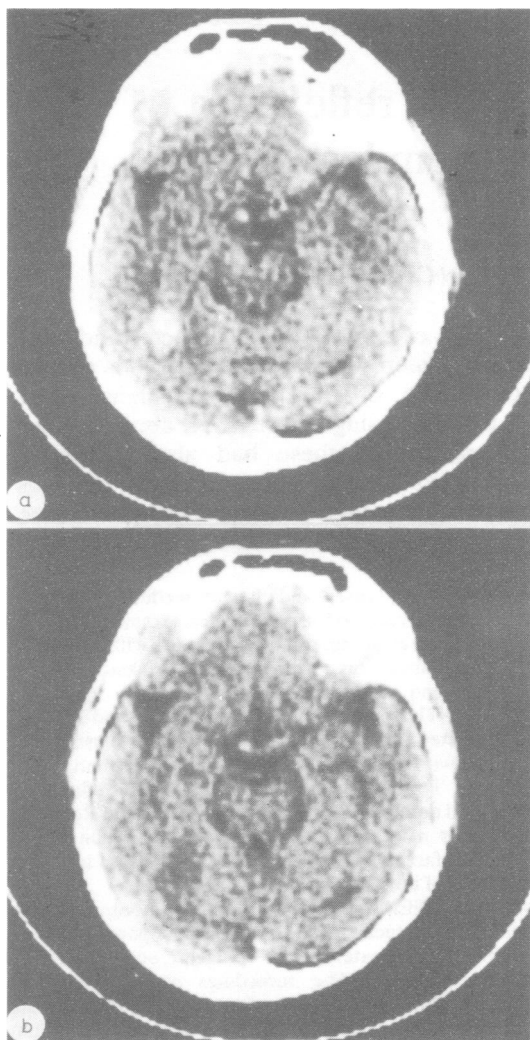
Although unilateral lesions of the dominant temporal lobe may be sufficient to cause transient global amnesia,¹⁰ they commonly affect its medial part,^{4,6,11} which was spared in our case. Lisak and Zimmerman¹¹ suggested that convulsive phenomena may explain the occurrence of transient global amnesia in mass lesions, but our patient's EEG did not show epileptic discharges. In view of the small size of the haemorrhage, a direct mass effect on the hippocampus seems unlikely. However, reversible damage may have occurred to fibres connecting the hippocampus to other temporal lobe structures involved in memory functions.¹² Alternatively, the haemorrhage may have transiently impaired the arterial blood supply to the medial temporal lobe as observed by Shuping *et al* in a patient with a left hemispheric glioma.⁶

Because of its predominance in elderly people, the high incidence of atherosclerotic risk factors, and the

Address for reprint requests: Dr G Landi, Clinica Neurologica II, Ospedale Policlinico, Via F Sforza 35, 20100 Milan, Italy.

Received 12 July.

Accepted 7 August 1982



CT scan of the left temporal haemorrhage on day 3 (a) and on day 15 (b).

possible association with other transient ischaemic attacks, transient global amnesia is commonly

attributed to cerebral ischaemic events.^{7,9,13} The unexpected finding of a small temporal haemorrhage in our patient illustrates the role of CT in the anatomical and aetiological diagnosis of transient global amnesia attacks.

References

- ¹ Gilbert JJ, Benson DF. Transient global amnesia. Report of two cases with definite aetiologies. *J Nerv Ment Dis* 1972;154:461-4.
- ² Greenlee JE, Crampton RS, Miller J. Transient global amnesia with cardiac arrhythmia and digitalis intoxication. *Stroke* 1975;6:513-6.
- ³ Caplan L, Chedru F, Lhermitte F, Mayman C. Transient amnesia and migraine. *Neurology* (NY) 1981;31:1167-70.
- ⁴ Hartley TC, Heilman KM, Garcia-Bengachea F. A case of transient global amnesia due to pituitary tumour. *Neurology* (Minneapolis) 1974;24:998-1000.
- ⁵ Boudin G, Pepin B, Mikol J, et al. Gliome du système limbique postérieur, révélés par une amnésie globale transitoire: observation anatomo-clinique d'un cas. *Rev Neurol* 1975;131:157-63.
- ⁶ Shuping JR, Toole JF, Alexander E Jr. Transient global amnesia due to glioma in the dominant hemisphere. *Neurology* (Minneapolis) 1980;30:88-90.
- ⁷ Matthew NT, Meyer JS. Pathogenesis and natural history of transient global amnesia. *Stroke* 1974;5:303-11.
- ⁸ Jensen TS, Olivarius B de Fine. Transient global amnesia as a manifestation of transient cerebral ischemia. *Acta Neurol Scand* 1980;61:115-24.
- ⁹ Shuping JR, Rollinson RD, Toole JF. Transient global amnesia. *Ann Neurol* 1980;7:281-5.
- ¹⁰ Benson DF, Marsden DC, Meadows JC. The amnesic syndrome of posterior cerebral artery occlusion. *Acta Neurol Scand* 1974;50:133-45.
- ¹¹ Lisak RP, Zimmerman RA. Transient global amnesia due to a dominant hemisphere tumour. *Arch Neurol* 1975;34:317-8.
- ¹² Horel JA. The neuroanatomy of amnesia. A critique of the hippocampal memory hypothesis. *Brain* 1978;101:403-45.
- ¹³ Jensen TS, Olivarius B de Fine. Transient global amnesia: its clinical and pathophysiological basis and prognosis. *Acta Neurol Scand* 1981;63:220-30.