

Figure (a) The fencing foil responsible for the injury. (b) Enlarged view of the tip of the foil.

blind though the globe was intact and the skin of the upper eyelid unbroken. Proptosis was noted but there was no evidence of pulsation and a bruit could not be detected. The right pupil exhibited complete afferent and efferent defects in the response to light and failed to constrict on accommodation. The presence in addition of right-sided ptosis, total external ophthalmoplegia, and corneal anaesthesia suggested a diagnosis of traumatic orbital apex syndrome¹⁰ on the basis of examination of the right eye alone. Fundus examination revealed no defect of perfusion of the right optic nerve head. Examination of the left eye at this stage produced evidence of intracranial penetration. The visual acuity was normal and the pupil reacted briskly to light and accommodation. The left eye could not be adducted beyond the midline when the stimulus was command or pursuit, optokinetic, or vestibular but adduction occurred on attempted convergence. Although the complete external ophthalmoplegia affecting the right eye prevented full testing of conjugate movements, these findings were considered indicative of a horizontal gaze palsy resulting from damage to the supranuclear horizontal gaze centre in the pons or to the adjacent longitudinal bundle. The left fundus was normal. The patient was admitted to hospital. Neurological examination at this stage demonstrated no abnormality other than those already noted. Radiological examination of the skull, orbits, and optic foramina was normal and in particular there was no evidence of damage in the region of the right superior orbital fissure. A CT scan showed the proptosis as the only abnormality. Neurological observations were begun. Within 2 hours of admission there developed a left-sided hemiplegia and a further CT scan showed attenuation in the region of the brain stem. The absence of a carotico-cavernous fistula was confirmed and the signs were considered to have resulted from oedema rather than from compression by haemorrhage. Tetanus

prophylaxis was given and on conservative management with antibiotics and dexamethasone the left hemiplegia and the horizontal gaze palsy rapidly resolved. After several weeks an efferent pupil response could be elicited on the right side, corneal sensation was restored, and considerable improvement was seen in the external ophthalmoplegia. Loss of vision in the right eye was permanent and probably resulted from swelling of the optic nerve within the confines of the bony optic canal following contusion.^{10 11} Within a month optic disc pallor was apparent. Permanent damage to cerebellar pathways resulted in ataxia and horizontal nystagmus which did not resolve.

It is evident that the foil entered the orbit through the upper conjunctival fornix producing very little external sign of injury. It traversed the orbit and, taking a course determined by the downward slope of the orbital roof, passed through the superior orbital fissure and on, lateral to the cavernous sinus, before coming to rest in the region of the pons and right cerebellar hemisphere. To date there are few reports of hemiplegia following transorbital penetrating injury,^{3 12 13} and so far as is known the finding of a gaze palsy in such an injury has not previously been reported. The possibility of intracranial extension must always be considered in cases of orbital injury. It is wise to admit all potential transorbital injuries to hospital for observation¹ and the importance of a careful neuro-ophthalmological assessment at the initial examination cannot be overstated.²

JOHN HUNGERFORD
University College Hospital,
Gower Street,
London, WC1

References

- ¹ Kjer P. Orbital and transorbital stab wounds. *Arch Ophthalmol* 1954;**51**:811-21.
- ² Bard LA, Jarrett WH. Intracranial complications of penetrating orbital injuries. *Arch Ophthalmol* 1964;**71**:332-43.
- ³ Bulluck MH, Baker GS, Henderson JW. Injuries of the brain caused by penetration of the orbit. *Minn Med* 1959;**42**:1408-13.
- ⁴ McClure CC, Jr, Gardner WJ. Transorbital intracranial stab wounds. *Cleve Clin Q* 1949;**16**:118-25.
- ⁵ Guthkelch AN. Apparently trivial wounds of the eyelids with intracranial damage. *Br Med J* 1960;**ii**:842-4.
- ⁶ Duffy GP, Bhandari YS. Intracranial complications following transorbital penetrating injuries. *Br J Surg* 1969;**56**:685-8.
- ⁷ Webster JE, Schneider RC, Lofstrom JE. Observations upon management of orbitocranial wounds. *J Neurosurg* 1946;**3**:329-36.

⁸ Schneider RC, Henderson JW. Penetrating orbital wound with intracranial complications. *Arch Ophthalmol* 1952;**47**:81-5.

⁹ Svoboda J. Injury of orbit and base of skull with fatal termination. *Československá oftalmologie* 1948;**72**:4. Abstracted Ophth Lit 1948;**2**:422.

¹⁰ Watson PG, Holt-Wilson AD. The traumatic orbital apex syndrome, its differential diagnosis and treatment. *Trans Ophthalmol Soc UK* 1968;**88**:361-74.

¹¹ Evans JP, Scheinker IM. Histologic studies of brain following head trauma: post-traumatic cerebral swelling and edema. *J Neurosurg* 1945;**2**:306-14.

¹² Larmande A, Descuns P, Margailan A. Wound of the orbit with homolateral hemiplegia in a fencer. *Rev Otoneuroophthalmol* 1956;**28**:440-1.

¹³ Platt ES. Orbitocranial penetrating injuries. *Am J Ophthalmol* 1954;**37**:758-63.

Focal dystonia in association with cerebral infarction

Sir: We wish to report the case of a woman who developed bradykinesia and rigidity of her left arm, and subsequently, a progressive fixed dystonic posture of her left hand in association with an infarct in the region of the right basal ganglia.

In 1974, when 43 years old, the patient presented with a six month history of progressive weakness of the left hand, with difficulty in doing up buttons or manipulating a fork. There was no family history of consanguinity or of neurological disease and the patient's previous health had been excellent. On examination there was a mild resting tremor of the left hand, with cogwheel rigidity at the elbow and wrist, and fine finger movements of the left hand were moderately impaired. The blood pressure was 230/140 mm Hg.

An initial diagnosis of Parkinson's disease was made and the hypertension treated, first with methyl dopa and later propranolol. No anti-Parkinsonian therapy was given and after a year the tremor remitted, but there was a slight increase in the rigidity and bradykinesia in the left arm. The latter failed to respond to trials of levodopa, bromocriptine or anticholinergic treatment which was tried over the following two years. In 1977 the patient first developed an abnormal posture of the left hand and this gradually increased during the next three years. On examination at the end of 1981 she was normotensive and her left hand was now permanently maintained in a dystonic posture (fig A). The medial three fingers were flexed at the metacarpo-phalangeal

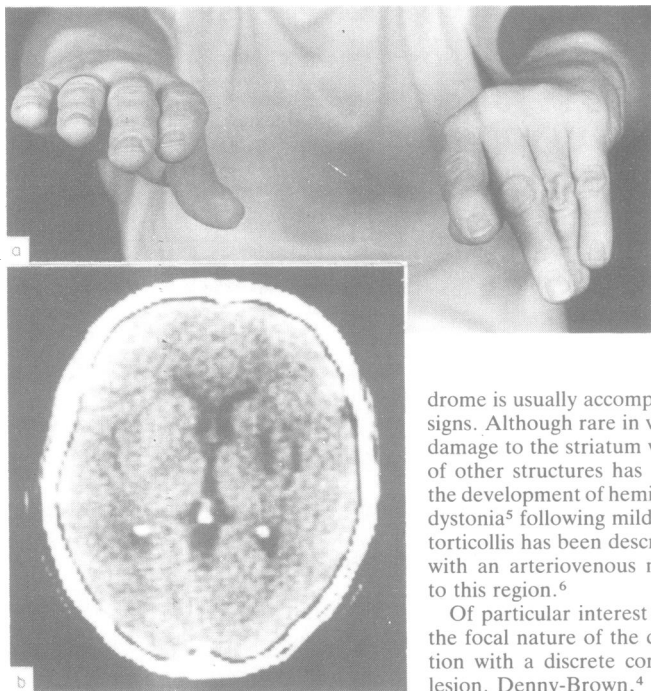


Fig (A) The dystonic posture of the left hand is demonstrated. (B) CT scan shows a low attenuation area in the right lentiform nucleus as well as enlargement of the right Sylvian fissure. (Côt 5B).-

joint, which could not be extended beyond 45° and the interphalangeal joints were hyperextended and could not be flexed passively beyond 20°. Movements of the thumb and forefinger were normal. There was mild rigidity at the left wrist and elbow. There were no other neurological signs. Routine blood tests including copper studies were normal as was an EEG. A CT scan (fig B) demonstrated mild right-sided cerebral atrophy and a low attenuation lesion in the region of the right lentiform nucleus compatible with a mature infarct. There was no clinical event suggestive of a stroke, but the scan appearance and the history of hypertension were in keeping with a silent infarction involving the basal ganglia on the right side. Although the time of onset of the infarction is not known, a delay between a cerebral insult and the onset of dystonia has been described by other authors.¹² Dooling and Adams³ have observed that post-hemiplegic athetosis only occurs with basal ganglia lesions when the cortico-spinal tracts are at least partially intact, but following a stroke the development of such a syn-

drome is usually accompanied by long tract signs. Although rare in vascular accidents,⁴ damage to the striatum with virtual sparing of other structures has been implicated in the development of hemidystonia² and focal dystonia⁵ following mild head injuries, and torticollis has been described in association with an arteriovenous malformation close to this region.⁶

Of particular interest in this patient was the focal nature of the dystonia in association with a discrete contralateral cerebral lesion. Denny-Brown,⁴ in his discussion of segmental dystonia described various abnormal hand postures which may follow a focal contralateral subthalamic lesion that damages the fields of Forel. In such cases the upper limb is rigid and initially the wrist is flexed and pronated with the hand open, but after some years the fingers may become tightly clenched and the elbow flexed. Whilst our patient exhibited rigidity at the left elbow and wrist, her abnormal posture was restricted to three fingers. In the absence of the CT scan findings, her hand posture might have been regarded as functional.

M TRAUB, A RIDLEY
Department of Neurology,
The London Hospital,
Whitechapel, London
E1 1BB, UK

References

- Burke RE, Fahn S, Gold AP. Delayed onset dystonia in patients with static encephalopathy. *J Neurol Neurosurg Psychiatry* 1980;43:789-97.
- Brett EM, Hoare RD, Sheehy MP, Marsden CD. Progressive hemidystonia due to focal basal ganglia lesion after mild head trauma. *J Neurol Neurosurg Psychiatry* 1981;44:460.
- Dooling EC, Adams RD. The pathological anatomy of posthemiplegic athetosis. *Brain* 1975;98:29-48.

- Denny-Brown D. Clinical symptomatology of basal ganglia disease. In: *Handbook of Clinical Neurology* Vol 6. Vinken PJ, Bruyn GW eds, Amsterdam: North Holland Publishing Company, 1968.
- Messimy R, Diebler C, Metzger J. Dystonie de torsion du membre supérieur gauche probablement à un traumatisme crânien. *Rev Neurol (Paris)* 1977;133:199-206.
- Lobo-Antunes J, Yahr MD, Hilal SK. Extra-pyramidal dysfunction with cerebral arteriovenous malformations. *J Neurol Neurosurg Psychiatry* 1974;37:259-68.

Association of Klippel-Trenaunay-Weber syndrome with myotonic dystrophy

Sir: Myotonic dystrophy, an inherited disorder, is associated with cataract, frontal baldness, cardiac dysfunction, testicular atrophy, abnormal insulin secretion, Klinefelter syndrome, and Down's syndrome, in addition to central and peripheral nervous system dysfunction. Cutaneous manifestations, other than balding, are rare. Few cases of pilomatrixoma (a benign calcifying epithelioma) have been reported in myotonic dystrophy.¹ We observed an extensive systematised vascular naevus in a segmental distribution with hypertrophy affecting one upper limb, the characteristic features of Klippel-Trenaunay-Weber syndrome, in a patient with myotonic dystrophy. An exhaustive review of the literature has failed to disclose similar cases.

A 39-year-old male Muslim, an agriculturist, born of a consanguineous union was seen in December 1980, with complaints of weakness of lower limbs of 2 yr duration. He had most of the cardinal signs of myotonic dystrophy such as myotonia, frontal balding, testicular atrophy, posterior capsular cataract, wasting and weakness of temporalis, masseter, sternocleidomastoid muscles of the forearm, hands and feet (fig). Electromyography showed well sustained spontaneous, high frequency discharges, myopathic pattern and nerve conduction studies showed normal motor and sensory conduction velocity in the upper and lower limbs. A cutaneous patch on the right side of the chest and medial aspect of the arm was noticed since birth. This was dull red in colour in the distribution of thoracic 1 and 2 segments (fig). Global hypertrophy of the right arm including the shoulder was present. No venous varicosities were seen nor was there any evidence of associated disorders like syndactyly, polydactyly, scoliosis, pulmonary hypertension, mental retardation, epilepsy or paraplegia.