

Familial Cavernous Angiomas

Joseph M. Bicknell, MD; Thomas J. Carlow, MD; Mario Kornfeld, MD; Jorgen Stovring, MD; Paul Turner, MD

• Cavernous angiomas are rare, surgically remediable vascular malformations of the CNS that may be characterized by hemorrhage, seizures, or focal neurologic deficits. Three families with cavernous angiomas have been described, and we report two more.

In the first, the mother died suddenly with headache. A pontine cavernous angioma was found at autopsy in one son. His brother has similar pontine signs and a radiographically proved pontine mass. The brother's son has seizures and a calcified cerebral lesion. In the second family, the father had a cavernous angioma excised from the caudate. One of his daughters had a hemorrhagic mass removed from the spinal cord. Another daughter has seizures and a temporal lobe vascular lesion proved angiographically.

Awareness of the possibility of familial involvement may aid in diagnosis of cavernous angioma.

(*Arch Neurol* 35:746-749, 1978)

Cavernous angiomas are relatively uncommon vascular malformations that may involve any part of the CNS. Some are clinically quiescent, but others cause seizures, hemorrhage, or focal neurologic deficit. Identification of these malformations is clinically important, since surgical removal of accessible lesions is relatively easy. Cavernous angiomas may be shown radiographically, especially by computerized axial tomography (CT); at times, there are supporting findings on cerebral angiography, and occasionally calcifications in the angioma are seen on plain skull roentgenograms. They should be suspected clinically when focal neurologic problems affect more than one family member. Three such instances of

familial involvement have been reported in the past.¹⁻³ We studied two additional families showing pathologic, radiographic, or clinical evidence of cavernous angioma.

REPORT OF CASES

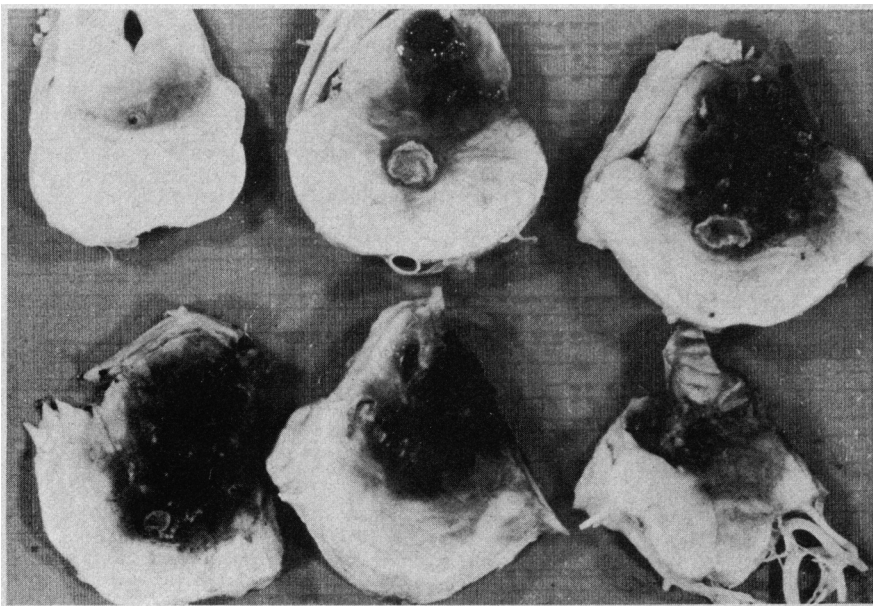
CASE 1.—A 35-year-old man was well until the age of 8 years, when suddenly strabismus, right facial paralysis, and left hemianesthesia developed. Neurologic examination performed when he was 26 years of age disclosed bilateral horizontal gaze pareses, right abducens paralysis, and palatal myoclonus in synchrony with a dissociated pendular vertical nystagmus. No ocular movement was noted in response to caloric or optokinetic stimuli. The masseter muscle on the right was weak, atrophic, and fasciculating. Right facial muscles were totally paralyzed. Hearing was impaired, mildly on the left and severely on the right. Hemiparesis, hemianesthesia, and ataxia were present on the left, and sweating was decreased on the entire right side of the body. Carotid and vertebral angiograms, pneumoencephalogram, and CSF examination showed no abnormality. He died suddenly at 35 years of age with a blood alcohol level of 519 mg/dl. Bulging of the central pons, thinning of

the right abducens and facial nerves, and atrophy of the right cerebellar hemisphere and vermis were evident on examination of the brain. Brain stem sections showed a brownish-red tegmental mass from the upper medulla to the inferior colliculus that extended through the brachium pontis into the right cerebellar hemisphere (Fig 1).

Histologically, the pontine lesion was a cavernous angioma composed of closely packed, irregular vascular channels. The channels had fibrous walls devoid of elastic fibers and smooth muscle; they were lined by a single layer of endothelium. Some contained thrombi in various stages of organization. Areas of calcification and metaplastic bone were present in several portions of the lesion. The surrounding parenchyma was rarified in some places, heavily gliotic in others, and contained numerous hemosiderin-laden macrophages (Fig 2). A second malformation, a minute telangiectasis, was seen in the right lingual gyrus.

CASE 2.—The older brother of patient 1 was in good health until he was 38 years old, when he abruptly experienced vertigo, tinnitus, hearing loss on the right side, and occipital headache. Within a week he became anesthetic on his entire left side. Neuro-ophthalmologic examination showed a horizontal gaze paresis on the

Fig 1.—Large, dark red, lobulated lesion in pontine tegmentum (case 1). It includes rounded space with calcified wall (midline, between base and tegmentum) and scattered white specks of calcium.



Accepted for publication Jan 4, 1978.

From the Departments of Neurology (Drs Bicknell and Carlow), Pathology (Dr Kornfeld), and Radiology (Dr Stovring), and the Division of Neurosurgery (Dr Turner), University of New Mexico School of Medicine and Veterans Administration Hospital, Albuquerque, NM.

Reprint requests to Department of Neurology, University of New Mexico School of Medicine, 2211 Lomas Blvd NE, Albuquerque, NM 87131 (Dr Bicknell).

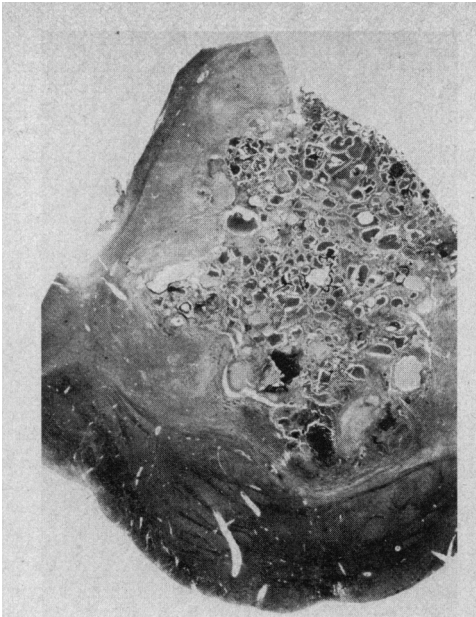


Fig 2.—Lesion is composed of tightly packed vascular channels of variable sizes (case 1). Walls consist of connective tissue lined with endothelium. There is no elastica nor media. Dark precipitates are calcium (Verhoeff-von Gieson, $\times 4.5$).

right side, bilateral abducens paresis, horizontal gaze-evoked nystagmus on right and left lateral gaze, rotary nystagmus on upward gaze, and saccadic pursuit when following targets to the right. Corneal reflex, facial sensation, and jaw strength were reduced on the right. There was a right peripheral facial paresis with myokymia. Hearing was impaired bilaterally (more on the right than the left), with features of retrocochlear involvement on audiometry. A subtle left hemiparesis and ataxia were evident.

Carotid and vertebral angiography were normal; pneumoencephalography, however, showing enlargement of the right side of the pons. He was felt to have a pontine glioma (the nature of his brother's illness had not yet been determined), and he was treated by irradiation and chemotherapy. His symptoms have remained stable for three years. Contrast-enhancing lesions in the right side of the pons and left cerebellar hemisphere consistent with cavernous angiomas have been proved subsequently by CT scan.

CASE 3.—The 19-year-old son of patient 2 had seizures when he was 9 years old, some beginning focally in the left arm and others displaying a psychomotor pattern. His neurologic examination was normal, but EEG showed spike discharges and a slow wave focus in the right posterior temporal region. A 3-cm spherical area of finely granular calcification was seen in the same area in roentgenograms of the

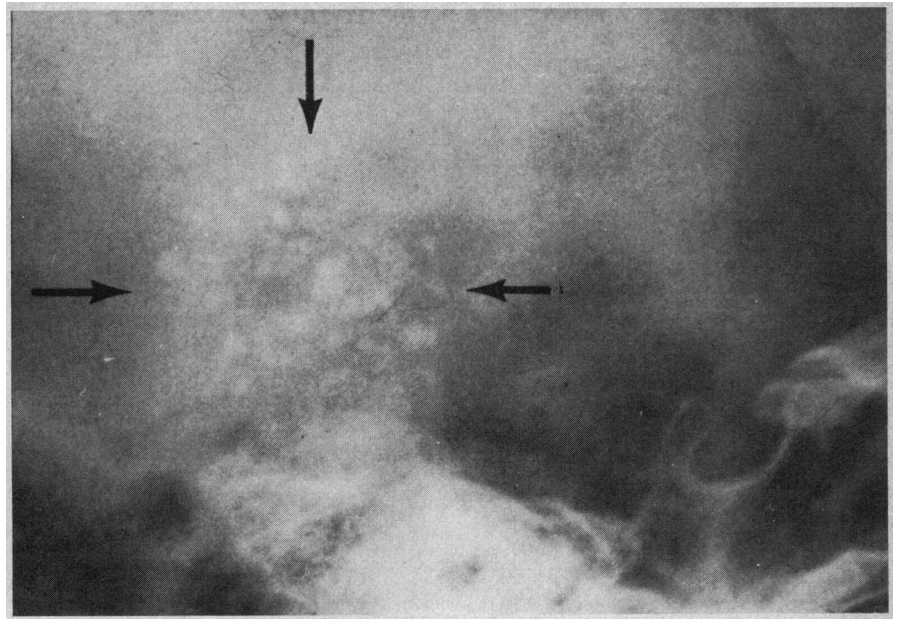


Fig 3.—Case 3. Circumscribed area of small stippled calcifications in right posterior temporal area (arrows).

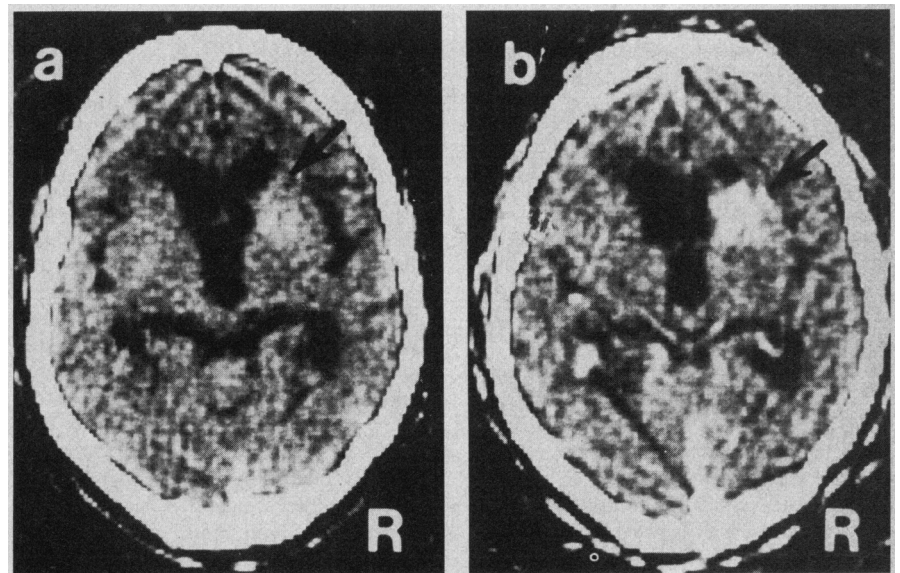


Fig 4.—Case 5. a, Precontrast CT scan showing calcium-containing, well-circumscribed lesion in right caudate nucleus and internal capsule (arrow); no mass effect. b, Enhancement of lesion after contrast (arrow).

skull (Fig 3). The mass appeared avascular angiographically, and a biopsy was attempted.

Examination of the excised tissue, however, showed only glial proliferation, globose eosinophilic bodies, and hemosiderin-containing macrophages, consistent with tissue from the periphery of a lesion that had bled at some time in the past. In the ensuing ten years, despite school and behavioral problems and unreliable use of anticonvulsants, he has remained neurologically normal with infrequent seizures.

Computerized axial tomographs showed cavernous angioma.

CASE 4.—A woman, the mother of patients 1 and 3 and the grandmother of patient 3, was not seen. She was said to have "died suddenly with a severe headache at an early age."

CASE 5.—A 56-year-old man had lifelong weakness and wasting of the left arm. Despite two years of college education, he had always held menial jobs and had been a chronic alcoholic for many years. His memory and equilibrium had been poor for

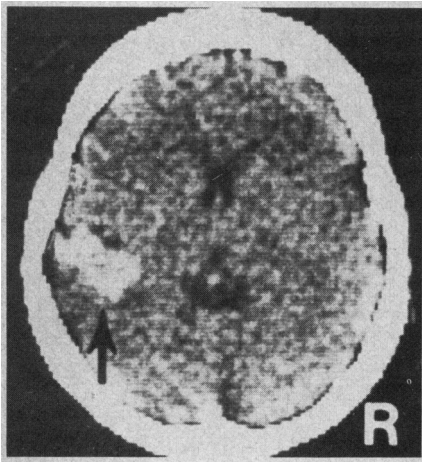


Fig 5.—Case 7. Precontrast CT scan with calcification in left posterior temporal region (arrow).

five years, and he was hospitalized for evaluation of dementia. On examination, although alert and oriented, he could not remember three items for two minutes. Cranial nerve testing showed only mild dysarthria. The left arm and hand were small, weak, and spastic, with a flexed posture and choreoathetotic movements. The gait was broad-based. Reflexes were hyperactive on the left. Sensory function was normal.

The CT scan showed slight ventricular enlargement, and a 3.5-cm, contrast-enhancing mass was present in the head of the right caudate nucleus (Fig 4). Right internal carotid angiography showed no abnormality. The lesion was excised without difficulty, and the patient was discharged unchanged.

On gross examination, the excised mass was firm and its cut surface had a spongy appearance due to the presence of multiple cystic spaces. Microscopically, it was a cavernous angioma consisting of a plexus of clustered vascular channels of varying size. The vessel walls were composed exclusively of connective tissue that often displayed irregular hyalin thickening; the vascular channels were lined by a single endothelial layer. There were areas of thrombosis and focal calcification, and the surrounding tissues showed gliosis and hemosiderin-laden macrophages.

CASE 6.—The 32-year-old daughter of patient 5 was well until she was 20 years of age, when she noted sensory loss in her left toes. This gradually ascended to the iliac crest and then extended to the right leg. At 21 years, when she experienced dysesthetic shock-like pains in the left leg, myelography was normal. However, myelography performed when she was 24 years, after she had become weak in the left leg and was unable to void, showed enlargement of

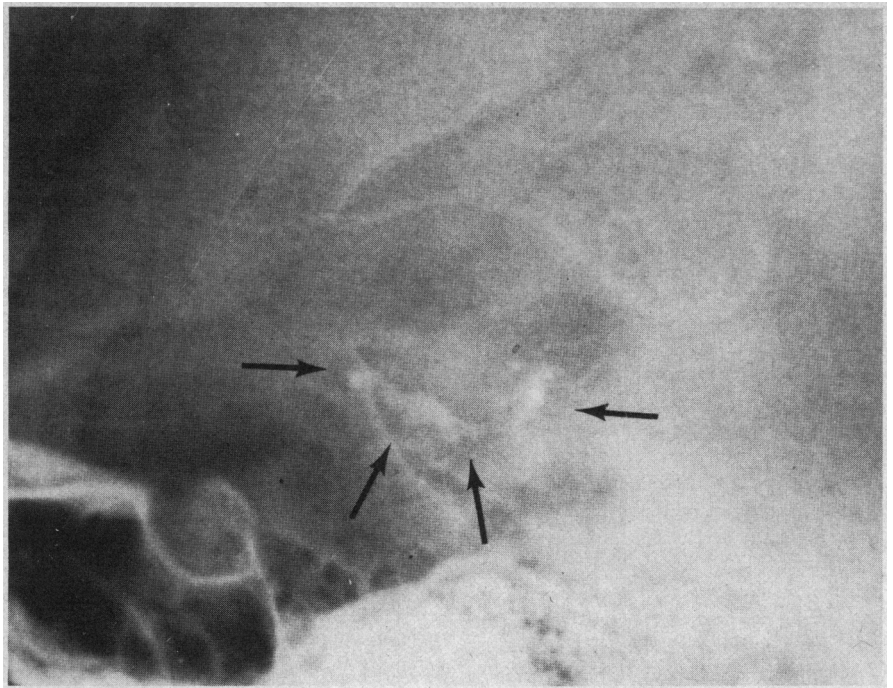


Fig 6.—Case 7. Late venous phase of left carotid arteriogram shows persistent opacification of irregular sinusoidal channels in angioma of left posterior temporal region (arrows).

the spinal cord, with a partial block of the spinal canal at the T6-T7 level.

A multilobulated, intramedullary lesion was excised from the cord. Grossly, it included liquid hematoma, three solid blood clots, and grayish surrounding tissue. Microscopic examination showed clotted blood, small fragments of cord parenchyma stained with blood pigment, and large vascular spaces described as "very dilated capillary-type structures resembling a hygroma or vascular malformation." Postoperatively, her legs remained weak and painful, and she continued to have trouble voiding. Her dysesthetic leg pain became increasingly severe despite treatment with phenytoin sodium and carbamazepine. When she was 27 years of age, a myelogram showed enlargement of the spinal cord from T5 to T7. A second laminectomy showed numerous dilated vascular channels entering an unresectable intramedullary mass of vessels.

Her symptoms worsened slowly over the next three years. Selective spinal cord angiography failed to show abnormal vessels, and she remains paraparetic with a T6 sensory level.

CASE 7.—A 28-year-old woman, the sister of patient 6, had had psychomotor seizures since she was 15 years old. This was controlled with carbamazepine, 200 mg twice daily. Results of neurologic examination were normal. At 28 years of age, her EEG showed left temporal spikes and slow

waves. A CT scan indicated a high-density mass in the left posterior temporal region (Fig 5).

Left carotid angiography was carried out with the injection of 6 ml of 60% iohalamate meglumine per second for 2½ s (a total of 15 ml of contrast medium). The filming sequence was extended over 16 s, and irregular sinusoidal channels were seen in the left posterior temporal region, with opacification persisting after contrast had disappeared from all other intracranial veins (Fig 6).

The diagnosis of cavernous angioma was suspected, but because of the left temporal location and the patient's good response to medication, surgery was deferred.

COMMENT

Vascular malformations of the nervous system are typically divided into at least three major categories: (1) capillary telangiectasis, (2) cavernous angioma, and (3) venous and arteriovenous malformation.^{4,5} Each has characteristic features pathologically, clinically, and radiographically.

Grossly, the cavernous angiomas range in size from one millimeter to several centimeters. They may be single or multiple, may be accompanied by cavernous angiomas in other organ systems, and may appear in association with telangiectases. Often

they are circumscribed or encapsulated and may be multilobular. Hemorrhage, thrombosis, calcification, or ossification may be seen.^{5,6} Microscopically, they are composed of closely packed, irregular, thin-walled channels with no elastica, no muscularis, and no intervening neural tissue.⁴ The vessel walls may be hyalinized, and hemosiderin staining and gliosis of adjacent tissue may reflect minor hemorrhages.⁵

Clinically, the cavernous angioma may be quiescent, coming to light only at autopsy. Symptomatic patients may have seizures, hemorrhage, or focal deficits, and the evolution may be ictal or progressive.^{6,7} The cerebrum and pons are the commonest sites, but the midbrain, cerebellum, medulla, or spinal cord may also be involved.^{4,6,8}

Radiographically, a cavernous angioma may be seen as (1) a circumscribed area of small, stippled calcification in plain skull films; (2) an area of increased uptake on radionuclide brain scan⁹; (3) a nonspecific mass in pneumoencephalography; (4) an area of increased density in CT scan¹⁰; or (5) an area of abnormal vascularity in angiography.

Computerized axial tomographic scanning is more sensitive than ordinary roentgenography in detecting calcifications, which are typically clustered in a well-demarcated area. Blood in the cavernous vascular spaces also appears as increased density and may show enhancement after intravenous contrast administration. There is little or no mass effect unless recent hemorrhage has occurred.

Angiography has been done in approximately 20 reported cases of cavernous angioma. Many patients have shown no abnormality or at most an avascular mass.^{11,12} Enlarged feeding arteries are never seen, but irregular neovascularity in the early arterial phase was described in one case.¹³ Recently, with improved angiographic techniques, capillary blush and prominent draining veins have been seen in several cases.^{9,14} Increased volumes of contrast medium and prolonged filming may be necessary, and contrast may persist in the angioma longer than in other venous structures.¹⁵

Kufs,¹ in 1928, described multiple "telangiectatic nodules" of the brain in a man of 81 years, his 45-year-old daughter had suddenly experienced a pontine syndrome at the age of 20 years.

A family reported in 1936 by Michael and Levin had five affected members.² The mother had seizures for three years and "died of epilepsy," and her brother had seizures as well. A daughter with intermittent left hemiplegia, focal convulsions, and calcifications visible in plain skull roentgenograms died in status epilepticus. Postmortem examination showed cavernous angiomas of the right frontal, temporal, and parietal lobes, the left hippocampus, and the right cerebellar hemisphere. Her younger sister also had focal seizures and calcifications, and her older sister had migraine-like episodes, with transient sensory loss on the left side followed by headaches.

Two patients with pathologically verified cavernous angiomas were described by Clark in 1970.³ In a 27-year-old man with headaches, psychomotor seizures, and a midbrain mass, hydrocephalus developed and he died after surgical exploration and shunting. He had cavernous angiomas in the left frontal and temporal lobe and the posterior half of the midbrain. His daughter died in coma at the age of 28 years after one year of headaches; autopsy disclosed a right temporal cavernous angioma with evidence of both old and recent hemorrhage.

Of these nine cases, four were confirmed pathologically and five were diagnosed on clinical and radiographic grounds.

Of our seven patients, one from each family (patients 1 and 5) showed the classical pathological findings of cavernous angioma, while another from each family (patients 3 and 6) showed compatible, but less conclusive, histologic changes. The tissue in case 3 resembled that seen adjacent to a vascular malformation, and that in case 6 was typical of the cryptic angioma in which hemorrhage obliterates much of the original vascular malformation. One case from each family (case 2 and 7) had no pathologic confirmation, but radiographic findings

were quite typical of cavernous angioma. In only one patient (case 4) was the diagnosis made solely on the clinical history.

With 16 cases in five families now described, familial occurrence appears to be an important clinical characteristic of cavernous angioma. The ease of identifying cavernous angiomas by CT scan and perhaps by modern angiographic technique and the feasibility of surgical excision¹² makes identification of these cases increasingly important. A positive family history may be a valuable aid to the early diagnosis and treatment of cavernous angioma.

References

1. Kufs H: Ueber Heredofamiliare Angiomatose des Gehirns und der Retina, ihre Beziehungen zueinander und zur Angiomatose der Haut. *Z Neurol Psychiatry* 113:651-686, 1928.
2. Michael JC, Levin PM: Multiple telangiectases of brain: A discussion of hereditary factors in their development. *Arch Neurol Psychiatry* 36:514-539, 1936.
3. Clark JV: Familial occurrence of cavernous angiomas of the brain. *J Neurol Neurosurg Psychiatry* 33:871-876, 1970.
4. Russell DS, Rubinstein LF: Tumours and hamartomas of the blood vessels, in *Pathology of Tumours of the Nervous System*. Baltimore, Williams & Wilkins Co, 1972, pp 85-108.
5. McCormick WF: The pathology of vascular ("arteriovenous") malformations. *J Neurosurg* 24:807-816, 1966.
6. Roberson GH, Kase CS, Wolpaw ER: Telangiectases and cavernous angiomas of the brainstem—"cryptic" vascular malformations: Report of a case. *Neuroradiology* 8:83-89, 1974.
7. Zeller RS, Chutorian AM: Vascular malformation of the pons in children. *Neurology* 25:776-780, 1975.
8. McCormick WF, Hardman JM, Boulter TR: Vascular malformations ("angiomas") of the brain, with special reference to those occurring in the posterior fossa. *J Neurosurg* 28:241-251, 1968.
9. Bartlett JE, Kishore PR: Intracranial cavernous angioma. *Am J Roentgenol Radium Ther Nucl Med* 128:653-656, 1977.
10. Kendall BE, Claveria LE: The use of computed axial tomography (CAT) for the diagnosis and management of intracranial angiomas. *Neuroradiology* 12:141-160, 1976.
11. Kamrin RB, Buchsbaum HW: Large vascular malformations of the brain not visualized by serial angiography. *Arch Neurol* 13:413-420, 1965.
12. Schneider RC, Liss L: Cavernous hemangiomas of the cerebral hemispheres. *J Neurosurg* 15:392-399, 1958.
13. Jonutis AF, Sondheimer FK, Klein HZ, et al: Intracerebral cavernous hemangioma with angiographically demonstrated pathologic vasculature. *Neuroradiology* 3:57-63, 1971.
14. Liljequist B: Angiography in intracerebral cavernous hemangioma. *Neuroradiology* 9:69-72, 1975.
15. Bogren H, Svalander C, Wickbom I: Angiography in intracranial cavernous angiomas. *Acta Radiol* 10:81-89, 1970.