

# Microsurgical Endarterectomy of the Intracranial Vertebral Artery for Vertebrobasilar Transient Ischemic Attacks

George S. Allen, M.D., Ph.D., Ronald J. Cohen, M.D., and Thomas J. Preziosi, M.D.

Departments of Neurosurgery (G.S.A., R.J.C.) and Neurology (T.J.P.), The Johns Hopkins University School of Medicine, Baltimore, Maryland

Two patients who had typical vertebrobasilar transient ischemic attacks (TIAs) that were refractory to anticoagulation with dicumarol and to antiplatelet therapy with aspirin and/or dipyridamole are described. Angiography revealed in both patients a stenotic atherosclerotic plaque of the intracranial vertebral artery between the posterior and anterior inferior cerebellar arteries. At operation, the first patient had an atherosclerotic plaque extending into the basilar artery, and no endarterectomy was attempted. The second patient had a 1-cm localized plaque that was removed successfully from the vertebral artery. Neither patient sustained a neurological deficit as a result of the operation. The patient whose plaque was not removed at operation continues to have vertebrobasilar TIAs and suffered a brain stem stroke 2 weeks after operation. The patient whose plaque was removed at operation continues to be free of TIAs 8 months later, and angiography performed 3 months after operation showed a widely patent vertebral artery. A portion of the intracranial vertebral artery has now been shown to be accessible to endarterectomy using the operating microscope. Angiography is helpful in determining this accessibility preoperatively. (*Neurosurgery* 8:56-59, 1981)

Key words: Angiography, Anticoagulation, Atherosclerotic plaque, Vertebral artery, Vertebral endarterectomy, Vertebrobasilar transient ischemic attacks

## INTRODUCTION

Patients with vertebrobasilar transient ischemic attacks (TIAs) are at risk of developing brain stem strokes. Surgical therapy has been available in the past only to those patients with extracranial causes for these attacks, such as the subclavian steal syndrome, cervical spondylosis, or atherosclerotic plaques at the origin of the vertebral artery. This paper reports the successful removal of an atherosclerotic plaque from the intracranial vertebral artery.

## CASE REPORTS

### Case 1

A 71-year-old, right-handed woman was admitted to the hospital with the chief complaint of episodes of dizziness and a sense of falling for the previous 4 months. These episodes lasted approximately 10 minutes and were commonly preceded by sensations of thickness and numbness in her tongue. In separate attacks the patient also noted transient numbness in her left hand. The patient had been anticoagulated with dicumarol and received antiplatelet therapy with aspirin, but her attacks were unchanged in frequency and severity while on these medications.

Her past medical history included two myocardial infarctions, a coronary artery bypass operation in 1976, and mild chronic obstructive pulmonary disease.

The general examination was unremarkable, and there were no arterial bruits. The neurological examination was within normal limits except for vestibular function tests that disclosed hypofunction of the vestibulo-ocular reflexes with nearly total loss of lateral canal response on the left side.

Cerebral angiography of both the carotid and the vertebrobasilar circulations demonstrated normal carotid arteries and a single stenotic lesion of the left vertebral artery just distal to the origin of the posterior inferior cerebellar artery (PICA).

A suboccipital craniectomy and removal of the arch of C-1 was performed with the patient in the sitting position on November 15, 1979. Using the operating microscope we exposed the left vertebral artery from the point at which it

penetrated the dura to the point at which it disappeared medially, anterior to the brain stem. Some rootlets of the hypoglossal nerve were draped over the posterior surface of the vertebral artery. A large arterial branch arose from the vertebral artery in the region of the atherosclerotic plaque and irrigated a significant area of the lateral medulla. The area of plaque was clearly visible as a hardened, yellowish area beginning just distal to the PICA. The patient was heparinized and an aneurysm clip was placed proximally on the vertebral artery just distal to the origin of the PICA. However, after the distal clip was placed at the level of the rostral part of the olive, a more thorough inspection revealed a plaque that extended past our operative exposure toward the basilar artery. We elected not to open the vessel because of our fear that we might not be able to excise the plaque completely and our concern that a distal intimal flap would be created, which could lead to subintimal dissection and vessel occlusion. The clips were removed from the vertebral artery. Anticoagulation was reversed with protamine sulfate because of persistent bleeding from the cervical muscles, and the incision was closed.

Postoperatively the patient did well until 2 weeks after operation when she developed her usual symptom complex of transient dizziness and numbness in her tongue, which was now associated with ataxia. Anticoagulation with dicumarol was resumed on December 1, 1979, but these symptoms persisted and she developed signs of a medullary infarct on December 4th (prothrombin time, 15 seconds; control time, 11.5 seconds). She was discharged on December 14th with some improvement, but she required assistance to ambulate. Since then she has recovered independent ambulation, and now she has mild residual perioral numbness, continues to have her typical vertebrobasilar TIAs, and remains anticoagulated.

### Case 2

This 60-year-old woman was admitted to the hospital with the chief complaint of episodic dizziness of approximately 2 to 3 years' duration, which had become worse during the past 8 months. The episodes were independent of either position or activity, and they commonly lasted for a few minutes. They

ranged in frequency from several times per day to a few times per week. Occasionally the dizziness was accompanied by nausea, and during one such episode the patient vomited. There was no consistent direction of subjective movement in space, but during the episodes the patient became ataxic. Often occurring on the same day as those episodes, but not necessarily simultaneously, were episodes of poorly formed visual hallucinations, usually in the form of "zig-zagging lights," semicircular in configuration, enlarging, and then waning rapidly. These sensations had first appeared in 1977, but had been increasing in frequency since February 1979. Since January 1979 the patient had noted several episodes of diplopia, as well as a "metallic noise" in her right ear. Her past medical history included a long history of hypertension, presently well controlled with methyldopa (Aldomet; Merck Sharp & Dohme, West Point, Pennsylvania) and a triple coronary artery bypass operation in 1977.

The patient had been evaluated in July 1979 when she had a normal cerebral computed tomographic scan, a normal electroencephalogram (EEG), and normal audiometry. She had been treated with aspirin and dipyridamole, but without change in her symptoms. Her general examination was unremarkable except for a loud left carotid bruit. A neurological examination and vestibular function tests were normal. A four-vessel cerebral angiogram revealed the following: (a) marked stenosis of the proximal left internal carotid artery at the cervical bifurcation, (b) occlusion at the origin of the right external carotid artery, (c) marked stenosis of the proximal intracranial portion of the left vertebral artery (Figs. 1 and 2), (d) a large anastomosis from the right vertebral artery at its genu on the lateral arch of C-1 to reconstitute branches of the right external carotid artery, (e) a large left anteroinferior cerebellar artery with no apparent posteroinferior cerebellar artery on the left side, (f) a large right posteroinferior cerebellar artery with no apparent anteroinferior cerebellar artery on the right side, (g) a patent right vertebral artery with mild irregularity of its intimal surface intracranially, and (h) a patent and mildly irregular basilar artery.

The patient was fully anticoagulated (prothrombin time, 26 seconds; control time, 12 seconds) with dicumarol during the interim between the performance of her angiogram and operation, but she had one further characteristic TIA.

A suboccipital craniectomy and removal of the arch of C-1 was performed with the patient in the sitting position on November 20, 1979. Because of the possibility that the large right vertebral-external carotid artery anastomosis would "steal" blood from the brain stem, this anastomotic branch was occluded with a permanent aneurysm clip. Using the operating microscope we exposed the left vertebral artery from its entrance through the dura to its disappearance anteriorly and medially under the brain stem. Inspection of the vertebral artery revealed a hard atherosclerotic plaque approximately 1 cm long, which gave the vessel a distinct yellowish appearance. Just beyond the plaque was an area of poststenotic dilatation. One main branch to the lateral medulla arose from the vertebral artery just distal to the plaque. The course of the hypoglossal nerve was anterior to the vertebral artery, and the 1st cervical nerve was applied to the posterior surface of the vertebral artery at its dural entrance. These structures and the cervical portion of the accessory nerve were mobilized by sectioning of the upper two dentate ligaments. Using permanent aneurysm clips, we occluded the vertebral artery proximally, just distal to its dural penetration, and distally at the level of the rostral part of the olive. The 9th and 10th cranial nerves were gently retracted rostrally by this clip. The lateral medullary branch was occluded separately with a temporary aneurysm clip. The vertebral artery was opened in a linear

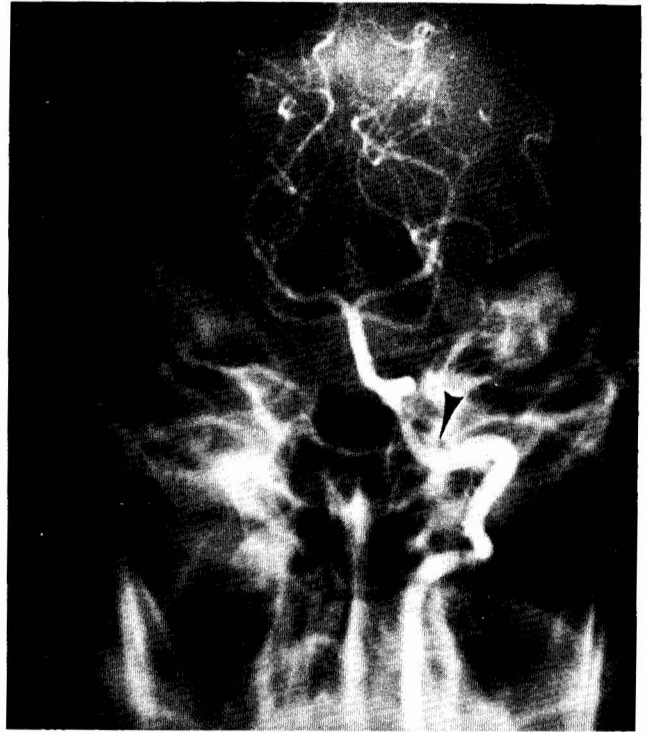


FIG. 1. Case 2. Anteroposterior projection of the preoperative left vertebral angiogram demonstrates focal stenosis. The vertebral artery pierces the dura (arrowhead) and then immediately turns rostrally along the lateral side of the medulla.

fashion, and a calcified, adherent plaque was removed completely by separating the plaque from the vessel wall (Fig. 3). To ensure that no intimal flap was created distally, we extended the arteriotomy and removed all intimal tags meticulously. The arteriotomy was closed with a simple running suture of 8-0 Prolene (Ethicon, Inc., Somerville, New Jersey). At the end of the repair, the vertebral artery had good pulsations and appeared patent. The patient experienced no changes in her vital signs or electrocardiogram pattern during the procedure. She did not undergo systemic heparinization for the vertebral clamping because of our experience with bleeding from the cervical muscles in Case 1. We used 1% heparinized saline irrigation during the endarterectomy and the arterial repair.

Postoperatively, the patient experienced no neurological deficit and she has suffered no further vertebrobasilar TIAs during the 4 months since operation. In March 1980, the patient returned for an elective left carotid endarterectomy, and angiography revealed a widely patent left vertebral artery with improved filling of the brain stem circulation (Fig. 4). A left carotid endarterectomy was performed without complication and the patient remains asymptomatic.

## DISCUSSION

Focal stenosis of the vertebral artery in the region of C-1 is often assumed to be caused by the dura surrounding the artery as the artery enters the subarachnoid space. This was not true in our two cases, and we emphasize that the point of entrance of the vertebral artery through the dura can be accurately determined with angiography. We found in both our autopsy and surgical cases that the vertebral artery ran at right angles to the dura covering the cervical-medullary junction, pierced it, and then immediately turned rostrally to assume a more

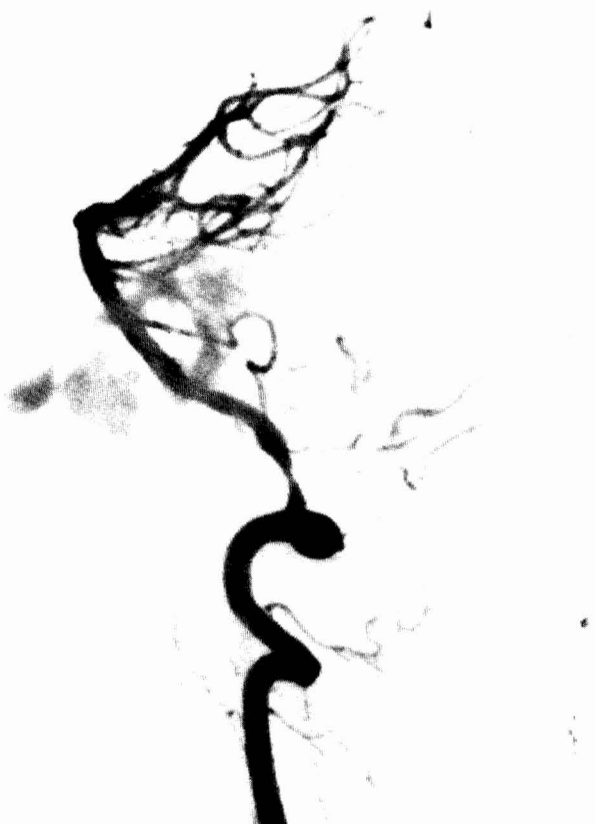

FIG. 2. Case 2. Lateral projection of the preoperative left vertebral angiogram (subtracted) demonstrates both focal stenosis and poststenotic dilatation.

parallel course with the medulla (Fig. 1). Surgically, the accessibility of the vertebral artery as it runs along the medulla can be determined from the angiogram by measuring the distance of the vertebral artery from the midline and allowing for one-half the width of medulla at this point. In three autopsy cases in which the operation was performed and in these two surgical cases, the vertebral artery was accessible to the level of the rostral part of the olive and was limited by the retractability of the rootlets of the 9th and 10th cranial nerves, which cross the vertebral artery posteriorly. In one of our autopsy cases the entire hypoglossal nerve also crossed posterior to the vertebral artery, and in our first surgical case a few rootlets crossed posterior. This anatomical variant could present technical problems at operation.

In Case 1 we found the plaque to be more extensive than had been anticipated from the angiogram and, because of the possibility of leaving a distal intimal flap, we decided not to remove the plaque. More surgical experience with this operation will allow us to determine whether this was a correct judgment. It is significant that the patient was neurologically intact after the operation but 2 weeks later, while anticoagulated with dicumarol (prothrombin time, 15 seconds; control time, 11.5 seconds), she began to experience TIAs and sustained a medullary stroke. She has made a good recovery from this stroke, but she continues to have TIAs while receiving dicumarol.

In Case 2, the plaque was quite localized and poststenotic dilatation was evident. The plaque was calcified, its yellow

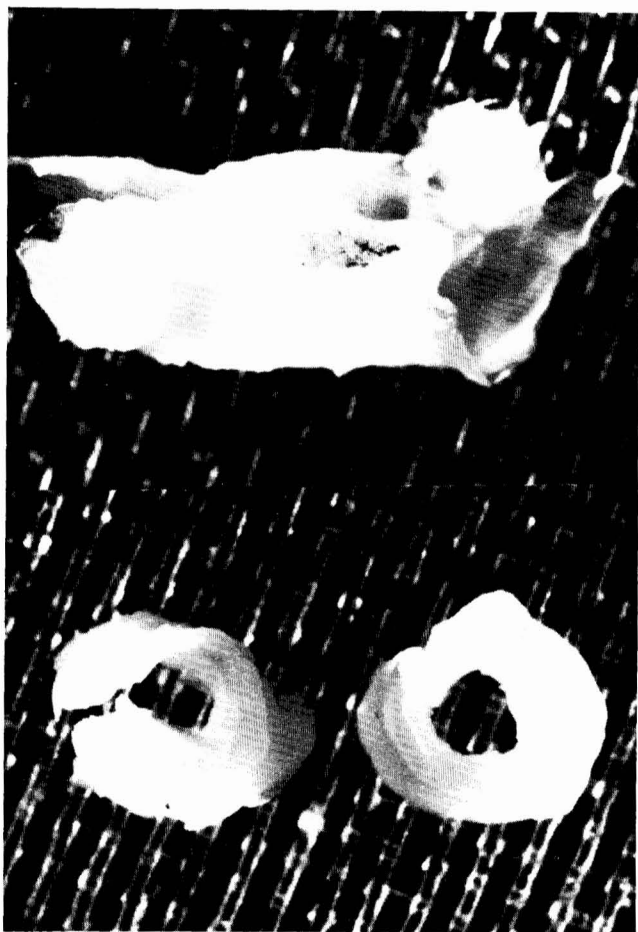

FIG. 3. The atherosclerotic plaque that was removed from Patient 2. The distal end of the plaque is on the right in both views. The actual length of the plaque is 1 cm.

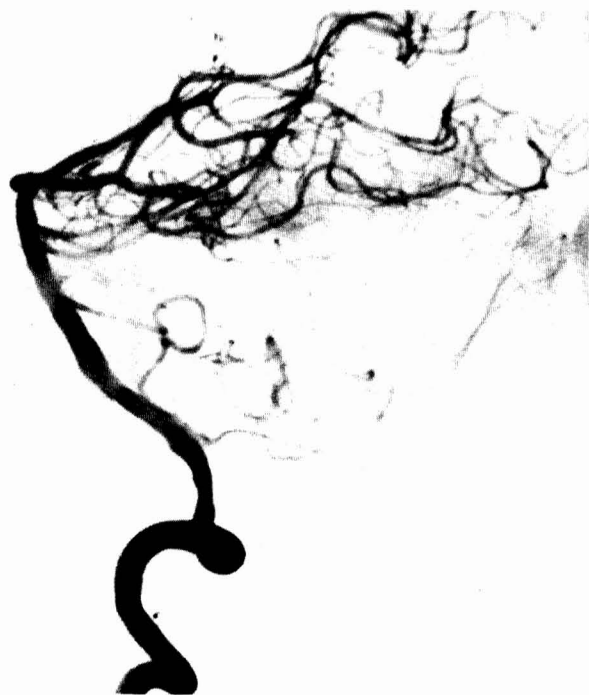

FIG. 4. Case 2. Lateral projection of the postoperative left vertebral angiogram (subtracted) taken 3 months after operation.

irregular inner surface fragmented easily, and grossly it appeared to be similar to plaques removed from the carotid bifurcation (Fig. 3). It is plausible from the appearance of the plaque that this patient's symptoms, especially her visual hallucinations, could have resulted from embolization. However, embolization as an etiological basis for vertebrobasilar TIAs is difficult to prove in a given patient because the emboli cannot be visualized directly here as they can be in the retinal circulation (2). Fisher et al., however, have documented pathologically that such emboli do occur in some cases of lateral medullary stroke (5). Our Patient 2 has been free of symptoms since her operation, in contrast to Patient 1.

Symptoms in our two cases continued even while the patients were on adequate anticoagulation and antiplatelet therapy. In both cases an occipital artery to distal loop of the PICA bypass, as first described by Khodadad (7), was not feasible because there was no PICA in Case 2 and because the stenotic lesion was distal to the PICA in Case 1. Furthermore, such a bypass may not be effective in patients who have a stenotic lesion because their symptoms may be embolic in origin.

The frequency of proximal intracranial vertebral artery stenosis in patients with vertebrobasilar TIAs is difficult to determine. Many patients with vertebrobasilar TIAs are not studied angiographically, and those who are usually have only one vertebral artery injected with contrast medium. Also, in contrast to carotid TIAs, the symptoms of vertebrobasilar TIAs often do not show clinically which vertebral artery might be responsible. It is well documented that occlusion or stenosis of the intracranial vertebral artery is a common cause of lateral medullary infarcts (Wallenberg's syndrome) (1, 5, 8). In the Cooperative Study the frequency of stenotic lesions of the intracranial vertebral arteries was 3.8% for the right side and 4.9% for the left side (6). In a clinicopathological study of 178 cases of atherosclerosis of the vertebral and carotid arteries, Fisher et al. have shown that infarcts in the posterior circulation arise from intracranial occlusive disease (4). Extracranial occlusive disease of the vertebral arteries more often leads to transient symptoms (3).

To the best of our knowledge, this represents the first report of successful endarterectomy involving the intracranial vertebral artery in which a true atherosclerotic plaque has been removed and the vessel has been reconstructed with microsurgical techniques. The endarterectomy site was patent angiographically 3 months after operation, and the patient has remained free of symptoms and is not on anticoagulant or antiplatelet therapy. It remains to be determined whether: (a) a significant number of patients will be candidates for this operation, (b) the operation will have acceptable morbidity and mortality rates, and (c) the operation will prevent transient and permanent neurological deficits in these patients.

Received for publication, August 11, 1980; accepted, September 14, 1980.

Reprint requests: George S. Allen, M.D., Ph.D., Associate Professor, Department of Neurosurgery, Blalock 1415, The Johns Hopkins Hospital, 601 North Broadway, Baltimore, Maryland 21205.

## REFERENCES

1. Currier RD, Schneider RC, Preston RE: Angiographic findings in Wallenberg's lateral medullary syndrome. *J Neurosurg* 19:1058-1067, 1962.
2. Fisher CM: Observations of the fundus oculi in transient monocular blindness. *Neurology (NY)* 9:333-347, 1959.
3. Fisher CM: Occlusion of the vertebral arteries: Causing transient basilar symptoms. *Arch Neurol* 22:13-19, 1970.
4. Fisher CM, Gore J, Okabe N, White PD: Atherosclerosis of the carotid and vertebral arteries—extracranial and intracranial. *J Neuropathol Exp Neurol* 24:455-476, 1965.
5. Fisher CM, Karnes WE, Kubik CS: Lateral medullary infarction—the pattern of vascular occlusion. *J Neuropathol Exp Neurol* 20:323-379, 1961.
6. Hass WK, Fields WS, North RR, Kricheff II, Chase NE, Bauer RB: Joint study of extracranial arterial occlusion: II. Arteriography, techniques, sites, and complications. *JAMA* 203:961-968, 1968.
7. Khodadad G: Occipital artery-posterior inferior cerebellar artery anastomosis. *Surg Neurol* 5:225-227, 1976.
8. Krayenbuhl H: L'aspect angiographique de la thrombose de l'artère cérébelleuse postérieure et inférieure dans le syndrome dit de Wallenberg. *Neurochirurgie* 1:45-51, 1955.

## COMMENT

The subject of intracranial endarterectomy, particularly involving the posterior circulation, is of particular interest currently. Doctors Allen, Cohen, and Preziosi have described two patients with significant generalized arteriosclerosis who both had stenotic lesions of the vertebral artery. One of these underwent a successful intracranial vertebral endarterectomy. Although an isolated case, it is provocative because it reminds us of our incomplete understanding of this disease process and it also demonstrates the potential success that may be achieved with this form of surgical intervention.

I am unable to draw any conclusions from these two patients, but note the lack of clarity with which we consider the mechanism of action in symptom production with intracranial stenotic lesions. If indeed the problem is embolic showering, then it is unfortunate that anticoagulant-antiplatelet therapy does not provide control of the symptoms. However, the direct surgical treatment of this lesion assists in eliminating the intrinsic pathological condition, whether it be hemodynamic or embolic. The use of an extracranial to intracranial bypass graft fails to answer either of these problems directly. Also, it is not totally possible when evaluating the patient with the successful endarterectomy to determine whether long term benefits were gained from the intracranial procedure or from the subsequent carotid extracranial endarterectomy, which is indeed thought by some to be the treatment of choice in 90% of patients with vertebrobasilar insufficiency.

Indeed, more detailed angiography is essential in assessing the cause and the most desirable mode of treatment in patients with vertebrobasilar vascular symptoms. Delineation of the extent of plaque formation would assist in patient selection. Also, there are technical questions such as how critical is a shunt during the procedure; how important is the distalmost aspect of the atheromatous plaque; and is a smaller vascular suture such as 10-0 most desirable?

These authors have addressed a very important question concerning a perplexing clinical problem of ischemia. Continued, yet more precise attention to all aspects of this problem is essential if we hope to provide a more meaningful solution.

Charles R. Neblett, M.D.  
Houston, Texas