

Anterior Spinal Artery Syndrome During the Postpartum Period

To the Editor.—The anterior spinal artery syndrome is an unusual cause of myelopathy during pregnancy and the postpartum period. In 1938, Barré and D'Andrade reported a case of anterior spinal artery infarction involving the fourth and fifth thoracic cord segments occurring during the seventh month of pregnancy¹ and confirmed at the time of necropsy. We have recently seen a similar case.

Report of a Case.—A 26-year-old woman, on her 20th day post partum after her fourth uncomplicated pregnancy and delivery, felt a deep burning pain in the chest and back that spread rapidly to the legs. After ten minutes, she was unable to move her legs or to void. There had been no preceding illness, neurologic symptoms, or symptoms of collagen vascular disease.

The blood pressure was 110/70 mm Hg and pulse rate 90 beats per minute. The chest was clear and the results of a cardiac examination were normal. The urinary bladder was distended. There was no spinal deformity or spinal tenderness to percussion. Mental status was normal and the cranial nerve functions were intact. There was a flaccid paraplegia that affected the abdomen and legs. Muscle stretch reflexes were absent in the legs. There were no abdominal reflexes. Pain sensation was lost below T-4; however, light touch, vibratory, and position senses were intact.

Hemoglobin level was 12.5 vol% and WBC count 7,000/cu mm. Tests for sickle cell disease, lupus erythematosus, and antinuclear factors were negative. Measurements of routine blood chemistries, prothrombin and partial thromboplastin determinations, and protein electrophoresis had normal results. The VDRL test was nonreactive. At the time of lumbar puncture, the CSF opening pressure was 140 mm H₂O, with normal manometrics; there was a CSF protein level of 93 mg/dL, glucose level of 68 mg/dL, and 522 RBCs and five lymphocytes per milliliter. Cultures of blood and CSF were negative for pathogens. A myelogram was normal. Two weeks later, the CSF protein level was 50 mg/dL, glucose level was 59 mg/dL, and IgG level was 3.9 mg/dL.

Over the following month, the sensory level dropped to T-10, with only minimal motor improvement. She has remained confined to a wheelchair and has required ileal loop diversion for urinary function.

Comment.—The diagnosis of anterior spinal artery infarction is made from the characteristic clinical presentation.^{2,3} The onset is usually abrupt, with the maximum deficit acquired immediately or, less frequently, after progression over several hours. A severe pulsating pain is often present from the onset and may last for several days. This may be a lancinating radicular pain, localized to the dermatome of the uppermost involved segment, or a diffuse tract pain, radiating from the level of the lesion into the legs. Initially, there is areflexic flaccid paraplegia. This converts later to a spastic paraplegia. Pain and temperature senses are characteristically spared. Urinary retention is present at the onset, but bladder function may occasionally be restored. Myelography is most often normal, but may reveal cord swelling at the level of the infarction. Though any level may be involved, the watershed area at the fourth thoracic segment is the most common site of infarction.⁴

The cause of this spinal cord infarction is not known. In reviews^{5,6} of thrombotic cerebrovascular disease occurring during pregnancy and the puerperium, there are speculations that arterial infarcts may be due to hormonal effect on cerebral vascular endothelium or to the combined effect of preexisting atheroma and the normal hypercoagulable state of pregnancy. The period of maximum risk is the latter half of pregnancy and the puerperium, with half the infarcts occurring prior to delivery and half afterwards. The same speculations would also apply to spinal vascular disease.

DAVID W. DUNN, MD
Department of Psychiatry and Neurology
Tulane University School of Medicine
1415 Tulane Ave
New Orleans, LA 70112
JEFFREY ELLISON, MD
Ochsner Foundation Hospital
New Orleans, LA 70121

1. Barré JA, D'Andrade C: Paraplegia par ramollissement aigu unisegmentaire de la moelle, survenue au cours de la grossesse. *Rev Neurol* 1938;69:133-135.

2. Steegman AT: Syndrome of the anterior spinal artery. *Neurology* 1952;2:15-35.

3. Moossy J: Vascular disease of the spinal

cord, in Baker AB (ed): *Clinical Neurology*. Hagerstown, Md, Harper & Row Publishers Inc, 1976, vol 3, chap 34, pp 12-13.

4. Henson RA, Parsons M: Ischaemic lesions of the spinal cord. *Q J Med* 1967;36:205-222.

5. Cross JN, Castro PO, Jennett WB: Cerebral strokes associated with pregnancy and the puerperium. *Br Med J* 1968;3:214-218.

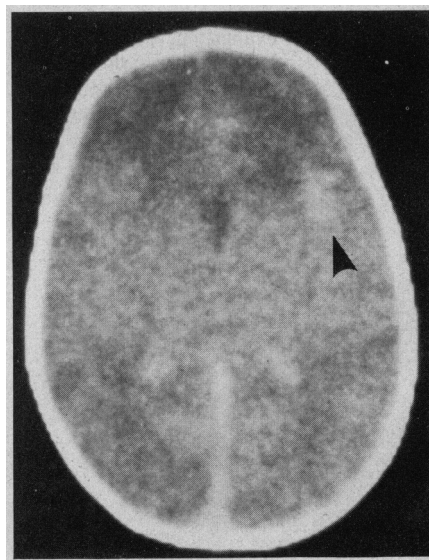
6. Amias AG: Vascular disease in pregnancy: Occlusion. *J Obstet Gynecol Br Com* 1970;77:312-325.

Epileptic Mother

To the Editor.—The review on the pregnant epileptic by Montouris et al (*ARCHIVES* 1979;36:601-603) succinctly summarized several important fetal and neonatal complications of maternal anticonvulsant therapy. Although the problem of anticonvulsant-related teratogenesis has received considerable attention in recent years,¹⁻³ other complications, particularly hemorrhagic disease, can pose more immediate and potentially life-threatening problems in the neonatal period.

We recently cared for a term newborn infant in whom an intracranial hemorrhage developed as a complication of anticonvulsant-induced hemorrhagic disease. The infant had no external evidence of hemorrhage, and

Computed tomographic scan showing right frontal intraparenchymal hemorrhage (arrow).



the neurologic symptoms the infant experienced were initially attributed to barbiturate withdrawal. However, a head computed tomographic (CT) scan disclosed an intraparenchymal cerebral hematoma.

Report of a Case.—A 2,900-g male infant was born after a 38-week gestation to a 33-year-old woman. Her six previous pregnancies had resulted in two living children and four first-trimester spontaneous abortions. Six months prior to this pregnancy, the woman had experienced her first grand mal convulsion. Neurologic evaluation had failed to disclose a cause for the seizures, and phenytoin sodium and phenobarbital sodium had been prescribed.

During pregnancy, the mother's serum phenobarbital and phenytoin levels were closely monitored, and the anticonvulsant dosages were increased appropriately in an attempt to maintain therapeutic levels. A single generalized convulsion occurred during the seventh month of pregnancy.

Vaginal delivery after a 12-hour uncomplicated labor yielded a meconium-stained infant with Apgar scores of 5 and 8 at one and five minutes, respectively. Physical examination revealed a tachypneic infant who had moderate hepatomegaly, a slightly depressed nasal bridge, and hypoplastic toenails. Weight, length, and head circumference were appropriate for the infant's gestational age.

Initial laboratory studies included a chest roentgenogram that showed cardiomegaly and increased pulmonary markings that suggested congestive heart failure. Coagulation studies indicated marked prolongation of prothrombin time (PT), 84 s (control, 12 s), and of partial thromboplastin time (PTT), 106 s (control, 37 s), which both corrected to normal with the addition of normal plasma *in vitro*. The platelet count, WBC count, hematocrit value, and RBC morphology were normal. Other normal results of laboratory studies included serum sodium level, serum calcium level, serum creatinine concentration, blood glucose level, BUN, serum bilirubin level, and SGOT. The ECG and echocardiogram were also normal.

After initial evaluation, the infant was considered to have coagulation defects secondary to maternal anticonvulsant administration and physical signs that suggested

the fetal hydantoin syndrome. Following intravenous administration of phytonadione, the PT and PTT improved to 15.9 s (control, 12.7 s) and 61 s (control, 36 s), respectively, by 12 hours of age.

On the second day of life, the infant appeared irritable and had impaired sleep patterns, excessive hunger, and exaggerated suck and root responses. At 40 hours of age, he experienced a two-minute seizure characterized by opisthotonus, tonic extension of the extremities, and cyanosis. Blood chemistry studies, including blood glucose level, serum calcium level, serum sodium level, and serum magnesium level, as well as arterial oxygenation, showed no abnormality immediately after the seizure. Cerebrospinal fluid examination showed normal glucose level, a protein level of 298 mg/dL, 150,000 RBCs per cubic millimeter, negative cultures for bacterial pathogens, and negative counterimmunoelectrophoresis. Head CT scan (Figure) disclosed an intraparenchymal hematoma in the right frontal lobe. Phenobarbital sodium (5 mg/kg) was prescribed and the infant had no further seizures.

Comment.—This infant's postnatal course illustrates the hazards facing the newborn infant who is exposed *in utero* to maternal anticonvulsants. The infant had a depressed nasal bridge and hypoplastic toenails, stigmata of the fetal hydantoin syndrome. Furthermore, he had laboratory evidence of impaired blood coagulation and experienced CNS symptoms that suggested barbiturate withdrawal.

Both phenobarbital and phenytoin may produce fetal vitamin K deficiency and predispose the infant to bleeding.^{4,5} This drug-induced disorder occurs in the first 24 hours of life, in contrast to physiologic vitamin K deficiency that appears on the second to the fifth day of life. At least 27 cases of anticonvulsant-induced neonatal hemorrhage have been reported, and ten of these cases have resulted in death. In a fatal case described by Bleyer and Skinner,⁶ autopsy disclosed multiple sites of hemorrhage in both brain and spinal cord.

Our experience with this infant emphasizes the need to monitor closely the infant of the epileptic mother. Clotting abnormalities should be identified and treated aggressively. In addition, several authors have recommended that phytonadione be given to the epileptic mother immediately prior to the delivery of her infant.^{6,7} Although withdrawal symptoms commonly occur in infants exposed to barbiturates,⁸ a seizure should be considered an atypical manifestation of withdrawal and other causes should be sought. Intracranial hemorrhage should be suspected in all infants with clotting abnormalities and CNS symptomatology that might be otherwise attributed to anticonvulsant withdrawal. We recommend that CT scans be performed on these infants to confirm or exclude this important diagnostic consideration.

JAMES F. BALE, JR, MD
Division of Pediatric Neurology
ROBERT W. ALLEN, JR, MD
JOAN HULME, MD
MICHAEL L. WYMAN, MD
Intermountain Newborn Intensive
Care Center
University of Utah Medical Center
Salt Lake City, UT 84132

1. Speidel BD, Meadow SR: Maternal epilepsy and abnormalities of the fetus and newborn. *Lancet* 1972;2:839-843.
2. Monson RR, Rosenberg L, Hartz SG, et al: Diphenylhydantoin and selected congenital malformations. *N Engl J Med* 1973;289:1049-1052.
3. Hanson JW, Smith DW: The fetal hydantoin syndrome. *J Pediatr* 1975;87:285-290.
4. Solomon GE, Hilgartner MW, Kutt H: Coagulation defects caused by diphenylhydantoin. *Neurology* 1972;22:1165-1171.
5. Mountain KR, Hirsch J, Gallus AS: Neonatal coagulation defect due to anticonvulsant drug treatment in pregnancy. *Lancet* 1970;1:265-269.
6. Bleyer WA, Skinner AL: Fatal neonatal hemorrhage after maternal anticonvulsant therapy. *JAMA* 1976;235:626-627.
7. Livingston S, Pruce I, Pauli LL: Antiepileptic drug interactions and teratogenicity. *Pediatr Ann* 1979;8:103-114.
8. Desmond MM, Schwanecke RP, Wilson GS, et al: Maternal barbiturate utilization and neonatal withdrawal symptomatology. *J Pediatr* 1972;80:190-197.