

Blunt Injuries to the Carotid and Vertebral Arteries

Robert Dragon, MD, New Britain, Connecticut

Harry Saranchak, MD, New Britain, Connecticut

Paul Lakin, MD, New Britain, Connecticut

Gerald Strauch, MD, New Britain, Connecticut

Although blunt injuries to the carotid and vertebral arteries are relatively rare, they produce major morbidity and, in perhaps as many as 40 percent of the cases reported, permanent neurologic deficit that precludes gainful employment [1]. No more than 130 cases of blunt carotid injury and 40 cases of vertebral injury have been reported in the English literature since 1952 [1-10]. All reports, however, indicate that the possibility of injury to these vessels should be considered in any patient who, after a latent interval following injury, whether severe or minor, begins to develop neurologic signs or symptoms. If investigated and treated aggressively, permanent neurologic deficit or even mortality may be avoided. Our experience with the following patients serves to underscore the problems associated with diagnosis and management of these lesions.

Case Reports

Case I. A 24 year old white man was admitted to another institution after an auto accident with a primary complaint of pain in the right side of the chest. Initial radiography revealed pneumothorax and an undisplaced fracture of the right first rib. The pneumothorax was treated with tube thoracostomy, and the patient remained stable for the first 8 hours after the accident. Left hemiparesis then developed. Angiography showed occlusion of the right carotid artery, which was interpreted as an artifact. Cranial perforator openings were made without improvement in the neurologic status. The patient was transferred to our institution 10 days after the accident, and the carotid artery was explored on the 14th day. Attempts at thrombectomy were unsuccessful, and the patient has persistent hemiparesis 10 years after the injury.

Case II. A 45 year old white woman experienced a brief flashing light in the left eye 2 days before admission. On hemiparesis followed by difficulty with speech. Examination revealed a harsh left cervical bruit. Angiography revealed a typical "string sign" indicative of carotid arterial dissection (Figure 1). The patient underwent successful exploration and repair. She related that 2 days before

hospitalization, she had undergone chiropractic manipulation and had had severe pain in the left side of the neck. She has no neurologic deficit today.

Case III. A 21 year old woman was involved in an auto accident and was thought to have incurred a left cervical injury on the steering wheel of the vehicle. The patient was neurologically intact of the scene of the accident, but after 45 minutes of observation, aphasia, paralysis in the right arm and paresis developed in the right leg. Angiography done immediately revealed an apparent 5 mm pseudoaneurysm with an intimal flap above the aneurysm in the left internal carotid artery (Figure 2). Exploration disclosed that the artery contained intraluminal clot and had been disrupted longitudinally as well as transversely. The disrupted vessel was excised and a vein graft interposed (Figure 3). Although improvement was slow in the immediate postoperative period, the patient has had excellent recovery of function over the past 14 months, and the deficits are detectable only with exhaustive testing.

Case IV. A 14 year old boy was admitted to the hospital after being struck by an automobile. He complained only of discomfort in the back. Clinical, laboratory and radiologic examinations revealed no evidence of serious injury. He was discharged from the hospital after several days, in good condition and with no neurologic signs or symptoms. Two and one-half weeks after injury, he was brought to the hospital dead after collapsing at home. Autopsy revealed that the cause of death was delayed hemorrhage from disruption of the left carotid artery in the neck. A massive hematoma extended from the neck into the mediastinum, where rupture into the right pleural cavity had occurred.

Case V. A 35 year old man flexed his neck suddenly while scolding his son and felt something snap on the right side of the neck. He felt weak, experienced diplopia and lost his equilibrium. One hour later he had a severe occipital headache, weakness in the right arm and leg and impaired swallowing. Angiography suggested dissection of the right vertebral artery (Figure 4). His condition stabilized while he was under observation, and he underwent anticoagulation. He became asymptomatic after a few days. Angiography 1 month later revealed the vessel to be normal (Figure 5). He has no neurologic deficit at present.

Comments

Ninety percent of carotid injuries reported in the literature were caused by penetrating injuries [2]. Most vertebral artery injuries, on the other hand,

From the Departments of Surgery and Radiology, New Britain General Hospital, New Britain, Connecticut.

Requests for reprints should be addressed to Gerald Strauch, MD, New Britain General Hospital, New Britain, Connecticut 06050.

Presented at the 61st Annual Meeting of the New England Surgical Society, Portsmouth, New Hampshire, September 26-28, 1980.

appear to be secondary to blunt trauma [7]. About 60 percent of blunt carotid injuries are caused by motor vehicle accidents. Direct blows and falls each account for 15 percent of cases [1-6]. In most cases, the injury to this vessel occurs in the area extending from the common carotid bifurcation to the skull [1,5]. The mechanisms of injury as outlined by Crissey and Bernstein [8] are direct blows to the vessel, hyperextension and rotation, blunt intraoral trauma and basilar skull fracture. It appears that hyperextension and rotation are by far the most significant modes of injury to the vertebral arteries [7,11]. Although produced by major traumatic events such as motor vehicle accidents, vertebral arterial occlusion or spasm has been documented after chiropractic manipulation, Yoga exercises and other mild traumatic events such as that in our fifth patient [7].

The angiographic findings of arterial injury range from slight irregularity secondary to an intimal flap, to more significant dissections associated with the string sign, as seen in our second and fifth patients [12], to total occlusion of the vessel as seen in patient I. Very severe injury to the vessels can produce complete severance followed by false aneurysm formation, as noted in patient III. The neurologic defects observed can be attributed to thromboembolic

events, impaired perfusion or abrupt cessation of perfusion.

Several clinical features aid in the recognition of such an injury. A bruit may be present in as many as 20 to 30 percent of cases. While some patients may have a cervical hematoma, 50 percent of patients in collected series had no objective evidence of cervical injury. Horner's syndrome, present because of asso-

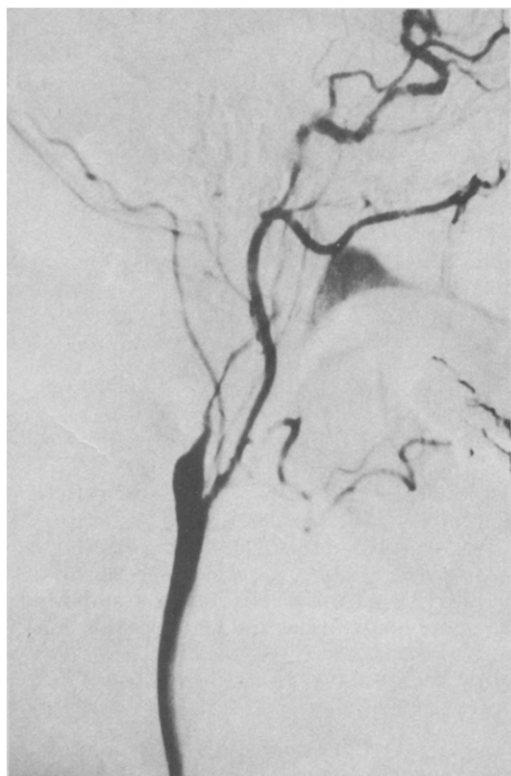

Figure 1. Case II. Subtraction views of the carotid artery with the "string sign" of the internal carotid artery indicative of dissection.

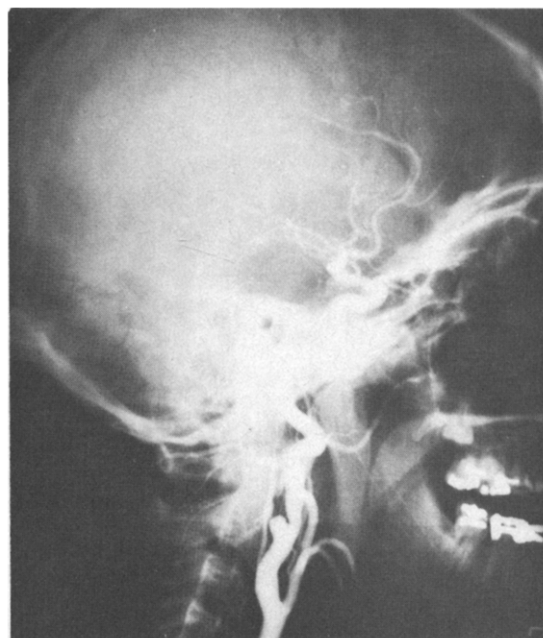


Figure 2. Case III. Carotid angiogram revealing a false aneurysm of the internal carotid artery with intimal flaps above the aneurysm.

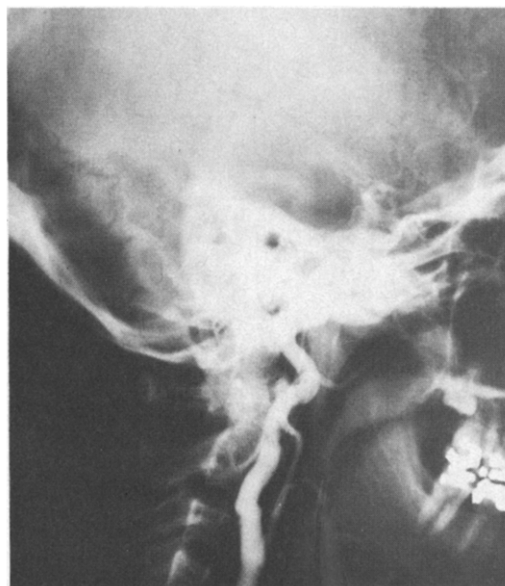

Figure 3. Case III. Carotid artery after repair with interposition vein graft.

ciated injury to cervical sympathetic ganglia, is helpful in diagnosis if present. Ninety percent of patients characteristically display a lucid interval of 1 or more hours before the onset of neurologic deficits, whether transient ischemic attacks or stroke [1,2,5]. Some injuries to the carotid arteries were not detected at the time of insult and presented much later as stenotic lesions or aneurysms producing transient ischemic attacks [13].

These injuries do not always occur as isolated events. They are frequently associated with other injuries, and they can be difficult to distinguish from intracranial injuries. Fortunately, most of the patients are alert rather than obtunded on presentation. Intracranial injury can be ruled out quickly and effectively with computed tomographic scanning. With an obvious deficit and normal findings on computed tomographic scanning, angiography is then indicated to rule out significant cervical vascular injury.

Three basic methods of therapy have been described in the literature: anticoagulation, ligation of the injured vessel and repair of the vessel. All three methods have provided acceptable results. Our fifth patient, for example, responded well to anticoagulation, which is the method advocated by some [14]. However, in patients with a large central neurologic deficit or a large cervical hematoma, the hazard of producing further hemorrhage is apparent. Ligation, the first surgical approach used for carotid arterial injury, is an acceptable means of controlling an ex-

panding hematoma in a hemodynamically unstable patient with a large central deficit. The results of ligation with minimal deficit are far inferior to reconstruction.

Reconstruction, whether by simple tacking of an intimal flap, by reentry procedures for more complicated dissections [12], or by resection and grafting of severely injured vessels, appears to yield the best results in patients with transient ischemic attacks or mild neurologic deficits [1,2]. Coma has ominous prognostic significance when seen after injury. In one collected series only 21 percent of comatose patients left the hospital alive and well. That same analysis of reported cases tends to support reconstruction even in patients with severe central deficits, such as our third patient [2]. The risk of producing hemorrhagic cerebral infarction must be appreciated in these patients but may be less of a problem than reported in the earlier literature [4]. Most reported deaths were caused by stroke or associated injuries. We were unable to find another death similar to that of our fourth patient.

Summary

A small series of patients with blunt injury to either a carotid or vertebral artery is presented. In three patients the injury was recognized relatively promptly. Two underwent surgery and one was observed with reasonably good results. In two patients the injury was unrecognized, resulting in death in one patient and in a severe, fixed, long-term neurologic deficit in the other. It appears likely that recon-

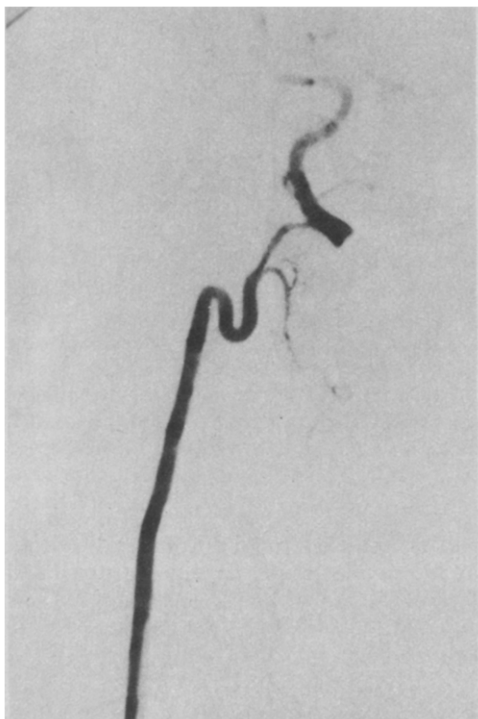


Figure 4. Case V. Subtraction film of "string sign" vertebral artery suggestive of dissection.

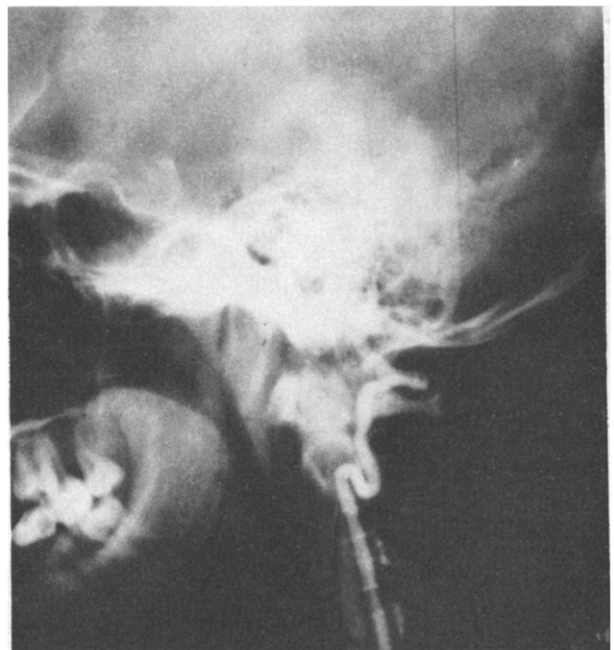


Figure 5. Case V. Angiogram of the same vertebral artery as in Figure 4, 1 month later.

struction may be the treatment of choice in any patient with angiographically proven injury unless coma or severe dense hemiplegia is present.

References

1. Krajewski LP, Hertzner NR. Blunt carotid artery trauma: report of two cases and review of the literature. *Ann Surg* 1980; 191:341-6.
2. Unger SW, Tucker WS Jr, Mrdeza MA, et al. Carotid arterial trauma. *Surgery* 1980;87:477-87.
3. Hoffman TH, Richardson JD, Flint LM. Intimal disruption of major cerebral vasculature following blunt trauma. *Surgery* 1980;87:441-4.
4. Ledgerwood AM, Mullins RJ, Lucas CE. Primary repair versus ligation for carotid artery injuries. *Arch Surg* 1980;115: 488-93.
5. Yamada S, Kindt GW, Youmans JR. Carotid artery occlusion due to nonpenetrating injury. *J Trauma* 1967;7:333-42.
6. Rubio PA, Reul GJ, Beall AC Jr, et al. Acute carotid injury: twenty-five years' experience. *J Trauma* 1974;14:967-73.
7. Heros RC. Cerebellar infarction resulting from traumatic occlusion of a vertebral artery. *J Neurosurg* 1979;51:111-3.
8. Crissey MM, Bernstein EF. Delayed presentation of carotid intimal tear following blunt craniocervical trauma. *Surgery* 1974;75:543-9.
9. Davidson KC, Werford EC, Dixon GD. Traumatic vertebral artery pseudoaneurysm following chiropractic manipulation. *Radiology* 1975;115:651-2.
10. Avellanosa AM, Glasauer FE, Young OH. Traumatic vertebral arteriovenous fistula associated with cervical spine fracture. *J Trauma* 1977;17:885-8.
11. Okasawa S, Nibbelink D. Vertebral artery occlusion following hyperextension and rotation of the head. *Stroke* 1974;5: 640-2.
12. Ojemann RG, Fisher CM, Rich JC. Spontaneous dissecting aneurysm of the internal carotid artery. *Stroke* 1972;3: 434-40.
13. Busuttill RW, Davidson RK, Foley KT, et al. Selective management of extracranial carotid arterial aneurysms. *Am J Surg* 1980;140:85-91.
14. Towne JB, Neiss DD, Smith JW. Thrombosis of the internal carotid artery following blunt cervical trauma. *Arch Surg* 1972;104:565-8.

Discussion

John Davis (Burlington, VT): I have personally seen only two cases of blunt trauma to the carotid artery, but I think they substantiate the authors' major point. One injury was a hematoma that occurred after an auto accident. Because of its large size, exploration was considered mandatory. Carotid arteriography showed a tear in the carotid artery, and repair was undertaken. This patient had no neurologic deficit, and he might have done alright if nothing had been done. I think he would have developed a false aneurysm and needed surgery later, but he probably would have survived without neurologic deficit.

The second case was probably a karate chop; some kind of bare hand hit the side of the neck. The patient had some slurring of speech. He was also inebriated, making examination difficult. A house officer suggested that we perform carotid arteriography, which demonstrated an intimal flap that was then repaired. Again, the patient had no neuro-

logic deficit and probably would not have because I think Sir Astley Cooper showed many years ago that in most persons one can ligate a carotid artery without neurologic deficit.

The situation is such that every surgeon is and should be an angiographer. I am concerned when surgeons will not attempt to evaluate arteries by this method. In few hospitals can angiography be performed immediately by the radiologist. The surgeon can perform it immediately on the operating table by placing the needle in the artery, injecting dye and taking one or more pictures using a portable roentgenographic unit. I believe we should perform reconstruction in all patients, based on the fact that many of them will have associated head injuries, particularly those in auto accidents. One cannot afford the possibility that failure to improve the circulation may be detrimental.

It is rare that a patient's carotid artery cannot be repaired at the time of surgical intervention for other injuries. The neck incision and repair of the carotid artery carry a very low morbidity and mortality. I think one should repair the artery at that time. I do not know whether it will affect the outcome, but I do not think there is any way to determine that in advance in most of these patients. My view is that repair should be performed, and unless it is a very unusual situation it will not add to the morbidity or the mortality.

Anthony S. Patton (Salem, MA): The extracranial vessels may be the cause of what appears to be an intracranial problem. We had a similar experience some years ago. A 30 year old man who was left-handed entered with severe blunt chest trauma and seemed to be on the way to recovery. He initially had a normal aortic arch study and was stable without a respirator. Ten days later, he suddenly had left hemiparesis and stopped breathing. Emergency angiography showed an occlusion to the right internal carotid artery. Operation disclosed the artery to be severely damaged and the intima embolized into the distal stump. This was removed, with great trepidation, with a Fogarty catheter, and the patient awoke immediately. A vein graft was needed for reconstruction, and the patient eventually did well. There was no evidence of any neck injury. I hope more such cases will be recognized and successfully treated.

John B. Ballou (Salem, MA): The fifth case in which the irate father scolded his son and had a thrombosis of the vertebral artery represents a form of blunt trauma to the vertebral arteries from just turning the neck. I would like to bring to the Society's attention another case that just occurred within the past week. An elderly woman recovering from a bowel resection woke up with quadriplegia. We found subluxation of the third or fourth cervical vertebra, which we felt had been incurred by hyperextension of the neck at the time of intubation for anesthesia.

Robert Dragon (closing): I would like to thank Dr. Davis for his comments and can only concur with him that any injured patient who, after a latent interval, develops any neurologic signs or symptoms should undergo immediate angiography.