
Case Reports

Headache in Cerebral Embolic Disease

SANFORD H. AUERBACH, M.D., RUSSELL B. BUTLER, M.D.,
AND HARVEY L. LEVINE, M.D.

SUMMARY A patient is presented who had severe headache and then developed a stuttering course of clinical neurological deficits. Arteriography demonstrated an ipsilateral proximal middle cerebral embolus. With recurrence of symptoms, repeat arteriography showed another, more proximal embolus with areas of distal occlusion. The headache probably occurred when the embolus became lodged in a pain sensitive cerebral vessel at the base of the brain. The subsequent stuttering neurological deficits were due to fragmentation of the embolus as well as recurrence.

Stroke, Vol 12, No 3, 1981

HEADACHE has been described in 8 to 18% of patients with cerebral emboli.^{1,2} Despite speculation as to the cause of this symptom, there has been no angiographic documentation to support any of the theories presented. The patient reported had a clinical presentation with headache and a stuttering clinical course. The embolic etiology of the cerebral vascular disease was demonstrated by serial angiography.

J.F., a 53-year-old right handed male, had a 2-day severe, throbbing, incapacitating headache over the left temple. On the day prior to admission he had a 10 to 20 minute episode of numbness and tingling of his right arm. His previous medical history was characterized by unstable angina which he had had since a myocardial infarction 7 years before. This had been treated with Nitropaste. He also was treated for congestive heart failure with digoxin and Lasix. He had never before had migraine or other headache.

The initial examination revealed a normal blood pressure and no bruits over the carotid arteries. The neurological examination was negative. One hour later, however, he had recurrence of right arm numbness and language deficit. Examination at this time demonstrated a mild right hemiparesis and a non-fluent language abnormality. An ECG was abnormal with sinus bradycardia, left ventricular hypertrophy and evidence of an old anteroseptal infarction. Lumbar puncture indicated the pressure, glucose and cell counts were normal. The spinal fluid protein was 96 mg%. Computerized tomography of the brain revealed no abnormalities.

A left carotid cerebral arteriogram showed a filling defect in the horizontal segment of the middle cerebral artery with distal small vessel occlusion. There was no

evidence of carotid artery disease in the neck. A repeat CT scan demonstrated presence of a left parietooccipital infarction.

Sodium heparin and Coumadin were given. One week after the patient's admission the heparin was stopped and the next day the patient had recurrence of the severe headache and neurological symptoms. A repeat CT scan was unchanged. At this time Coumadin was discontinued and the heparin restarted, resulting in improvement of symptoms. A repeat arteriogram showed a new filling defect in the left internal carotid artery, as well as multiple occlusions of more distal branches of the middle cerebral artery. He was subsequently switched back and maintained on Coumadin with no recurrence of symptoms.

Discussion

This patient had angiographic evidence of cerebral embolic disease and a presentation with headache and a stuttering course. The cerebral angiograms fulfilled the diagnostic criteria for emboli described by Dalal et al.³ and Ring.⁴ (figs. 1, 2). In this patient the repeated demonstration of normal proximal carotid arteries led to the belief that his emboli were cardiac in origin.

Wells¹ and Fisher⁶ describe the occurrence of headache in embolic cerebral disease. Headache is not a common symptom, appearing in less than 10% of Wells' 120 patients. The headache was generalized in half of the patients and was on the side of vessel occlusion in the other half. Fisher⁶ described the pain as being referred to the ipsilateral temporal region. Both authors postulated that the pain was due to lodging of the embolus in the proximal, pain sensitive part of an artery at the base of the brain. Arteries in this region have been demonstrated to be sensitive to stretching, mechanical stroking and electrical stimulation.⁷ Until the present patient, however, there has been no reported angiographic evidence of a relationship between the headache and the embolus location.

The stuttering course described in embolic disease⁸ may be the consequence of 1) An embolus becoming

From the Departments of Neurology and Radiology, Veterans Administration Medical Center, 150 South Huntington Ave., Boston, MA 02130 and the Boston University School of Medicine, Boston.

Reprints: Dr. Butler, Dept. Neurology, Veterans Administration Medical Center, 150 S. Huntington Ave., Boston, MA 02130.

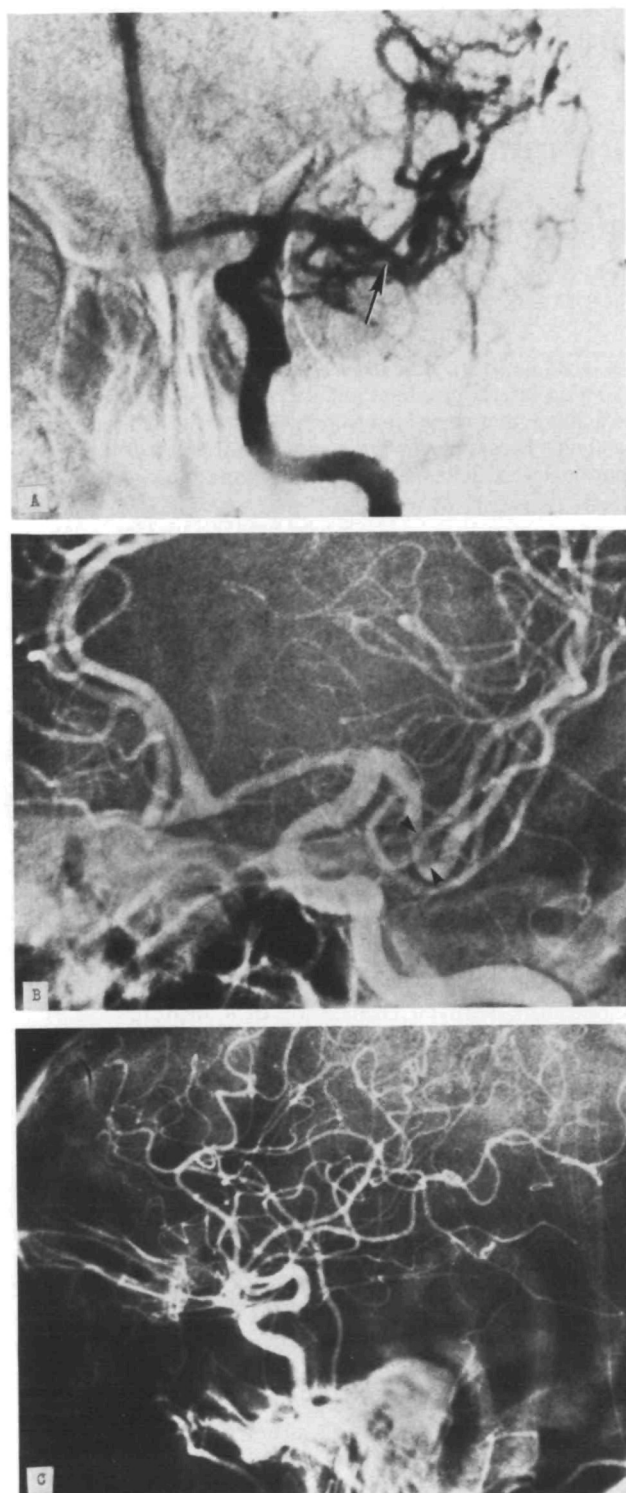


FIGURE 1. Left carotid arteriogram. A. Anteroposterior projection. There is a filling defect (arrow) in the middle of cerebral artery. B. Oblique projection. The filling defect is seen more clearly (arrowhead). The appearance on this projection is more typical of an embolus. C. Lateral projection. The carotid siphon is normal.

lodged proximally and the resulting distal ischemia relieved by establishment of collateral flow, 2) an embolus may become dislodged and new symptoms occur as the fragments occlude smaller vessels, 3) there may

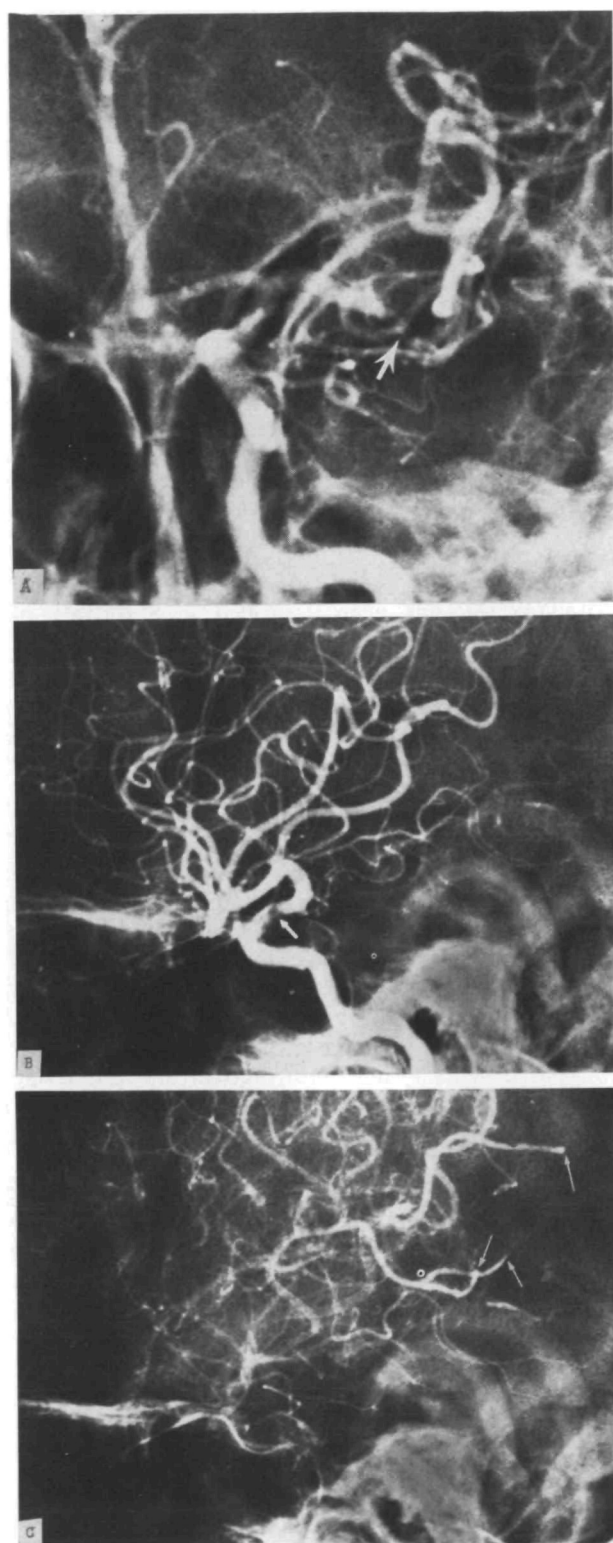


FIGURE 2. Left carotid arteriogram. A. Anteroposterior projection. The filling defect in the horizontal portion of the middle cerebral artery (arrow) is larger, and there is extension into the bifurcation of this vessel. The appearance is compatible with either further embolization or propagation of thrombus from the original embolus. B. Lateral projection. A new filling defect is seen in the carotid siphon (arrow) indicating further embolization. C. Late arterial phase of lateral projection. Three occluded middle cerebral artery branches (arrow) due to embolic fragments.

be recurrent emboli to the same vessel, 4) fragmentation of emboli. In this patient the probable cause of recurrent symptoms was recurrent emboli.

This demonstrates the observation made by Wells⁹ that there is a predilection for emboli to lodge consistently in the same arterial distribution.

References

1. Wells CE: Premonitory symptoms of cerebral embolism. *Arch Neurol* 5: 44-50, 1961
2. McDowell F: Cerebral Embolism" *In* Vinken PJ, Bruyn GW (eds) *Handbook of Clinical Neurology*. Vol 5. American Elsevier Publishing, New York, NY, 1972
3. Dalal PM, Smith SC, Deschamps CK: Cerebral embolism. *Lancet* I: 51-65, 1965
4. Ring BA: Diagnosis of embolic occlusion of smaller branches of the intracerebral arteries. *Am J Roentgenol* 97: 575-582, 1966
5. Fisher CM, Pearlman AL: The non-sudden onset of cerebral embolism. *Neurology (Minneapolis)* 17: 1025-1032, 1967
6. Fisher CM: Headache in cerebrovascular disease. *In* Vinken PJ, Bruyn GW (eds) *Handbook of Clinical Neurology*, Vol 5. American Elsevier Publishing Co. Inc., New York, 1968
7. Wolff HG: Headache and Other Head Pain. Oxford University Press, New York, 1948
8. Miller RD, Jordan RA, Parker RL, Edward JE: Thromboembolism in acute and in healed myocardial infarction. II: Systemic and pulmonary arterial occlusion. *Circulation* 6: 7-15, 1952
9. Wells CE: Anticipation of emboli. *In* Millikan CH, Sickert RH, Whisnant JP (eds) *Cerebral Vascular Disorders*, Third Princeton Conference. Grune and Stratton, New York, 1961

Reactive Hyperemia for the Clinical Diagnosis of Subclavian Steal Syndrome: Report of a Case

MARK SHARON, M.D., RICHARD W. ASINGER, M.D.,
AND MORRISON HODGES, M.D.

SUMMARY The diagnosis of subclavian steal syndrome in a patient was strengthened by utilizing reactive hyperemia of the ipsilateral arm to reproduce the presenting clinical symptoms.

Stroke, Vol 12, No 3, 1981

SUBCLAVIAN STEAL is caused by a stenotic or occlusive lesion in the proximal subclavian or innominate artery. Blood flow to the distal subclavian artery and the ipsilateral upper extremity is via retrograde flow in the ipsilateral vertebral artery. This reversed flow may be asymptomatic or may "steal" blood from the vertebral-basilar system causing central nervous system ischemia.¹ The presenting clinical complex of the subclavian steal syndrome may be related to ischemia of the central nervous system, ipsilateral upper extremity, or both.² The history, physical examination and even angiographic findings may not be diagnostic of this syndrome. Thus, a provocative test may be needed to confirm the diagnosis. Exercise of the ipsilateral upper extremity has been utilized as such a test but negative results may occur even in patients with documented subclavian steal syndrome.³ Since most patients with this syndrome are older, prolonged or vigorous arm exercise may not be feasible. Hence another form of test would be helpful in establishing the diagnosis.

We recently examined a patient with subclavian steal syndrome in whom the clinical diagnosis was strengthened by a provocative test we used. We utilized reactive hyperemia of the ipsilateral arm to reproduce the presenting clinical symptoms.

Patient Report

A 76-year-old male was admitted to the Hennepin County Medical Center because of a pelvic fracture resulting from a syncopal episode. He had had syncopal episodes for 17 years, with an average frequency of 2-3 episodes per week. Syncope occurred mainly during moderate exertion or after a heavy meal. He could not relate his symptoms to upper extremity exercise. He described presyncopal symptoms of unsteadiness, vertigo, and visual blurring which lasted 30 seconds to several minutes.

His past medical history was significant for chronic alcohol abuse and coronary artery bypass surgery 8 years prior to admission. The patient denied having angina since the bypass operation and was on no medication. Holter monitoring showed infrequent premature ventricular contractions and occasional sinus pauses up to 1.6 seconds duration. His symptom complex, however, did not occur during Holter monitoring.

Physical exam revealed a blood pressure of 120/70 in the right arm and 70 palpable in the left arm. The heart rate was 78 and regular. The cardiovascular exam revealed bilateral carotid and subclavian bruits (R > L). The left brachial pulse was decreased in amplitude and delayed in arrival when compared with the right. Cardiac exam demonstrated a grade II/VI holosystolic murmur at the apex. The remainder of the exam, including neurological examination, was unremarkable.

From the Cardiology Sections and the Departments of Medicine, Hennepin County Medical Center and the University of Minnesota, Minneapolis, MN.