

Spontaneous Disappearance of Carotid Stenosis¹

Pulla R. S. Kishore, M.D., and Arthur R. Dick, M.D.

Angiographic diagnosis of atheromatous plaques is usually well correlated with surgical and pathologic findings. Hemorrhage into such plaques is believed to be frequent, but is seldom diagnosed angiographically. The authors report a case of intramural hemorrhage into an atheromatous plaque with subsequent resolution. A brain scan of a woman, age 52, with right hemiparesis and dysphasia showed increased isotope uptake in the left frontotemporal region. Arteriography 10 days after onset of symptoms showed a plaque in the left carotid bifurcation. Clinical improvement followed. Repeat arteriography 12 weeks later revealed almost normal left carotid bifurcation.

INDEX TERMS: Carotid arteries, stenosis • Cerebral angiography, indications • (Cerebral vessel, atherosclerotic stenosis, 1[7].721 • (Common carotid artery bifurcation, atherosclerotic plaque, 1[72].7215) • (Common carotid artery bifurcation, atherosclerotic stenosis with hematoma, 1[72].7216)

Radiology 129:721-722, December 1978

ANGIOGRAPHIC DIAGNOSIS of atheromatous plaque is usually correlated well with surgical and pathologic findings. Complicated lesions such as ulcerative plaques and associated thrombus at the site of stenosis, are often seen clearly at angiography but occasional discrepancies are noted between angiographic findings and surgical or pathologic findings (1). Hemorrhage into an atherosclerotic plaque occurs frequently in the natural history of atherosclerotic vascular disease (2). The latter phenomenon often leads to an increase in the stenotic lesion. However, a diagnosis of hemorrhage in the plaque is seldom made by arteriography. We report a case of probable hemorrhage, observed angiographically, into an atherosclerotic plaque in the internal carotid artery. A review of the literature did not disclose to us a similar case.

CASE REPORT

A 52-year-old white woman was found unconscious. The evening before, she had complained of mild bifrontal headache followed by weakness of the right upper and lower extremities. Upon admission she had dysphasia and right hemiparesis. Lumbar puncture revealed CSF with a normal cell count, protein, and pressure. Her dysphasia and right hemiparesis improved over a period of one week. She was transferred to the University of Kansas Medical Center for further evaluation where examination revealed a regular pulse rate of 64, regular respirations of 24 per minute and blood pressure of 120/80. Neurological examination revealed dysphasia, mainly receptive, with right hemiparesis, weakness of the lower half of the right side of the face, and a Babinski sign on the right. The remainder of the physical examination was unremarkable.

Routine laboratory findings were within normal limits. The electrocardiogram was also normal. Electroencephalography revealed focal slowing over the frontal-temporal area. Skull and chest radiographs were normal, and the brain scan revealed increased isotope uptake in the left frontotemporal region (Fig. 1).

A left common carotid arteriogram was obtained 10 days after the onset of symptoms. The common carotid artery proximal to the bifurcation was normal. An irregular plaque extended from the bifurcation into the internal carotid artery (Fig. 2). Stenosis was also seen in the external carotid artery. Minimal stenosis was noted in the intracranial portion of the internal carotid artery in the pre-cavernous and cavernous segments. The intracranial circulation was otherwise unremarkable. The patient tolerated the procedure well and there was no change in neurological status during or following arteriography. The patient was discharged and readmitted 12 weeks later for repeat arteriography and

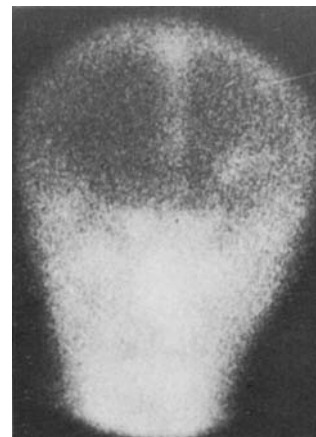

Fig. 1. Radionuclide brain scan (Tc99m), shows increased uptake in left frontotemporal region consistent with cerebral infarction.

possible surgery. She was asymptomatic except for minimal weakness of the right upper extremity. Aortic arch and left carotid arteriography revealed minimal stenosis involving the bifurcation. The irregular plaque seen in the internal carotid artery on the examination, 12 weeks earlier, was absent (Fig. 3). No surgical lesion was seen in the brachiocephalic vessels and the patient was discharged.

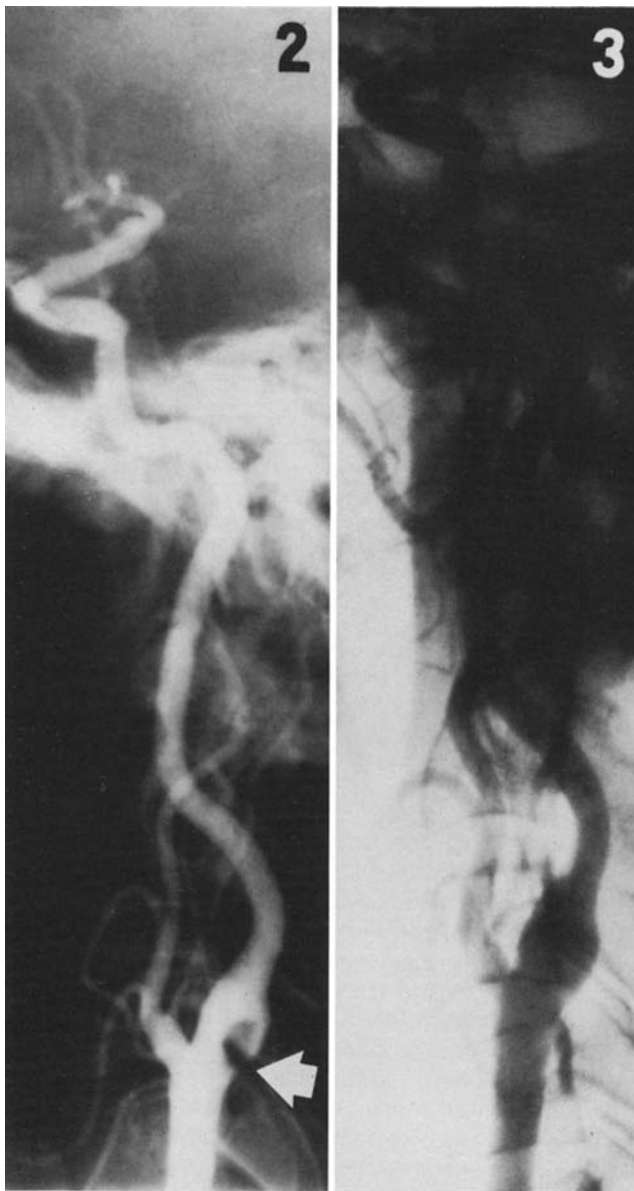
DISCUSSION

Stenotic lesions due to atheromatous disease are usually progressive (3). The disappearance of the stenotic lesion in our case, within approximately 12 weeks, suggests a technical artifact, *e.g.*, subintimal injection. However, this possibility is unlikely since the lumina of the common carotid and internal carotid artery are smooth in outline, proximal and distal to the stenosis (Fig. 2). Furthermore, the presence of atherosclerotic vascular disease of the external carotid artery without impairment of flow of contrast material into the distal internal carotid artery at the time of the initial arteriogram, is evidence against subintimal injection. Had this been a subintimal injection, the degree of compromise of the caliber of the lumen was such that neurological deficit might be expected during or following the arteriogram; this did not occur. The positive brain scan is consistent with infarction in the left middle cerebral artery territory occurring at least several days before the first arteriogram.

The arteriographic appearance of this lesion is similar to that of a thrombus. Radiologic diagnosis of an intraluminal thrombus is not difficult if contrast material extends between the arterial wall and thrombus in at least one projection at arteriography (4); Roberson *et al.* reported nine such cases. However, in one of their cases, "there was no definite thrombus" on surgical exploration. The possibility that the lesion in our case was a thrombus is not suggested by arteriography; the absence of progressive neurological deficit or recurrent transient ischemic attacks is additional evidence against thrombus. A more reasonable explanation in our case, and possibly that of Roberson *et al.*, is intramural hemorrhage into an atherosclerotic plaque.

Hemorrhage into atherosclerotic plaques is fairly frequent in

¹ From the Department of Radiology, Medical College of Virginia, Richmond, Virginia, and the Department of Neurology (A.R.D.), The University of Kansas Medical Center, College of Health Sciences and Hospital, Kansas City, Kansas. Received for publication on April 27, 1978. Accepted on June 22, 1978



pathological specimens (2). However, angiographic diagnosis is often difficult. These hemorrhages are believed to be responsible for progressive stenotic lesions (2). In patients with atherosclerotic cerebrovascular disease, stenotic lesions also show progression (3). In our case, there was virtually complete regression angiographically rather than progression. Our case most likely represents intramural hemorrhage into an atherosclerotic plaque, with subsequent complete resolution.

REFERENCES

1. Kishore PRS: The significance of the ulcerative plaque. *Radiol Clin North Am* 12:343-352, Aug 1974
2. Stehbens WE: *The Pathology of Cerebral Blood Vessels*. C. V. Mosby Co., St. Louis, 1972, pp 98-125
3. Bauer RB, Boulos RS, Meyer JS: Natural history and surgical treatment of occlusive cerebrovascular disease evaluated by serial arteriography. *Am J Roentgenol* 104:1-17, Sep 1968
4. Roberson GH, Scott WR, Rosenbaum AE: Thrombi at the site of carotid stenosis. Radiographic diagnosis. *Radiology* 109:353-356, Nov 1973

Pulla R. S. Kishore, M.D.
Department of Radiology
Box 728
Medical College of Virginia
Richmond, Virginia 23298

Fig. 2. Left common carotid angiogram in lateral projection reveals irregular plaque in the bifurcation extending into the internal carotid (arrow), compromising the lumen by greater than 50%.

Fig. 3. Left common carotid angiogram (subtraction film) in lateral projection (12 weeks after examination in Figure 2) reveals carotid bifurcation and internal carotid artery without evidence of atherosclerotic plaque previously observed.

