

# Post-traumatic Occlusion of the Supraclinoid Internal Carotid Artery

Farroukh Ajir, M.D. and James C. Tibbetts, M.D.

*Division of Neurosurgery, University of Wisconsin Center for Health Sciences and Madison General Hospital, Madison, Wisconsin*

Intracranial occlusion of the internal carotid artery secondary to minor head or neck injury is uncommon. We report the case of an 18-year-old man who sustained a minor head and neck injury during a fist fight and developed a left hemiparesis resulting from thrombosis of the supraclinoid portion of the right internal carotid artery. Conservative inpatient treatment with low dose heparin and aspirin resulted in a gradual, steady improvement. Two months later, after an intensive program of physical therapy, the patient showed good progress; his facial weakness had lessened and his left hemiparesis was mild. Although there is no ideal treatment for internal carotid artery occlusion secondary to minor trauma, conservative treatment should be undertaken unless there are progressive or recurring ischemic symptoms, in which case an extracranial-intracranial bypass operation should be considered. (*Neurosurgery* 9:173-176, 1981)

**Key words:** Arterial occlusion, Arterial thrombosis, Head and neck injury, Internal carotid artery, Low dose heparin, Pseudoaneurysm, Trauma

## INTRODUCTION

Thrombosis of the extracranial portion of the internal carotid artery as a result of nonpenetrating head and neck injury is not uncommon (2, 3, 5, 7, 11, 14, 16). However, intracranial occlusion of the internal carotid artery after minor head and neck injury without skull fracture is rare, and only a few cases of post-traumatic occlusion of the supraclinoid internal carotid artery have been reported (1, 4, 9, 12, 13, 18, 20). We are presenting another case.

## CASE REPORT

An 18-year-old man was hit on his right temple by a fist during a fight and was held around his neck by a forearm for a short time. Immediately after the trauma, he lost consciousness for approximately 20 minutes. When he awoke, he noticed that he was unable to move his left arm and leg. For the first 48 hours after the accident, the patient was kept home by his friends and could not seek medical attention.

He had no history of cardiovascular disease, diabetes, or any other medical problem. He had a history of drug abuse, but had never been on amphetamines. He denied using any drug before the accident.

His physical and neurological examination on admission (2 days after the incident) revealed a thin young man with normal vital signs and in no acute distress. There were no abrasions, bruises, or lacerations, but there was tenderness over the right temple region. The patient was awake, alert, and oriented to time, person, and place. His pupils were equal and reactive to light and accommodation. The extraocular eye movements were full. He had a partial left homonymous hemianopsia, a complete left facial palsy, and tongue deviation to the left. He was unable to move his left hand and arm, and he had a moderate to severe weakness of the left lower extremity. He was unable to maintain his balance in either the sitting or the standing position. An extensor plantar reflex was present on the left side. He had brisk reflexes on the left in comparison to the right side. Skull x-ray films did not reveal any fracture or other abnormality. His routine complete blood count and blood chemistries were normal.

A computed tomographic scan showed an area of decreased density in the right frontotemporoparietal region with minimal

mass effect and shift (Fig. 1). No enhancement was seen with contrast administration. A carotid and vertebral angiogram revealed that the right common carotid artery was normal, as was the right external carotid artery. But the right internal carotid artery was quite narrow and irregular commencing at about the C-1, C-2 level (Fig. 2A). The vessel was patent to the level of the ophthalmic artery, but no flow was seen beyond that point (Fig. 2, B and C). The left carotid artery was normal in the neck and in its intracranial arborization. Both pericallosal arteries were perfused via the left carotid artery. No flow was seen across the right A-1 segment. The right pericallosal artery arborized over the convexity, and there was retrograde flow in several right middle cerebral branches via surface collaterals from the anterior cerebral artery. The vertebral injection demonstrated a normal posterior circulation. The

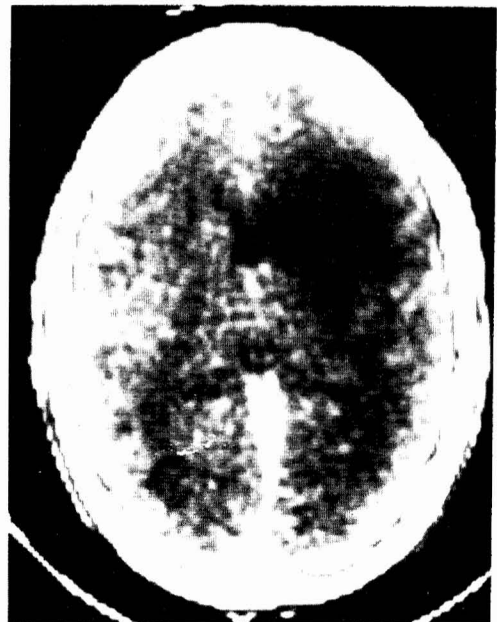


FIG. 1. Computed tomographic scan reveals an area of decreased density in the right frontotemporoparietal region.

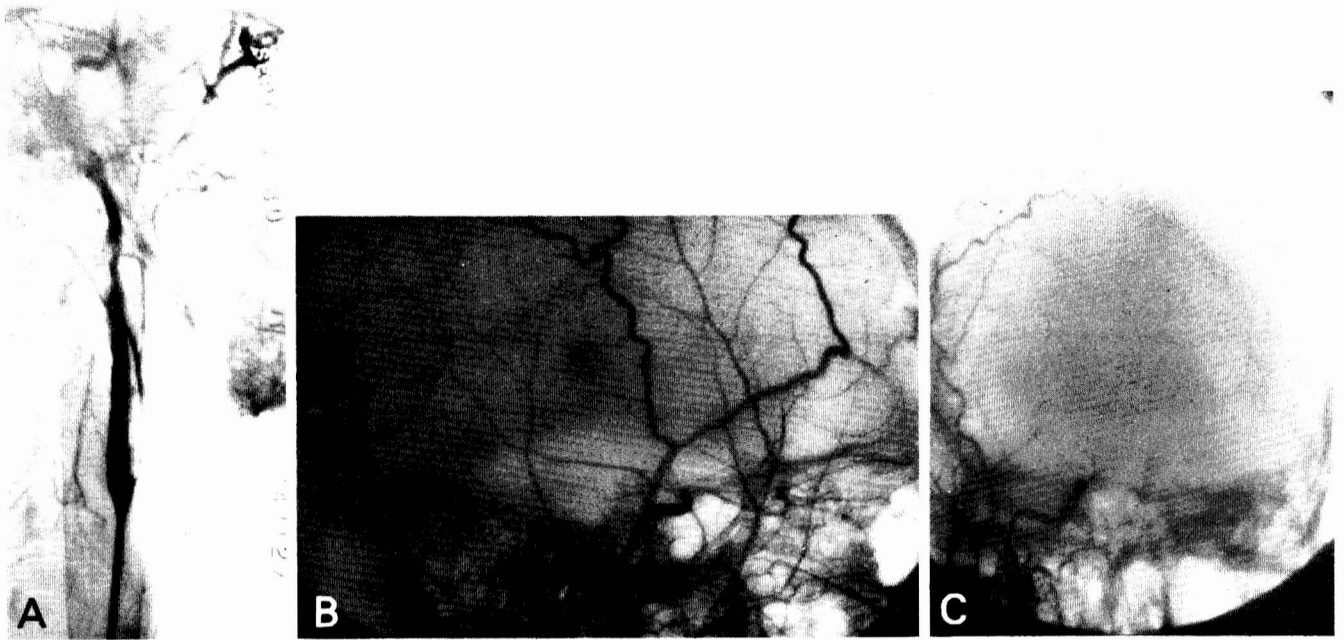


FIG. 2. Initial carotid angiogram shows (A) narrowing and irregularity of the cervical portion and (B and C) complete occlusion of the supraclinoid portion of the right internal carotid artery.

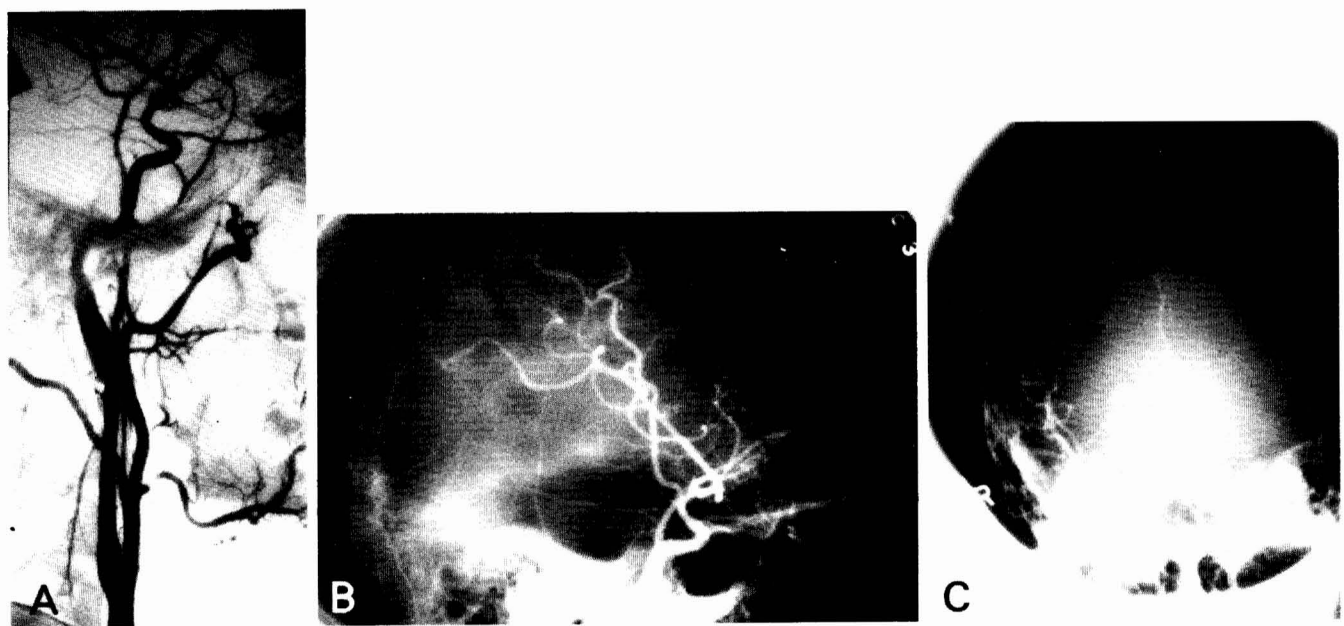


FIG. 3. Right carotid angiogram repeated 2 months later reveals (A) the formation of a long, fusiform pseudoaneurysm of the cervical portion and (B and C) reopening of the supraclinoid portion.

proximal right middle cerebral artery, the right anterior cerebral artery, and the supraclinoid carotid artery never filled and were presumably thrombosed. The patient was placed in the intensive care unit with the diagnosis of right frontotemporo-parietal infarction as a result of internal carotid artery occlusion. Treatment with heparin (4000 units subcutaneously every 8 hours) and aspirin (325 mg twice a day) was begun. His left homonymous hemianopsia improved gradually and he showed some improvement in his lower extremity weakness, although no immediate change occurred in his left central facial or arm

plegia. The patient was then transferred to the rehabilitation service for aggressive physical therapy.

Two months later the patient was readmitted for a repeat angiogram. His neurological examination revealed that his facial weakness had lessened. He had a mild to moderate left hemiparesis, but was able to walk without any help or support. A repeat angiogram showed that the right internal carotid artery was patent. There was good flow through the supraclinoid portion and through the right anterior and middle cerebral arteries (Fig. 3, B and C). The right internal carotid artery in

the neck just proximal to the skull base showed changes compatible with a relatively long fusiform pseudoaneurysm extending to the skull base (Fig. 3A). The patient was discharged and will be followed.

### DISCUSSION

Hemiparesis or any other neurological sign in a patient with head injury is usually the result of epidural, subdural, or intracerebral hematoma or cerebral contusion. Sometimes focal signs may be secondary to the occlusion of a major cerebral artery with infarction (6, 8). Traumatic occlusion of the internal carotid artery in its petrous, cavernous, or supraclinoid portion is not very common (1, 12, 15, 17, 19, 21). Only a few cases of post-traumatic occlusion of the supraclinoid internal carotid artery without skull fracture have been reported (4, 9, 12, 13, 18-20). After atherosclerosis, trauma is the second most common cause of carotid artery occlusion in adults. In children and young adults, trauma is the major cause of internal carotid artery thrombosis (1, 2, 10).

The mechanism whereby thrombosis occurs is not yet known. Several theories have been proposed, including trauma to the wall of the artery leading to intimal damage, emboli, and spasm with eventual thrombosis; injury elevating the intima and initiating thrombosis or emboli; and spasm of an artery slowing down the flow and creating turbulence, thereby promoting thrombosis (3, 7, 10, 12, 15, 16). The mechanism of thrombosis in our patient is unknown. It is possible that during the fight, trauma caused a tear in the intima in the cervical portion of the internal carotid artery, forming a clot, which migrated to the supraclinoid portion. A second possibility is that the intimal tear may have dissected all the way up to the origin of the ophthalmic artery.

A number of treatments of traumatic carotid occlusion have been suggested including heparinization, sympathectomy, thrombolytic agents such as streptokinase and urokinase, hyperbaric oxygen, and hypothermia. There is no ideal treatment. The major considerations in choosing a therapeutic modality are the selection of patients, evaluation of the effectiveness of therapy, and the risks of turning an ischemic infarction into a hemorrhagic infarction (7, 10, 16, 20). In our patient, treatment was begun late after the injury. We treated our patient with small doses of heparin because we did not want to convert a markedly ischemic area to a hemorrhagic infarct, but we hoped to prevent embolization to the distal collateral vessels as the thrombus broke up. We believed that an immediate extracranial-intracranial bypass operation was not indicated, and it seems from the patient's progress that our judgment was correct.

In conclusion, in the differential diagnosis of patients with neurological deficit after minor or major head and neck injury, occlusion of the intracranial portion of the internal carotid artery should be considered. Although these patients may require extracranial-intracranial bypass surgery if there are progressive or recurring ischemic symptoms, conservative management should be considered first.

Received for publication, March 7, 1981; accepted, April 4, 1981.

Reprint requests: Faroukh Ajir, M.D., Division of Neurosurgery, University of Wisconsin Center for Health Sciences, 600 Highland Avenue, Madison, Wisconsin 53792.

### REFERENCES

- Dharker SR, Dharker RS: Traumatic occlusion of internal carotid artery in an infant. *Surg Neurol* 9:77-78, 1978.
- Frantzen E, Jacobsen HH, Therkelsen J: Cerebral artery occlusions in children due to trauma to the head and neck: A report of 6 cases verified by cerebral angiography. *Neurology (NY)* 11:695-700, 1961.
- Gurdjian ES, Hardy WG, Linder DW, Thomas LM: Closed cervical cranial trauma associated with involvement of carotid and vertebral arteries. *J Neurosurg* 20:418-427, 1963.
- Higazi I: Post-traumatic carotid thrombosis: Report of a case with intensive angiographic study of the collateral circulation. *J Neurosurg* 20:354-359, 1963.
- Hockaday TDR: Traumatic thrombosis of internal carotid artery. *J Neurol Neurosurg Psychiatry* 22:229-231, 1959.
- Hollin SA, Sukoff MH, Silverstein A, Gross SW: Post-traumatic middle cerebral artery occlusion. *J Neurosurg* 25:526-535, 1966.
- Kaufman HH, Lind TA, Clark DS: Non-penetrating trauma to the carotid artery with secondary thrombosis and embolism; Treatment by thrombolysis. *Acta Neurochir (Wien)* 37:219-244, 1977.
- Lewin W: Vascular lesions in head injuries. *Br J Surg* 55:321-331, 1968.
- Mastaglia FL, Savas S, Kakulas BA: Intracranial thrombosis of the internal carotid artery after closed head injury. *J Neurol Neurosurg Psychiatry* 32:383-388, 1969.
- Mastaglia FL, Savas S, Kakulas BA, Lekias JS: Thrombosis of the internal carotid artery after closed head injury. *Proc Aust Assoc Neurol* 8:93-100, 1971.
- Olafson RA, Christoferson LA: The syndrome of carotid occlusion following minor craniocerebral trauma. *J Neurosurg* 33:636-639, 1970.
- Recoules-Arche D, Vedrenne C, Mazars G: Les occlusions traumatiques de la carotide interne supra-clinoïdienne. *Neurochirurgie* 22:293-300, 1976.
- Rosegay H: Limited value of carotid pulse in diagnosis of internal carotid thrombosis. *Neurology (NY)* 6:143-145, 1956.
- Schneider RC, Lemmen LJ: Traumatic internal carotid artery thrombosis secondary to nonpenetrating injuries to the neck: A problem in the differential diagnosis of craniocerebral trauma. *J Neurosurg* 9:495-507, 1952.
- Sedzimir CB: Head injury as a cause of internal carotid thrombosis. *J Neurol Neurosurg Psychiatry* 18:293-296, 1955.
- Stringer WL, Kelly DL Jr: Traumatic dissection of the extracranial internal carotid artery. *Neurosurgery* 6:123-130, 1980.
- Thomson JLG: Traumatic thrombosis of the internal carotid artery in the carotid canal. *Br J Radiol* 36:840-842, 1963.
- Torkildsen A, Koppang K: Notes on the collateral cerebral circulation as demonstrated by carotid angiography. *J Neurosurg* 8:269-278, 1951.
- Vigouroux RP, Guillermain P, Maouad M: Les obstructions traumatiques des vaisseaux cérébraux et cervicaux (carotide interne et ses branches). *Rev Otoneuroophthalmol* 50:73-90, 1978.
- Vigouroux R, Lavieille J: Les thromboses post-traumatiques de la carotide interne. *Neurochirurgie* 8:115-142, 1962.
- Yashon D, Johnson AB II, Jone JA: Bilateral internal carotid artery occlusion secondary to closed head injuries. *J Neurol Neurosurg Psychiatry* 27:547-552, 1964.

### COMMENTS

Drs. Ajir and Tibbetts have presented another case of traumatic dissection of the internal carotid artery. I surmise that their patient suffered a hyperextension injury to his neck with an intimal tear of the carotid artery as it was stretched over C-1. The patient probably had an embolus to his supraclinoid carotid artery, resulting in the neurological deficit. The relatively normal appearance of the internal carotid artery between the site of the embolus and the dissection in the neck indicates that there was not an extension of a dissection. I agree with the management and the treatment with heparinization. I question whether this patient should be continued on Persantine or aspirin. If he should develop new emboli, which is a possibility, then I think he would be a candidate for ligation of the internal carotid artery after a superficial temporal/middle cerebral artery anastomosis. A repeat follow-up angiogram would be of interest.

David L. Kelly, Jr., M.D.  
Winston-Salem, North Carolina

The authors have addressed a particularly difficult problem, which is how to deal with vascular complications of head injury. It is important to consider the possibility of vascular injury in patients with head injury who have unexplained neurological deficits and to pursue their evaluation with angiography. Because patients who have vascular injuries may not have symptoms until emboli or occluding thrombi occur and this may be delayed several hours to a few days, it is possible that many patients should have screening angiographic studies, but the indications for this are not yet established. The new technique of digital angiography will soon provide a simple way to evaluate the true incidence and significance of such vascular injuries.

Head-injured patients can be classified according to three categories of vascular problems: patients with impending embolization and occlusion, patients with stenosis or occlusion who are having impaired flow but who have not suffered infarction, and patients who have suffered infarction secondary to vascular occlusion from thrombosis or embolization. In the first group, the medical and surgical therapy must be directed against developing clots and dissection. Antiplatelet agents and anticoagulation may produce stabilization of a clot and give the intrinsic fibrinolytic systems a chance to dissolve it. An even more aggressive approach might include the use of thrombolytic substances, possibly streptokinase or urokinase. An operative approach to accessible lesions might also be used. Fluctuating neurological symptoms might be due to embolization or impaired perfusion from stenosis or occlusion; here, thrombolysis, direct operation on accessible lesions, and bypass may be important. Patients with apparently fixed symptoms may or may not have had an infarction. I hope that in the future this will be determined using regional cerebral blood flow studies or positron emission tomographic scans. Aggressive medical and surgical therapy may be indicated for those

patients who have neurological findings but viable brain. In those patients who have suffered infarction, attempts to prevent further thrombosis or embolization (which might cause problems in more distant viable brain tissue) should also be made, as is suggested by this case, in which heparin was used and the patient's condition was stabilized. The safety of low dose heparin in this situation has not been established, but it well may be a reasonable treatment and it deserves further study.

Post-traumatic vascular spasm was also mentioned. Spasm could lead to slowing of flow, together with intimal injury and alteration of blood, the so-called Virchow's triad of causes of intravascular clotting. However, it is not certain that spasm alone is sufficient to cause thrombus formation. The subject of post-traumatic vascular spasm was reviewed in depth at a recent symposium (1-5).

Howard H. Kaufman, M.D.  
Houston, Texas

1. Adams CBT: Vasospasm: Occurrence in conditions other than subarachnoid hemorrhage from a bleeding aneurysm, in Wilkins RH (ed): *Cerebral Arterial Spasm*. Baltimore, Williams & Wilkins, 1980, p 471.
2. Hughes JT: Morphological changes in human cerebral arteries in relation to intracranial arterial spasm, in Wilkins RH (ed): *Cerebral Arterial Spasm*. Baltimore, Williams & Wilkins, 1980, pp 480-487.
3. Miller JD, Gudeman SK: Cerebral vasospasm after head injury, in Wilkins RH (ed): *Cerebral Arterial Spasm*. Baltimore, Williams & Wilkins, 1980, pp 476-479.
4. Nilsson BI: Vasospasm and the pathophysiology of concussive head injury, in Wilkins RH (ed): *Cerebral Arterial Spasm*. Baltimore, Williams & Wilkins, 1980, pp 488-495.
5. Wilkins RH: Trauma-induced cerebral vasospasm, in Wilkins RH (ed): *Cerebral Arterial Spasm*. Baltimore, Williams & Wilkins, 1980, pp 472-475.