

The Aprosodias

Functional-Anatomic Organization of the Affective Components of Language in the Right Hemisphere

Elliott D. Ross, MD

• It was recently proposed that the affective components of language, encompassing prosody and emotional gesturing, are a dominant function of the right hemisphere, and that their functional-anatomic organization in the right hemisphere mirrors that of propositional language in the left hemisphere. Ten right-handed patients with focal lesions of the right hemisphere and disorders of affective language are described. Observations were made about each patient's spontaneous prosody, prosodic repetition, prosodic comprehension, and comprehension of emotional gesturing. Using this particular examination strategy, which is derived from the usual bedside approach to aphasic disorders, the organization of affective language in the right hemisphere does mirror the organization of propositional language in the left hemisphere. Furthermore, the disorders of affective language seem to be classifiable in the same manner as the aphasias. Thus, the term "aprosodia," preceded by specific modifiers such as motor, global, transcortical sensory, etc, seems appropriate when classifying the various disorders of affective language that occur following right-hemisphere damage. The relationships between affect, mood, pathologic laughing and crying, and depression are also discussed.

(*Arch Neurol* 1981;38:561-569)

In a previous article by Ross and Mesulam,¹ coupled with the observations of Heilman et al² and Tucker et al,³ it was proposed that the affective components of language, encom-

passing prosody and emotional gesturing, were a dominant linguistic feature of the right hemisphere, and that their functional-anatomic organization in the right hemisphere mirrored that of propositional language in the left hemisphere. The recent observations by Larsen and co-workers⁴ regarding changes in regional cerebral blood flow during "automatic speech" give further support to the foregoing ideas. To these investigators' surprise, changes in blood flow occurred in the right hemisphere that were homologous in distribution to those observed in the left hemisphere (supplementary motor area, inferior sensorimotor strip, and posterosuperior temporal lobe). A ready explanation for the right-hemisphere phenomenon was not given because of the traditional belief that language, in general, is a left-hemisphere function. Since the distribution of blood flow in both hemispheres was homologous during automatic speech, it could be argued that whatever the right hemisphere contributes to language, that contribution must be anatomically organized in the same way as propositional language. Most likely, in light of the publications by Heilman et al,² Tucker et al,³ and Ross and Mesulam,¹ Larsen and co-workers were actually observing the functional-anatomic organization of the affective components of language in the right hemisphere.

With this in mind, I began to systematically examine patients with focal right-hemisphere damage for disorders of affective language by using strategies similar to those developed for assessing disorders of propositional language. In classifying an aphasic deficit, four observations are essential:⁵ (1) fluency of spontaneous speech, (2) ability to repeat words, phrases, and sentences, (3)

auditory comprehension of propositional language, and (4) visual-confrontation naming. When using this method of evaluation, eight types of aphasia have been defined, each with a relatively distinctive neuroanatomic localization,^{5,6} ie, motor (Broca's), sensory (Wernicke's), conduction, global, transcortical motor, transcortical sensory, anomia, and mixed transcortical aphasia. Therefore, evaluation of spontaneous prosody and gesturing,⁷ the ability to repeat with prosodic-affective variation,^{2,3} auditory comprehension of the affective components of prosody,^{2,3} and visual comprehension of emotional gesturing in patients with focal lesions of the right hemisphere was undertaken. The ten case reports that follow provide further evidence that the functional-anatomic organization of affective language in the right hemisphere mirrors that of propositional language in the left hemisphere. Furthermore, the affective disorders of language appear to be classifiable in the same manner as the aphasias. Thus, the term "aprosodia," (á' prô só' dia) preceded by specific modifying words such as motor, global, transcortical sensory, etc, seems appropriate when classifying the various disorders of affective language that follow focal right-hemisphere damage (Table).

PATIENTS AND METHODS

The ten patients to be described were referred to me by the neurology house staff of the University of Texas Health Science Center, Dallas, because of my interest in patients with right-hemisphere strokes. Instances of "negative" cases, where a lesion that involved the right peri-Sylvian region did not cause an aprosodia, were not encountered. All patients who I examined who had a right peri-Sylvian lesion also had an aprosodia. One patient with a right superoposterior parie-

Accepted for publication Oct 5, 1980.

From the Departments of Neurology and Psychiatry, University of Texas Health Science Center, Dallas.

Reprint requests to Department of Neurology, University of Texas Health Science Center, 5323 Harry Hines Blvd, Dallas, TX 75235 (Dr Ross).

tal-lobe infarction, confirmed by computed tomographic (CT) scan, was examined but did not have an aprosodia. Since the homologous region in the left hemisphere is not associated with aphasia, this patient's case report has been excluded from this article.

The bedside evaluation of the affective components of language is relatively simple, although some practice is required by the examiner so that he may confidently project differing affective tones through voice and through emotional gesturing during the formal portions of the assessment. The testing procedures outlined below are easily, if not flawlessly, carried out by patients who do not have brain damage regardless of educational background. Thus, judging normal and abnormal performance is not a particularly difficult task. Heilman et al² and Tucker et al³ have developed quantitative testing procedures using audio recordings of professional actors and line drawings to examine some of the affective components of language, but these testing instruments are not commercially available. The bedside technique, on the other hand, allows the clinician to readily incorporate a qualitative assessment of the affective components of language into the routine neurologic examination, much the same way as one conventionally tests for propositional language.

Spontaneous Prosody and Gesturing

In the course of history taking, observations should be made about the prosodic quality of the patient's voice. Overall loudness or softness of speech or the existence of pathologic laughing or crying should be ignored, and the finer aspects of emphasis, intonation, melody, and variability of voice should be assessed (cases 2, 3, and 9). The examiner should ask emotionally loaded questions during the interview, such as how the patient feels about his neurologic disability or if he has had any close calls with death or maiming. The critical distinction for the examiner to make is whether the patient's spontaneous speech is prosodic or aprosodic. This is similar to the judgment of fluency and nonfluency of speech when assessing patients for aphasia. Mismatching of the affective components of language to the semantic content should be noted, since patients with posterior lesions, similar to posterior aphasics, may be "fluent" but have abnormal or inappropriate prosody (cases 4 and 8). In addition, observations concerning the patient's spontaneous gesturing should be made to complete the assessment.

Prosodic-Affective Repetition

This evaluation tests the patient's ability to repeat sentences using the affective components of prosody and requires some acting ability on the part of the examiner. Declarative statements void of emotional words, such as "I am going to the movies" or "We are going to the circus," should be used. The patient is asked to repeat the sentence with the same affective quality as used by the examiner. Thus, when the

examiner says the statement using a happy, sad, tearful, disinterested, angry, or surprised voice, the patient repeats the sentence exactly the same way. Repetition ability should be judged on how well the patient fine tunes his prosodic variation to that of the examiner's. Merely raising or lowering the loudness of voice or raising the voice at the end of a questioning type of statement does not constitute good prosodic repetition, since these elementary aspects of prosody may be preserved when all other prosodic variation is absent (cases 1, 2, and 4).

Prosodic-Affective Comprehension

Auditory comprehension of the affective components of prosody and visual recognition of emotional gesturing should be assessed separately, since these components of affective language may be differentially compromised (cases 5 and 10). Standing behind a patient when testing prosodic comprehension is an expedient way to avoid visual clues. The examiner should use declarative statements void of emotional words in conjunction with differing affective tones and have the patient identify the projected emotion. One may give the patient five or six multiple-choice answers, eg, "Was that said in an angry, sad, happy, indifferent, surprised, or tearful tone," if he initially has trouble with the task, but often this is not necessary. Since this task does not test subtle aspects of prosodic comprehension, one can be sure that a patient has a significant deficit if he does poorly.

Comprehension of Emotional Gesturing

This is a visual-comprehension test for emotional gesturing that is similar to the evaluation of visual-language functions, confrontation naming, and reading in the aphasia examination. One stands in front of the patient and pantomimes an emotional gesture that involves the face and limbs to convey a particular affective state, such as surprise, anger, disinterest, sadness, or elation. The patient is then asked to identify the emotion by name or description. If he initially has trouble with the task, then one should use a multiple-choice format similar to that described for testing prosodic comprehension.

REPORT OF CASES

Motor Aprosodia

CASE 1.—On May 11, 1979, a 63-year-old right-handed man had the abrupt onset of left-hand weakness and dysarthria and was admitted to a hospital in Fort Worth, Tex. He was transferred to the Neurology Service at the Dallas Veterans Administration Hospital on May 18. Examination showed him to be alert and cooperative. He had implicit denial of his left-sided hemiparesis, in that he was aware of the deficit but appeared unconcerned about it. Immediate recall, recent and remote memory, proverb interpretation, and orientation were normal. He had flat affect but denied depression. Propositional language was fully normal and there was no dysarthria.

A mild left-sided lower facial weakness

on volition was present, with decreased response to pin and temperature over the left half of his face and neck. There was a moderately severe left-sided hemiplegia, which affected hand, arm, shoulder, and hip, with sparing of foot and distal part of the leg, and left-sided hemianesthesia, splitting the midline, to pin and temperature, with decreased position and vibration sensations in the distal area of the left upper extremity.

The patient's speech was flat and monotone with little spontaneous prosody, even when he discussed his World War II experiences of liberating the concentration camps in Germany or his son being shot to death the previous year. Spontaneous gesturing was also greatly reduced, which gave the patient a flat affect.

The patient's prosodic repetition was impaired. His speech remained aprosodic except when there was a question at the end of a statement. If one asked him to mimic a tearful or angry sentence using a loud voice, he could raise his voice but was unable to modulate it to convey the correct emotion. The patient's prosodic comprehension and comprehension of emotional gesturing were flawless.

The patient was reexamined on June 11, 1979. His spontaneous prosody and gesturing were good, although he tended to miss the mark on prosodic repetition. However, both he and his wife agreed that his voice was only "80% as musical" as before the stroke. The hemiparesis and sensory deficits were also improved. A repeated CT scan, done June 25, demonstrated a right inferior frontal-lobe and anteroinferior parietal-lobe infarction (Fig 1 and 2, A).

CASE 2.—A 47-year-old right-handed man was admitted to the Neurology Service at the Dallas Veterans Administration Hospital on May 30, 1979, because of a right-sided cerebrovascular accident. Mental status and propositional-language examinations were normal except for a flat affect, with implicit denial of his deficits. He denied being depressed or sad. He had a moderately severe left-sided lower facial weakness, and hemianesthesia to pin and temperature over the left half of his face and neck. Excellent strength and coordination were present in his left limbs, although he was slow to move these limbs on request. There was left-sided hemianesthesia, splitting the midline, to pin and temperature with mild loss of stereognosis and two-point discrimination in the left hand.

The patient's speech was flat with rare prosodic variation. Spontaneous gesturing was markedly reduced, which gave the patient a flat affect. The only emotions he showed were two episodes of uncontrollable crying, when he told me about his son who was in prison for armed robbery. These crying episodes greatly dis-

| The Aprosodias* | | | | |
|----------------------------|-----------------------------------|------------|------------------------|--------------------------------------|
| | Spontaneous Prosody and Gesturing | Repetition | Prosodic Comprehension | Comprehension of Emotional Gesturing |
| Motor† | Poor‡ | Poor | Good | Good |
| Sensory† | Good | Poor | Poor | Poor |
| Global† | Poor | Poor | Poor | Poor |
| Conduction | Good | Poor | Good | Good |
| Transcortical motor | Poor | Good | Good | Good |
| Transcortical sensory† | Good | Good | Poor | Poor |
| Mixed transcortical | Poor‡ | Good | Poor | Poor |
| Anomic§ | Good | Good | Good | Poor |

*The aprosodias in boldface type have been observed and are described in this article. Aprosodias in lightface type are postulated but not demonstrated.

†Good anatomic correlation with lesions in the left hemisphere known to cause homologous aphasias.

‡Spontaneous gesturing, during recovery, may show marked improvement when compared with spontaneous prosody (cases 2 and 9).

§Anomic aprosodia should be the result of a right angular-gyrus lesion akin to the syndrome of anomic aphasia, alexia, and agraphia,⁵ which invariably indicates left angular-gyrus damage. Although spontaneous prosody and gesturing are categorized as good for sensory, conduction, transcortical sensory, and anomic aprosodia, it does not necessarily mean that these features of language will be normal, only present; mismatching of affect to the semantic content of speech may occur (cases 4 and 8).

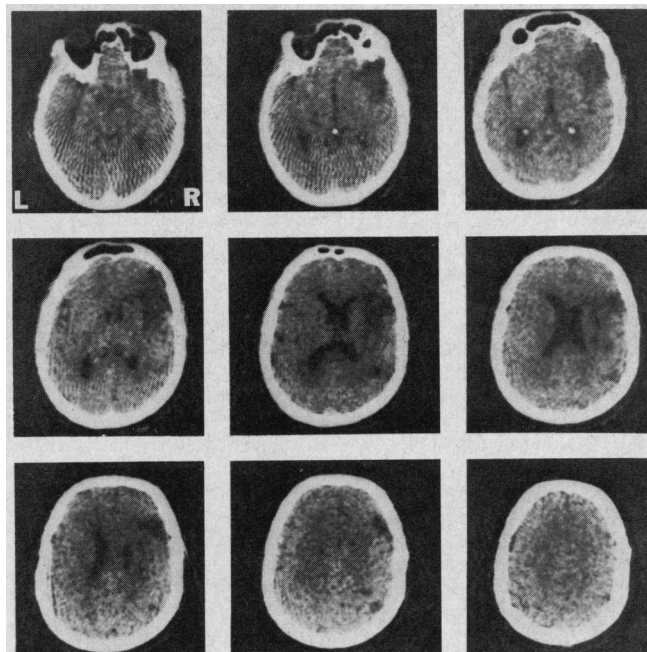
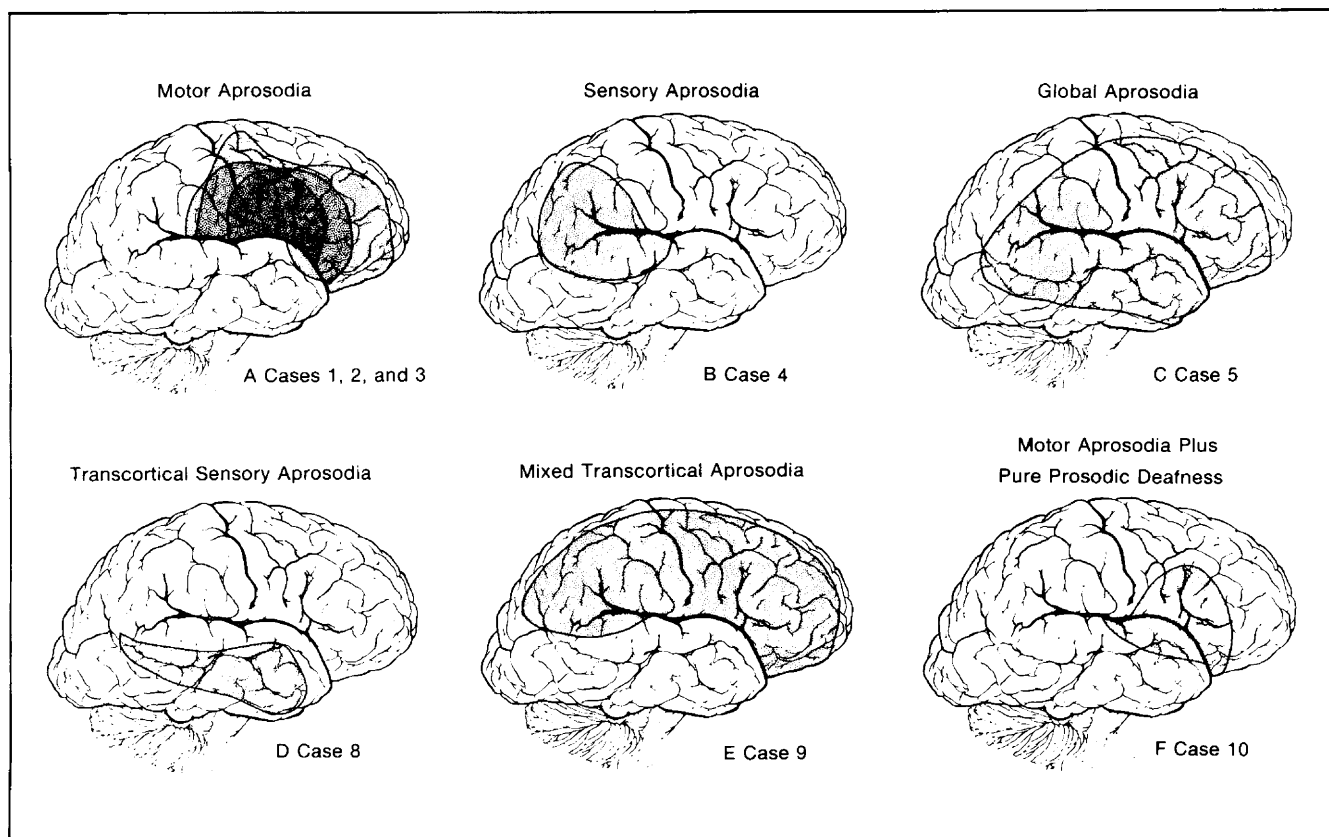


Fig 1.—Computed tomographic scan from patient 1. Infarction involves right frontal operculum, insula, and anterior parietal operculum. Superoposterior temporal lobe is spared.

Fig 2.—Depiction of infarctions observed in patients, with use of right lateral-hemisphere template and the atlas of Matsui and Hirano.²⁴ Various aprosodia and case numbers are as follows: motor aprosodia, cases 1, 2, 3; sensory aprosodia, case 4; global aprosodia, case 5; transcortical sensory aprosodia, case 8; mixed transcortical aprosodia, case 9; motor aprosodia and pure prosodic deafness, case 10.



turbed him since he had never cried before when discussing his son's incarceration.

The patient's prosodic repetition was very poor, although occasionally the patient would imitate the loudness of the examiner's voice without other prosodic variation. The patient's prosodic comprehension and comprehension of emotional gesturing were flawless.

During hospitalization, the severity of his left-sided paralysis fluctuated despite anticoagulation. He ultimately sustained a spastic left-sided hemiplegia, which spared the distal portion of his left lower extremity, and a prominent global sensory loss in his left upper extremity. The disturbance of affective language remained unchanged even at discharge on June 26, except that spontaneous gesturing was now noticeably present in his nonparalyzed right side and face. A CT scan done on June 13, demonstrated a right-sided inferior frontoparietal infarction (Fig 2, A).

CASE 3.—A 35-year-old right-handed man was admitted to the Neurology Service at the Dallas Veterans Administration Hospital on June 6, 1979, because of the subacute onset of a dense left-sided hemiplegia with sensory loss, anosognosia, and a left-sided hemianopsia. Examination on June 18, 1979, showed him to be awake, alert, and cooperative with normal mental status except for a flat affect. He had good insight into his illness. He claimed to feel "depressed" about his stroke, and during the interview he had a number of brief uncontrollable crying episodes that were not appropriate to the context of the discussion. Propositional language was normal. A mild, inattention, left-sided hemianopsia was present. Pin and temperature sensitivity was slightly dysesthetic over the left side of his face, and there was a moderately severe left-sided lower facial paralysis on volition, which was not present when he cried. He had a flaccid left-sided hemiplegia, with marked loss of proprioceptive and cortical sensations and relative sparing of pin and temperature sensations.

His speech was completely flat and monotone, without prosodic variation even when he was describing his mood as being "depressed" and "hopeless." He admitted to suicidal thoughts, but even at this juncture there was no true component of sadness to his voice. The only evident emotion was occasional uncontrollable and inappropriate crying that greatly embarrassed him. He had no observable spontaneous gesturing.

The patient's prosodic repetition was totally flat. He did not even adjust the loudness of his voice to that of the examiner's. His prosodic comprehension and comprehension of emotional gesturing were flawless.

During hospitalization the patient's depression intensified; he became more suicidal and was treated with imipramine hydrochloride. At the time of discharge, Sept 7, his hemiplegia was spastic. He still manifested a dense motor aprosodia and a flat affect, even though his depression had totally resolved. Pathologic crying was no longer present. A CT scan, done on June 12, demonstrated a low-density lesion in the right basal ganglia, with extension to the frontoparietal subcortical white matter consistent with a right middle cerebral artery infarction (Fig 2, A).

Cases 1, 2, and 3 illustrate the phenomenon of motor aprosodia, which is characterized by aprosodic-agesural speech, poor prosodic repetition, and good prosodic comprehension. This is similar to motor (Broca's) aphasia, which is characterized by nonfluent speech, poor repetition, and good comprehension of propositional language.⁵ Furthermore, the supra-Sylvian infarctions in these cases (Fig 1 and 2, A) are in the distribution reported for lesions in the left hemisphere that cause Broca's aphasia.^{6,7} It is interesting that patient 1 had excellent recovery from his motor aprosody, whereas patients 2 and 3 did not. This may be related to the relative depth and size of the infarctions⁸; similar to the experience reported by Mohr,^{7,8} who found that small lesions in Broca's area produce rapidly ameliorating motor aphasia, while large supra-Sylvian lesions produce a persistent and often severe form of Broca's aphasia.

The disparity between recovery of spontaneous gesturing and spontaneous prosody in patient 2 suggests that these two aspects of language probably have different underlying anatomic bases (case 9).¹ This may be similar to the relationship of ideomotor apraxia to Broca's aphasia, where the former usually shows recovery over time while the latter may not.^{6,9} The overall relationship of spontaneous gesturing to aphasia and aprosody, however, is unclear. Patients with Broca's aphasia have been described as showing changes in gesturing that seem to reflect their underlying defect in propositional language,¹⁰ whereas patients with motor aprosodia appear to lose all spontaneous gesturing ability,¹ be it propositional or emotional. It may be that spontaneous (emotional) gesturing, in addition to being a dominant function of the right hemisphere, also serves as the vehicle for embedding the propositional components of gesturing contributed by the left hemisphere. Thus, the agesural state that results from right-hemisphere lesions may result

from the loss of emotional gesturing that concomitantly deranges propositional gesturing, while left-hemisphere lesions only effect the propositional components of gesturing. This hierarchical dependency of emotional to propositional gesturing may be similar to the hierarchical interaction of propositional speech to prosody. Since prosody, by definition, must be embedded onto the vehicle of propositional speech,¹¹ lesions that cause motor aphasia may produce changes in prosody, described under the rubrics of "hyperprosody" and "dysprosody" by Monrad-Khron,¹² whereas lesions that cause motor aprosodia produce a severe loss of prosody with little effect on propositional speech other than transient dysarthria. (For a more detailed discussion of the relationship of the different components of prosody to brain lesions and right-hemisphere damage see Ross and Mesulam.¹)

Sensory Aprosodia

CASE 4.—A 50-year-old right-handed man awoke with left-sided weakness and incoordination Dec 16, 1979, which precipitated admission to the Neurology Service at Parkland Memorial Hospital, Dallas. On examination he was awake, alert, and oriented, with normal recent and remote memory, calculation ability, proverb interpretation, and propositional language. He appeared to have a global aprosodia with flat monotone speech, poor prosodic repetition, and impaired prosodic comprehension. He tended to look to the right, and when drawing figures he neglected the left side. Facial sensation and strength were good, but he had a left-sided homonymous hemianopsia. A mildly spastic left-sided hemiparesis that affected the leg more than the arm and a global left-sided sensory impairment were present. The left-sided weakness rapidly resolved over a few hours.

Examination on Dec 17 showed him to have a normal mental status, with normal propositional language. Cranial nerves were normal except for a dense left-sided homonymous hemianopsia. There was no facial weakness or sensory loss. Motor weakness was not present on formal testing, but he held his left hand in a dystonic flexion posture and walked with a left-sided hemiparetic gait. Reflexes were slightly increased on the left, but Babinski's sign was absent. He had mild reduction in vibration and position sensations in his distal left extremities, with severe astereognosis in his left hand. Pin and temperature sense were normal.

The patient's speech exhibited a full range of prosodic features, with excellent variation. If anything, he tended to seem excessively happy despite his neurologic deficits. One had the feeling that his prosody was somewhat

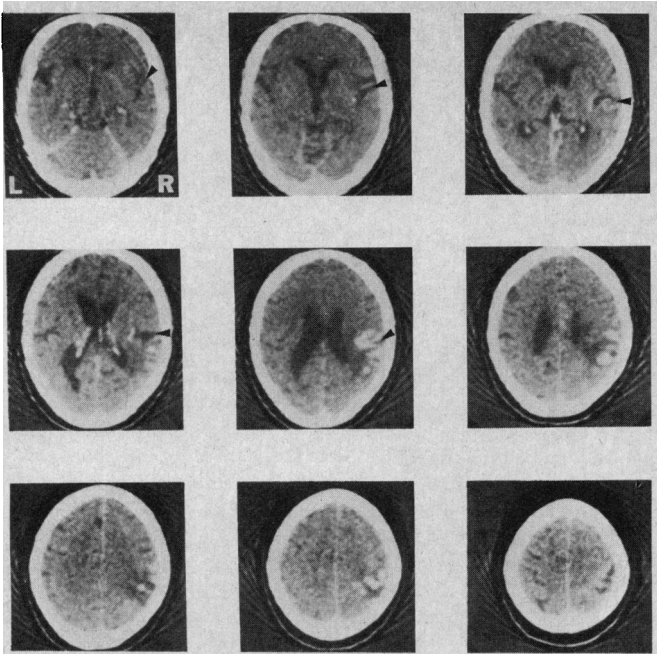


Fig 3.—Enhanced computed tomographic scan from patient 4. Infarction involves right parietal operculum and superoposterior temporal lobe. Right frontal operculum is spared. Arrowheads point into right Sylvian fissure, which divides frontal and, in higher cuts, parietal opercula from superior temporal lobe.

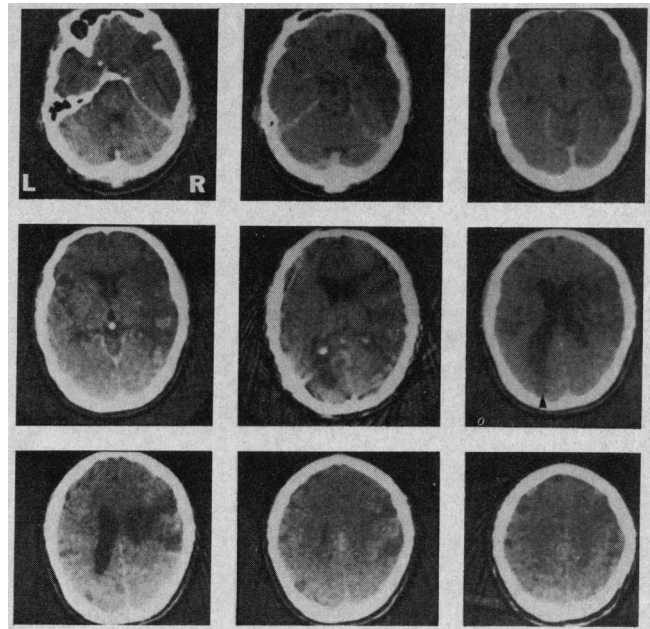


Fig 4.—Enhanced computed tomographic scan from patient 5. Infarction involves entire right middle cerebral artery distribution causing destruction of inferior and lateral frontal and parietal lobes, insula, and superior and middle temporal lobe. Left occipital horn is enlarged. Arrowhead points to possible old left occipital infarction or contusion.

euphoric and mismatched at times to the semantic content of his speech. He had well preserved and animated gesturing.

The patient's prosodic repetition was very poor despite normal spontaneous prosody. The best he could do was to raise or lower his voice to match the examiner's without insertion of other prosodic variations.

His prosodic comprehension was also extremely poor. He would persistently miss even the simplest emotional tones such as indifference, tearfulness, or anger. He tended to make his decisions on loudness of voice or call everything "happy." Once he identified a sad, tearful emotion as being "sad," but when asked if it was "a little sad, moderately sad, or very sad and tearful" he replied "Oh just a little sad."

The patient's comprehension of emotional gesturing was also severely impaired, similar to prosodic comprehension. However, when his prosodic comprehension was evaluated and he was allowed to view the examiner, his overall comprehension of affective language showed moderate gains but was still impaired.

The patient's neurologic deficits continued to improve during hospitalization, but the hemianopsia remained. At the time of discharge on Dec 29, he still manifested a sensory aprosodia, but his ability to comprehend emotional gestures was improved

but not normal. A CT scan, done on Dec 17, demonstrated a right posterosuperior temporal-lobe and posteroinferior parietal-lobe infarction (Figs 2, B, and 3).

Case 4 illustrates the phenomenon of sensory aprosodia, which is characterized by prosodic-gestural speech, poor prosodic repetition, and poor comprehension of prosody and emotional gesturing. This is similar to sensory (Wernicke's) aphasia, which is characterized by fluent speech, poor repetition, and poor comprehension of both written and spoken propositional language.⁵ Furthermore, the predominant posterior temporoinferior parietal infarction in patient 4 is the same distribution reported for lesions in the left hemisphere that cause Wernicke's aphasia.^{6,13} Although I am not absolutely certain that the patient was, at times, mismatching his prosody and emotional gesturing to the semantic content of speech, this uncertainty may just reflect inexperience in making such judgments in these kinds of patients. It should also be pointed out that if it were not for the patient's initial elementary neurologic deficits, his stroke may have easily gone undetected since his prosodic disorder only became apparent after formal examination. If the lesion was confined to the superoposterior temporal lobe, the only outward manifestation might have been a change in behavior due to mismatching of affect to semantics or

the patient misinterpreting the affective components of other peoples' behavior, causing him to respond inappropriately. If this were the case, then these patients or their families might seek psychiatric or psychological help even though the problem was primarily neurologic.

Global Aprosodia

CASE 5.—A 43-year-old right-handed man suffered the acute onset of a flaccid left-sided hemiplegia with sensory loss and was admitted to the Neurology Service at Parkland Memorial Hospital on Jan 1, 1979. He was lethargic and difficult to examine. He denied his neurologic deficits and had dysarthria, but propositional language was normal. A left-sided hemianopsia, left-sided lower facial weakness, loss of pin sensation over the left side of the face, and a flaccid left-sided hemiplegia with global sensory loss were apparent on examination. The lethargy and anosognosia resolved over the ensuing week, although he still manifested a mild dysarthria and persistent left-side hemianopsia.

Examination on Jan 31 showed the previously described, elementary neurologic findings. He had a flat affect but denied depression. Mental status and propositional language were otherwise normal.

His speech was flat and monotone without prosodic variation and without spontaneous gesturing. This was unchanged even when one discussed the extent, severity, and ultimate disability of his stroke.

The patient's prosodic repetition was extremely poor; everything was repeated aprosodically. He could not even vary the loudness of his voice to match the examiner's.

His prosodic comprehension and comprehension of emotional gesturing were severely compromised, although occasionally he would correctly identify an emotion, especially anger. It turned out, however, that he made this decision on loudness of voice. Thus, when given a statement in a very tearful but loud voice, he would consistently label it as being angry. Also, any vehemently made emotional gesture, regardless of its affective tone, was always interpreted as anger.

On reexamination Feb 2, the patient's prosodic comprehension and comprehension of emotional gesturing were improved but still abnormal. A CT scan done on Feb 6 demonstrated a large right middle cerebral-artery infarction that involved the frontal, parietal, anterior occipital, and superior and middle temporal lobes (Fig 2, C and 4).

Case 5 illustrates the phenomenon of global aprosodia, which is characterized by aprosodic-agematural speech, poor prosodic repetition, and poor comprehension of prosody and emotional gesturing. This is similar to global aphasia, which is characterized by nonfluent speech, poor repetition, and poor comprehension of both written and spoken propositional language.³ Furthermore, the large supra- and infra-Sylvian infarction is in the same distribution reported for lesions in the left hemisphere that cause global aphasia.⁶ The improvement in comprehension of the affective components of language in this patient is also consistent with Kertesz's observation⁶ in cases of global aphasia that comprehension is the most likely feature to improve, whereas nonfluency is least likely to improve over time.

Transcortical Motor Aprosodia

CASE 6.—A 70-year-old right-handed man was admitted to the Neurology Service at the Dallas Veterans Administration Hospital on Dec 5, 1978, because of a left-sided hemiparesis. Examination on Dec 7 showed him to be awake, alert, and oriented but apathetic in his responses. He did not deny his deficits but seemed unconcerned about them. Mental status and propositional language were otherwise normal. He had a mild left-sided lower facial weakness at rest and on volition, but a striking weakness when he laughed. There was a mild left-sided spastic hemiparesis most prominent in his lower extremity and proximal portion of his upper extremity with sparing of the hand. Sensation was normal

except for loss of graphesthesia and stereognosis in the left hand.

His speech was a soft monotone, completely devoid of emotion. He had little spontaneous gesturing, which created a flat affect. Occasionally he would laugh inappropriately. His prosodic repetition was excellent and strikingly better than his spontaneous prosody; his prosodic comprehension and comprehension of emotional gesturing were normal.

A CT scan, done on Dec 6, demonstrated an edematous enhancing lesion that involved the right frontal, anterior parietal, and anterior temporal lobes. Brain biopsy at craniotomy showed metastatic undifferentiated adenocarcinoma. Despite steroid therapy, radiation therapy, and chemotherapy, the patient became stuporous and died Jan 5, 1979.

CASE 7.—A 51-year-old right-handed woman was admitted to the Neurology Service at Parkland Memorial Hospital on Sept 18, 1979, after the acute onset of incontinence and a left-sided hemiparesis without sensory loss. Examination on Sept 22 showed her mental status and propositional language to be normal. She had good insight into her deficits. Urinary incontinence was present, characterized by an inability of the patient to hold her urine once she felt the urge to urinate. She had a moderately severe left-sided lower facial weakness and a left-sided eutonic hemiparesis, which spared the foot, distal part of the arm, and hand. No sensory loss or extinction phenomenon were observed.

Her speech was flat and monotone without prosodic variation. There was a dearth of gesturing, giving her a flat affect. She denied any symptoms of depression. Her prosodic repetition was flawless and in striking contrast to her aprosodic spontaneous speech; her prosodic comprehension and comprehension of emotional gesturing were excellent.

During hospitalization she regained continence and the left-sided hemiparesis improved. Examination March 5 showed only mild incoordination of the left leg with good strength, a mild left-sided lower facial weakness, most prominent during emotive movements, and total resolution of her transcortical motor aprosodia. A CT scan, done on Sept 19, demonstrated a small triangular lucency deep in the right hemisphere that involved the anterior limb of the internal capsule, head of the caudate nucleus, and putamen, without evidence of cortical involvement.

Cases 6 and 7 illustrate the phenomenon of transcortical motor aprosodia, which is characterized by aprosodic-agematural speech, good prosodic repetition, and good prosodic comprehension. This is similar to transcortical motor aphasia, which is characterized by nonfluent speech, good repetition,

and good comprehension of propositional language.³ Unfortunately, since the pathologic process in patient 6 was due to metastases, it is difficult, if not impossible, to make any statement about localization. This case is only important phenomenologically. Patient 7, on the other hand, is interesting because her lesion proved to be subcortical, although the distribution of her hemiparesis strongly suggested that she had right anterior cerebral-artery occlusion that produced infarction in the distribution of the recurrent artery of Heubner (accounting for the facial paralysis) and infarction of the medial frontal lobe (accounting for the leg monoplegia and incontinence).¹⁴ Unfortunately, a right medial frontal lesion was not shown by CT scan to account for the transcortical motor aprosodia, especially since transcortical motor aphasia has been reported after left medial frontal lesions.^{13,15} This case, however, may represent an aprosodia due to a right striatal lesion. The transient nature of her transcortical motor aprosodia is in keeping with some of the transcortical motor types of aphasias that have been reported following striatal lesions in the left hemisphere.^{3,17}

Transcortical Sensory Aprosodia

CASE 8.—A 76-year-old man with progressive recent-memory loss was admitted to the Neurology Service at Parkland Memorial Hospital on Feb 11, 1979, because of the acute onset of headache followed by unconsciousness and several generalized tonic-clonic seizures. On admission he was comatose and had left-sided hemiparesis. He received anticonvulsant medication and underwent emergency CT scanning. Within five hours he regained consciousness and had only a mild left-sided weakness.

Examination Dec 12, 1979, showed him to be awake, alert, and oriented, with a normal mental status except for moderate problems with recent memory. Propositional language and cranial nerves were normal; however, he had no useful vision because of dense bilateral cataracts. No motor weakness, reflex asymmetry, incoordination, or sensory deficits were noted.

His speech exhibited a full range of prosodic features, and he had animated gesturing. Mismatching of emotions to semantic content was not prominent, although he appeared somewhat euphoric in his responses regardless of semantic content. The patient's prosodic repetition was excellent but his prosodic comprehension was nonexistent. He totally failed to identify the emotive contents of speech and did not even use loudness of voice as a potential clue to help identify the correct emotion. His com-

prehension of emotional gesturing could not be tested because of his cataracts.

The prosodic deficits remained unchanged at discharge. Evaluation on Oct 15 showed a persistent transcortical sensory aprosodia without improvement. A CT scan done Feb 11, during hospitalization, demonstrated a large right-sided temporal intracerebral hematoma that spared the posterosuperior temporal lobe (Fig 2, D, and 5).

Case 8 illustrates the phenomenon of transcortical sensory aprosodia, which is characterized by prosodic-gestural speech, good prosodic repetition, and poor comprehension of affective language. This is similar to transcortical sensory aphasia, which is characterized by fluent speech, good repetition, and poor comprehension of propositional language.³ Although the lesion was an intracerebral hemorrhage, making localization less certain because of pressure effects, it is interesting that the hematoma did not involve the posterosuperior right temporal lobe, since this also seems to be characteristic of lesions in the left hemisphere that produce transcortical sensory aphasia.^{3,6}

Mixed Transcortical Aprosodia

CASE 9.—In May 1979, a 34-year-old right-handed woman was admitted to a hospital in Dallas because of subarachnoid hemorrhage. She underwent clipping of a left-sided supraclinoid berry aneurysm of the internal carotid artery. Postoperatively she sustained a left-sided hemiplegia with sensory loss and double incontinence. She was eventually transferred to the Physical Medicine and Rehabilitation Service at Parkland Memorial Hospital on Oct 12. Examination demonstrated a normal mental status except for a flat affect, with a rather indifferent attitude on the patient's part to her neurologic disabilities. She denied depression. Propositional language was unimpaired. Cranial nerves were normal except for mild left-sided visual-field extinction to double simultaneous stimulation and a mild left-sided lower facial weakness. She had a prominent left-sided spastic hemiplegia and a global left-sided hemicensory loss. The patient did poorly in the physical therapy program and was examined in consultation Oct 22 for evaluation of a questionable "dementia."

The routine neurologic examination was unchanged, but she did admit to being somewhat sad and hopeless, without suicidal ideation. She denied, however, any of the vegetative symptoms of depression, such as anorexia or insomnia, and she denied dysphoria.

Her speech was completely flat and monotone even when she talked about her neurologic deficits, which were severe enough to confine her to a

wheelchair and cause her to be catheter dependent. She had no spontaneous gesturing, which created a flat affect. The only emotion she demonstrated was several episodes of uncontrollable and inappropriate crying, during which she claimed she did not feel sad or know why she was crying.

The patient's prosodic repetition was good although not perfectly normal. She could easily modulate the loudness of her voice to that of the examiners and add a good deal of the finer aspects of prosody. In comparison to her spontaneous prosody, repetition was strikingly good although not completely normal. Her prosodic comprehension was clearly impaired, with most of her decisions made on loudness of voice. The patient's comprehension of emotional gesturing was as compromised as prosodic comprehension.

The patient did poorly in rehabilitation and was discharged. Evaluation on Jan 7, 1980, demonstrated no change in the findings from neurologic examination except for some improvement in prosodic comprehension. However, further historical details were obtained from the family. The patient, for many months, had been sleeping poorly, was anorexic (causing a 27-kg weight loss), and was "not the same person" because of excessive irritability. She cried and laughed inappropriately and uncontrollably at home. Because of this history, it was felt that she had depression, despite her denial of deep sadness and vegetative symptoms. She was treated with nortriptyline hydrochloride and had resolution of her vegetative symptoms, pathologic laughing and crying, and irritability. Her flat affect and aprosodic speech, however, remained totally unchanged. She continued to demonstrate improvement in prosodic repetition, prosodic comprehension, and comprehension of emotional gesturing. A CT scan done on Oct 26, 1979, during her hospitalization, showed a large right middle cerebral-artery infarction, which involved the frontal and parietal lobes with extension into the superior temporal lobe (Fig 2, E, and 6). There was also a small infarction in the left anteromedial frontal lobe.

Case 9 illustrates the phenomenon of mixed transcortical aprosodia which is characterized by aprosodic-gestural speech, good prosodic repetition, and poor comprehension of prosody and emotional gesturing. This is similar to mixed transcortical aphasia, which is characterized by non-fluent speech, good repetition, and poor comprehension of propositional language.^{3,18} From the lesion shown by CT scan, one would have expected the patient to have had global aprosodia. However, evaluation of her affective

components of language was first done almost six months after the stroke. Most likely, if she had been examined closer to her ictus, she would have demonstrated global aprosodia since prosodic repetition, although much better than the other components of affective language, was not normal. Furthermore, over the ensuing four months she began to show significant improvement in comprehension of prosody and spontaneous gesturing, transforming her mixed transcortical aprosodia into transcortical motor aprosodia. Again, this distributed recovery from prosodic deficits is consistent with the recovery observed by Kertesz⁶ in patients with global aphasia, especially when the lesion causes minimal damage to the (left) posterosuperior temporal lobe, as was the circumstance in the right-hemisphere lesion in patient 9.

Motor Aprosodia With Pure Prosodic Deafness

CASE 10.—A 67-year-old right-handed man awoke with left-sided hemiparesis on Jan 23, 1980, and was admitted to the Neurology Service at Parkland Memorial Hospital. He denied weakness in his left limbs but did admit to gait difficulty. He was alert, cooperative, and oriented but mildly inattentive. Immediate recall was only five numbers forward. Recent and remote memory, calculations, and interpretation of similarities and proverbs were normal. He had mild slurring of speech but no aphasic deficits. Cranial nerves were normal except for a mild left-sided lower facial weakness on volition. There was a moderate left-sided hemiparesis that affected the upper extremity to far greater extent than the lower extremity, with sparing of the distal leg and foot. Sensory functions were normal except for some decreased appreciation of pin and temperature in his left upper extremity.

Examination on Feb 2 showed left-sided spastic hemiparesis that involved his face, arm, hand, and proximal leg. No sensory loss was evident. The patient now had a normal mental status except for a flat affect. He denied being depressed.

His speech was flat and monotone without prosodic variation even when discussing his neurologic deficits and disability. Gesturing was very blunted.

The patient's prosodic repetition was exceedingly poor, and he could not even vary the loudness of his voice to reflect that of the examiner's. His prosodic comprehension was also exceedingly poor. He could not even use loudness of voice as a cue to identify the projected affective tone. The patient's comprehension of emotional gesturing in distinct contrast to pros-

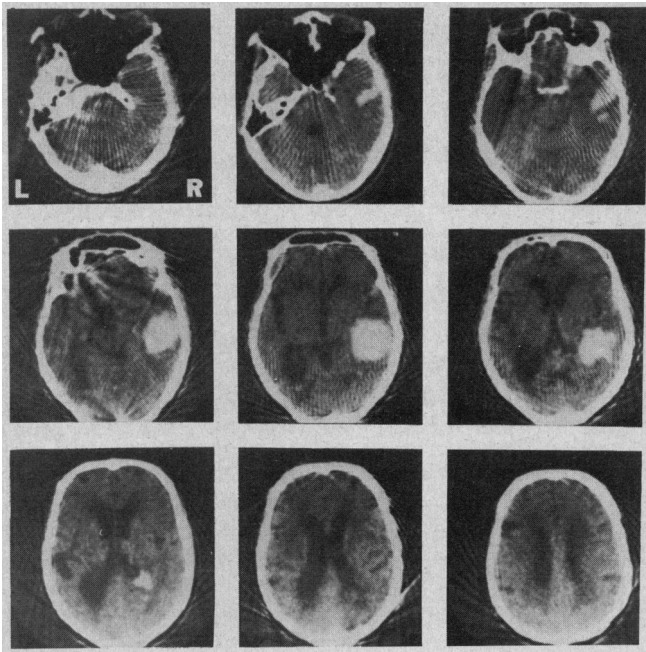


Fig 5.—Top left, Computed tomographic scan from patient 8. Intracerebral hematoma involves right anterior, middle, and inferior temporal lobe, with deep extension into right occipital horn. Superoposterior temporal lobe is spared. There is minimal edema and displacement of brain. Cortical atrophy and hydrocephalus ex vacuo are present.

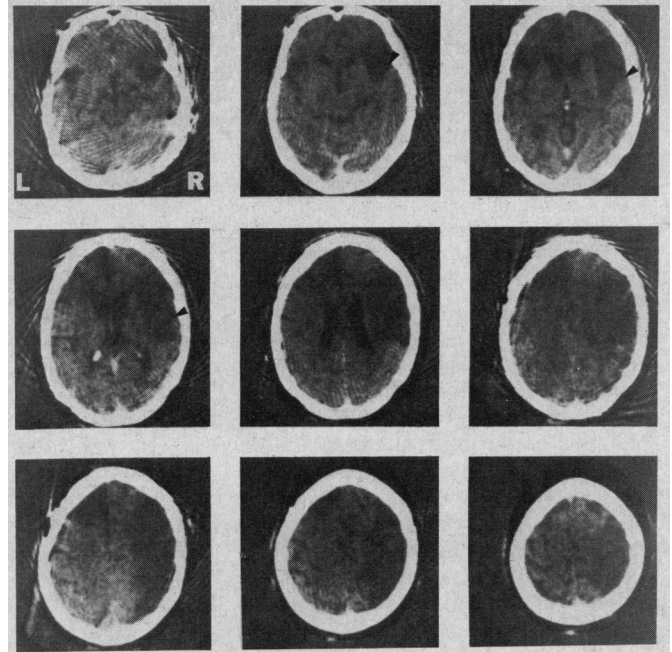


Fig 6.—Top right, Computed tomographic scan from patient 9. Infarction involves right inferior and lateral frontal and parietal lobes and part of right superoposterior temporal lobe. There is also infarction of left anteromedial frontal lobe. Arrowheads point to right Sylvian fissure, which separates frontal and parietal opercula from superior temporal lobe.

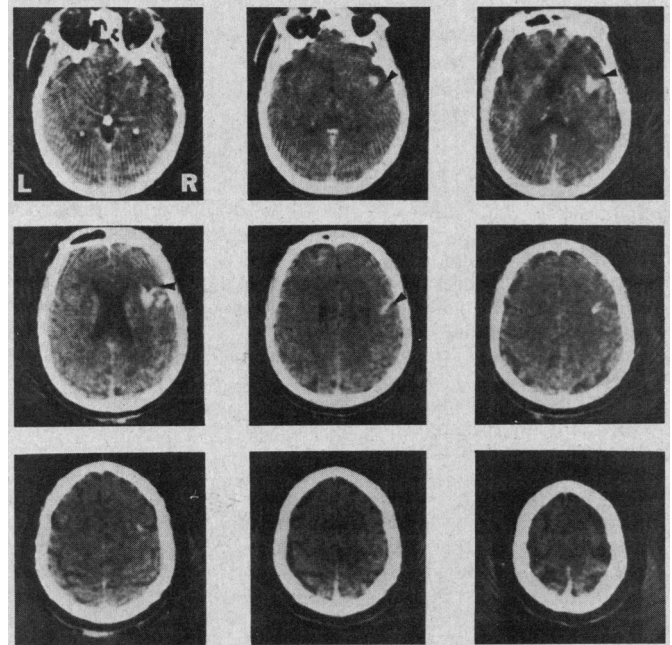


Fig 7.—Bottom right, Enhanced computed tomographic scan from patient 10. Infarction involves right frontal operculum, insula, and superior, midanterior, temporal lobe. Parietal operculum and superoposterior temporal lobe are spared. Arrowheads point to right Sylvian fissure, which separates frontal and parietal opercula from superior temporal lobe.

odic comprehension, was flawless. In fact, if prosodic comprehension was tested so that he could see the examiner, he only manifested minimal difficulties!

Just prior to discharge, on Feb 15, the patient was reexamined. His elementary neurologic findings were unchanged. Prosodic comprehension, however, was significantly better but not completely normal. A CT scan, done on Feb 1, demonstrated a lesion that involved the right frontal operculum, anterior insula, and superior-midtemporal lobe, with sparing of the superoposterior temporal and inferior parietal lobes (Fig 2, F and 7).

Case 10 illustrates the phenomenon

of motor aprosodia coupled with pure prosodic deafness. This particular combination of deficits—aprosodic-agerstural speech, poor prosodic repetition, poor prosodic comprehension, and good comprehension of emotional gesturing—is similar to occasionally described patients who have global aphasia without alexia.¹⁹ The right frontal opercular lesion easily accounted for the aprosodic spontaneous speech and loss of prosodic repetition. The comprehension deficit, however, is the intriguing feature of case 10, since it only involved auditory processing of affective language. This implies that the visual connections to

the right superoposterior temporal lobe, which appears to be functionally homologous to Wernicke's area on the left,⁴ were preserved so that comprehension of emotional gesturing could be carried out. The lesion in the right superior-midtemporal lobe probably injured the right primary auditory cortex and interrupted the callosal connections from the left auditory cortex, isolating the right superoposterior temporal lobe from auditory inputs, thus accounting for the loss of prosodic comprehension (pure prosodic deafness). This explanation is the same one used to account for pure word deafness (loss of auditory com-

prehension of propositional language with preserved reading, writing, naming, propositional speech, and nonverbal audition) following a unilateral lesion of the left middle temporal lobe that spares Wernicke's area.^{5,20} Furthermore, it has been postulated, but not proven, that global aphasia without alexia might result from a lesion that causes pure word deafness in combination with a lesion that causes Broca's aphasia in the left hemisphere.¹⁹

COMMENT

The patients described in this article help to further unravel the functional-anatomic organization of the affective components of language in the right hemisphere.¹⁻⁴ Seven of ten patients had lesions in the right hemisphere, with accompanying disorders of affective language corresponding exactly to the traditional classification and localization given for motor, sensory, global, and transcortical sensory aphasia and pure word deafness (Fig 2 and Table). In addition, the phenomena of transcortical motor aprosodia and mixed transcortical aprosodia have been observed. To complete and substantiate the analogy of the aprosodias to the aphasias, however, patients with "conduction" and "anomic" varieties of aprosodia will need to be identified (Table) and further validating case reports will need to be published.

Two further points should be made about the behavior changes that accompany right-hemisphere lesions. In the aprosodias associated with flat affect, coarse emotional behavior may be preserved, since a number of patients retained the ability to laugh and cry (cases 2, 3, and 9). For the most part, this ability was clearly "pathologic" because the laughing and crying were usually inappropriate, uncontrollable, and had an all-or-nothing quality.²¹ The most striking pathologic laughing and crying occurred in the two patients (cases 3 and 9) who were ultimately found to have major depressive disorders. Interestingly, when these patients' depression was treated, their pathologic laughing and crying dissipated. This strongly suggests that in patients with prominent pathologic laughing and crying, following unilateral right-hemisphere damage, the diagnosis of depression should be suspected and vigorously pursued.²²

The last point concerns flat affect. One should not confuse a flat affect following right-hemisphere damage to be necessarily indicative of depres-

sion or unconcern. Patients who are depressed have a depressive affect; patients with a flat affect, following right hemisphere damage, have little or no affect whether depressed or not (cases 3 and 9), happy, sad, angry, etc. Thus, one should be very cautious when psychiatrically examining these patients, since their affect may not reflect their mood. Some patients with right-hemisphere lesions who appear to have implicit denial or unconcern for their deficits are very concerned about them but unable to convey this concern through prosody or emotional gesturing. In these particular cases, strict attention should be paid to the patient's propositional description of his mood and inner feelings (case 3), disregarding the flat affect. On the other hand, if the right-hemisphere lesion is large and/or involves posterior structures, such as in patient 9, the propositional responses to questions that pertain to mood can be very misleading, since the language areas of the left hemisphere may no longer have direct access to emotional processes in the right hemisphere. Thus, the patient may display behavioral manifestations consistent with an emotional disorder (in this instance, the vegetative signs of depression) without an appropriate verbal-cognitive set. This is similar to the behavior exhibited by "split brain" patients, as reported by Gazzaniga and LeDoux,²³ when tasks are given to the right hemisphere that require a left-hand response. If a verbal explanation of the right-hemisphere behavior is requested from the left hemisphere, it often bears little relation to the actual task and may be very misleading as to the true state of affairs. (For further elucidation of the often disparate and vexing relationships between affect, mood, pathologic laughing and crying, and depression in brain-damaged patients, see Ross and Rush.²⁴)

During the last five months (after this report was submitted for publication), I have encountered four cases of motor aprosodia, two cases of sensory aprosodia, and two cases of global aprosodia secondary to cerebral vascular infarctions of the right hemisphere. All the patients were right handed and none had aphasic deficits. The locations of the lesions, determined by CT, causing the various aprosodias correlated without exception to the functional-anatomic data presented in this report. It has been my recent experience, as attending neurologist, that the aprosodias are as commonly encountered on the clinical services as are the aphasias.

The neurology house staff referred patients to me; Stephanie Ross, MS, reviewed the manuscript; and Denise Wernet patiently typed the manuscript.

References

- Ross ED, Mesulam M-M: Dominant language functions of the right hemisphere: Prosody and emotional gesturing. *Arch Neurol* 1979; 36:144-148.
- Heilman KM, Scholes R, Watson RT: Auditory affective agnosia: Disturbed comprehension of affective speech. *J Neurol Neurosurg Psychiatry* 1975;38:69-72.
- Tucker DM, Watson RT, Heilman KM: Discrimination and evocation of affectively intoned speech in patients with right parietal disease. *Neurology* 1977;27:947-950.
- Larsen B, Skinhøj E, Lassen NA: Variations in regional cortical blood flow in the right and left hemispheres during automatic speech. *Brain* 1978;101:193-209.
- Benson DF: *Aphasia, Alexia, and Agraphia*. New York, Churchill Livingstone, 1979.
- Kertesz A: *Aphasia and Associated Disorders*. New York, Grune & Stratton Inc, 1979.
- Mohr JP: Broca's area and Broca's aphasia, in Whitaker H, Whitaker HA (eds): *Studies in Neurolinguistics*. New York, Academic Press Inc, 1976, vol 1, pp 201-235.
- Mohr JP: Rapid amelioration of motor aphasia. *Arch Neurol* 1973;28:77-82.
- Geschwind N: The apraxias: Neural mechanisms of disorders of learned movement. *Am Sci* 1975;63:188-195.
- Cicone M, Wapner W, Foldi N, et al: The relation between gesture and language in aphasic communication. *Brain Lang* 1979;3:324-349.
- Fry DB: Prosodic phenomena, in Malmberg B (ed): *Manual of Phonetics*. New York, American Elsevier Publishing Co, 1974, pp 365-410.
- Monrad-Khron G: The third element of speech: Prosody and its disorders, in Halpern L (ed): *Problems of Dynamic Neurology*. Jerusalem, Hebrew University Press, 1963, pp 101-117.
- Kertesz A, Benson DF: Neologistic jargon: A clinicopathological study. *Cortex* 1970;6:362-386.
- Critchley M: The anterior cerebral artery and its syndromes. *Brain* 1930;68:120-165.
- Rubens AB: Transcortical motor aphasia, in Whitaker H, Whitaker HA (eds): *Studies in Neurolinguistics*. New York, Academic Press Inc, 1976, vol 1, pp 293-303.
- Alexander MP, Schmitt MA: The aphasia syndrome of stroke in the left anterior cerebral artery territory. *Arch Neurol* 1980;37:97-100.
- Alexander MP, LoVerme SR: Aphasia after left hemispheric intracerebral hemorrhage. *Neurology* 1980;30:1193-1202.
- Ross ED: Left medial parietal lobe and receptive language functions: Mixed transcortical aphasia after left anterior cerebral artery infarction. *Neurology* 1980;30:144-151.
- Heilman KM, Rothi L, Campanella D, et al: Wernicke's and global aphasia without alexia. *Arch Neurol* 1979;36:129-133.
- Gazzaniga MS, Glass AV, Sarno MT, et al: Pure word deafness and hemispheric dynamics: A case history. *Cortex* 1973;9:136-143.
- Wilson SAR: Pathological laughing and crying. *J Neurol Psychopathol* 1924;4:299-333.
- Ross ED, Rush AJ: Diagnostic issues and neuroanatomical correlates of depression in brain-damaged patients: Implications for a neurology of depression. *Arch Gen Psychiatry*, to be published.
- Gazzaniga MS, LeDoux JE: *The Integrated Mind*. New York, Plenum Press, 1978, chap 5, 6, and 7.
- Matsui T, Hirano A: *An Atlas for the Human Brain for Computerized Tomography*. Tokyo, Igaku-Shoin Ltd, 1978.