

A different type of blocking (Fig 1, right) was seen eight and nine months after onset. Here, a single late component was present in an on-off fashion for 30 or more consecutive impulses. An analogous finding has been reported at regions of low conduction safety in single primary afferent fibers of the cat, with impulses undergoing alternating periods of block and conduction [1]. This raises the possibility that following the attack of myoglobinuria, a recently myelinated sprout acted as a region of low conduction safety, thereby giving rise to on-off blocking. Further studies may help resolve this point.

I am grateful to Drs M. J. Aminoff, H. L. Fields, and D. A. Riley, of the University of California, San Francisco, for review of the manuscript and valuable suggestions.

References

1. Chung S-H, Raymond SA, Lettvin JY: Multiple meanings in single visual units. *Brain Behav Evol* 3:72-101, 1970
2. Dennis MJ: Physiological properties of junctions between nerve and muscle developing during salamander limb regeneration. *J Physiol (Lond)* 244:683-702, 1975
3. Desmedt JE, Borenstein S: Regeneration in Duchenne muscular dystrophy. Electromyographic evidence. *Arch Neurol* 33:642-650, 1976
4. Edds MV: Collateral nerve regeneration. *Q Rev Biol* 28:260-276, 1953
5. Hall-Craggs ECB: Hyperinnervation of muscle following treatment with bupivacaine. *Anat Rec* 184:420-421, 1976
6. Stålberg E, Thiele B: Transmission block in terminal nerve twigs: a single fibre electromyographic finding in man. *J Neurol Neurosurg Psychiatry* 35:52-59, 1972
7. Trojaborg W: Prolonged conduction block with axonal degeneration. An electrophysiological study. *J Neurol Neurosurg Psychiatry* 40:50-57, 1977

Blue Rubber Bleb Nevus Syndrome with CNS Involvement and Thrombosis of a Vein of Galen Malformation

E. A. Waybright, MD, J. B. Selhorst, MD,
W. I. Rosenblum, MD, and C. G. Suter, MD

A patient is described with the dermatological features of blue rubber bleb nevus syndrome (BRBNS), focal seizures, and lateralized neurological signs. CAT scan demonstrated a nonenhanced density in the region of the vein of Galen. Neuropathological examination showed that this density was a clot within a vein of Galen malformation. Hemangiomas that grossly resembled the skin lesions of BRBNS were seen on the cerebral surface. Many of these hemangiomas were thrombosed and overlay patchy zones of infarction. Numerous vascular malformations of varying histological types were also found within the brain and systemic organs.

Bluish, compressible, often raised hemangiomas of the skin should alert physicians to the BRBNS and the potential for vascular malformations to occur within the brain as well as systemic organs. Diagnosis of BRBNS involving the brain may assist in interpretation of radiographic findings. The tendency of these malformations to thrombose may account for focal neurological deficits.

Waybright EA, Selhorst JB, Rosenblum WI, et al:
Blue rubber bleb nevus syndrome with CNS
involvement and thrombosis of a vein of Galen
malformation. *Ann Neurol* 3:464-467, 1978

In 1958 Bean [1] described a disorder with distinctive hemangiomas of the skin and gastrointestinal tract. He termed the condition the blue rubber bleb nevus syndrome (BRBNS). We wish to draw attention to brain involvement in BRBNS by describing a patient who presented with focal seizures, lateralized neurological signs, and bluish hemangiomas of the skin. In this patient computerized tomography (CAT scan) revealed a high density in the region of the vein of Galen. The nature of this high density and the cause of the neurological signs were not fully evident until pathological examination.

From the Departments of Neurology and Pathology, Medical College of Virginia, Richmond, VA.

Accepted for publication Dec 13, 1977.

Address reprint requests to Dr Selhorst, Box 698, Medical College of Virginia, Richmond, VA 23298.

Four months before admission a 19-year-old man described a brief clonic twitch of his left arm. Subsequently he complained of several severe, throbbing bifrontal headaches. One such headache lasted three days. Two clonic seizures of the left arm prompted admission. Careful review of the family history did not reveal similar skin lesions in any member.

The patient was 1.52 m tall and weighed 91.9 kg. Blood pressure was 154/104. His skin had scattered, spiderlike telangiectasias and blue, bleblike, rubbery hemangiomas of the left upper eyelid, lower lip (Fig 1), buccal mucosa, and palm. These had been present from birth. General physical examination was unremarkable. Neurological examination disclosed total left homonymous hemianopia, broad-based gait, and slightly decreased strength in the left arm. Astereognosis and extinction to double simultaneous tactile stimuli were found in the left hand. Ocular motility was full. There were no abnormal eye movements. Fundoscopic examination after application of a mydriatic agent was unremarkable.

Laboratory data revealed an increased red cell mass (hemoglobin, 18.7 gm/dl, hematocrit, 54.5%) with low to normal platelet count and normal white cell count. Lactic dehydrogenase and alkaline phosphatase were elevated. Other liver function indicators were normal after transient mild elevations. Urinalysis showed proteinuria and slightly positive reaction for blood without microscopic hematuria. An electrocardiogram recorded first-degree atrioventricular block and right ventricular hypertrophy. With the patient breathing 100% oxygen, a right-to-left pulmonary shunt of 13% was found.

Roentgenograms of the chest, hand, skull, and long bones were normal. An electroencephalogram showed spike discharges and theta rhythm in the right posterior hemisphere. CAT scan revealed a small, high density in the posterior midline that was not enhanced after injection of contrast material. Prominent basal veins and a straight sinus were seen (Fig 2A). An angiogram of the right carotid and left vertebral arteries showed dilated basal veins and superficial

draining veins over the right hemispheric cortex. The thalamostriate and internal cerebral veins and the vein of Galen were not visualized. Using subtraction techniques neither arterial shunts, hypervascular stains, nor early-filling veins were identified about the vein of Galen or the cerebral surface.

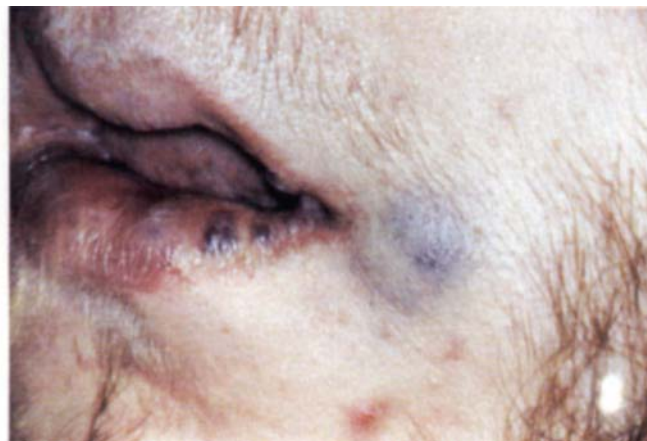
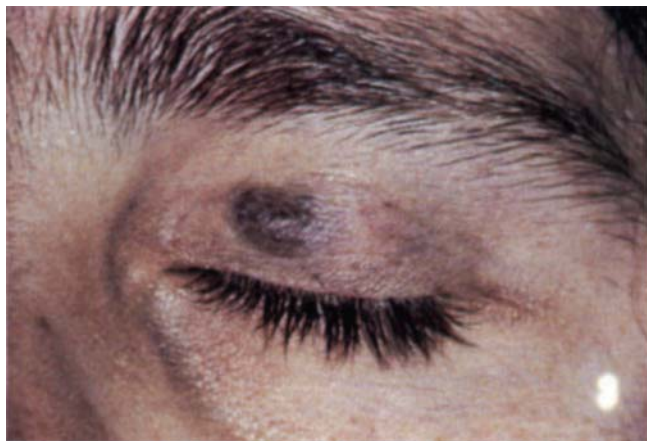After consultation a clinical diagnosis of BRBNS of skin and brain was made. Phenytoin therapy was begun. Several phlebotomies were performed to ameliorate secondary polycythemia. Three days after discharge the patient died at home in his sleep.

Postmortem Findings

The patient had multiple vascular malformations of the skin, esophagus, right atrium, pericardium, and parietal pleura. These malformations were variously capillary telangiectasias, cavernous and venous hemangiomas, and arteriovenous malformations. Abnormal pulmonary vessels were also seen. The cause of death was not apparent.

Numerous bluish, ectatic vessels up to 1.0 cm in diameter were scattered over the posterior half of the right hemispheric surface (Fig 3). These hemangiomas grossly resembled the skin lesions on the face. Histological examination showed these ectatic vessels to be large, dilated channels with walls of varying thickness. Many of the channels were thrombosed. Multiple tortuous arteries were present adjacent to these walls. In one section a small artery entered the dilated vein. Moderate-sized venous channels were also seen deep in sulci. Along the surfaces of the right posterior parietal and occipital lobes, underlying the thrombosed hemangiomas, were multiple softened, yellowish areas. These thin, discolored patches consisted of necrotic gray and white matter. In the region of the vein of Galen was a 2.0 cm bluish mass that was fed by the internal cerebral veins (Fig 2B). This mass was a venous aneurysm which contained a large thrombus. Several small arteries were found adjacent to it. Capillary telangiectasias and cavernous hemangiomas were also found near the surface of the right cerebrum and cerebellum.

Fig 1. Raised bluish hemangiomas with a rubbery consistency are seen on the eyelid, lip, and angle of the mouth. Spontaneous perspiration occurred on the upper lip.



Discussion

Cavernous hemangiomas, blood sacs with a rubbery consistency and bluish color, and irregular blue marks

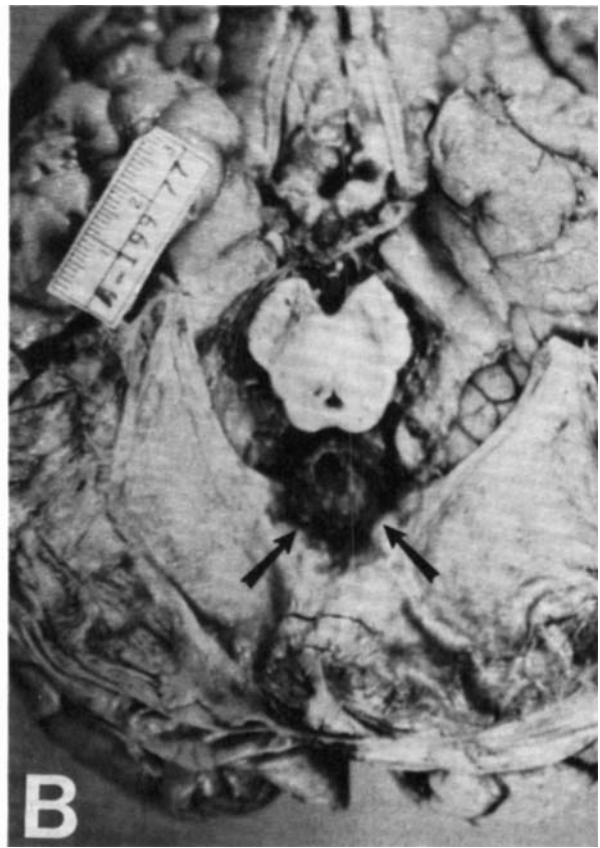
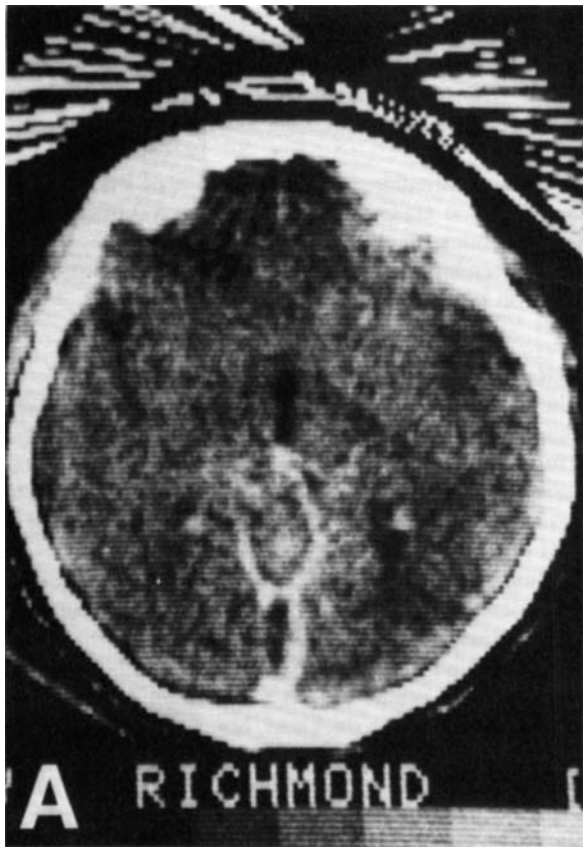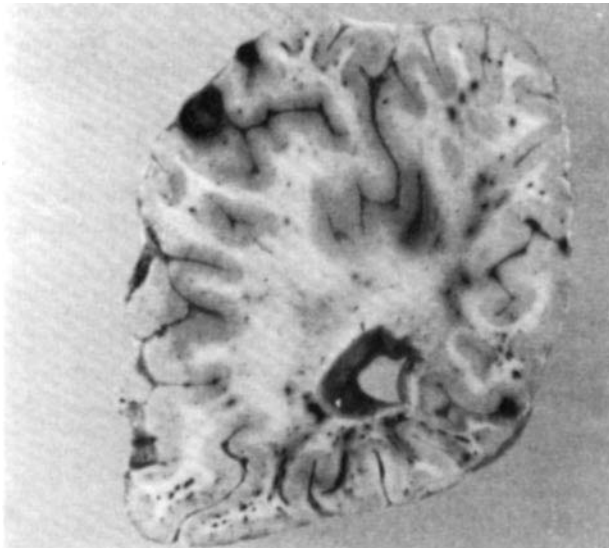
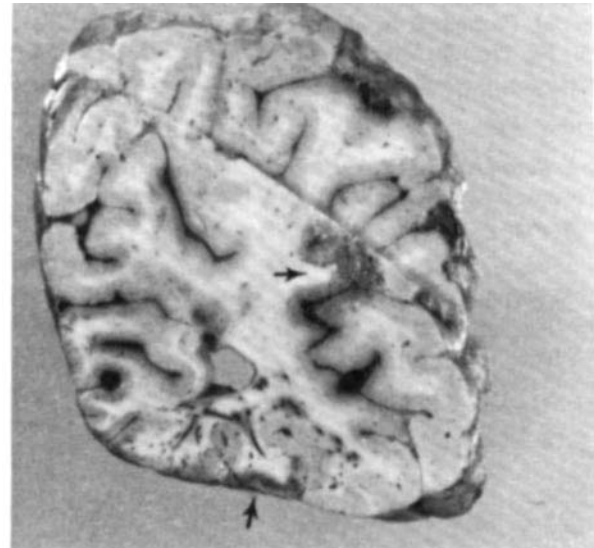


Fig 2. (A) CAT scan with contrast shows venous drainage into the straight sinus and around a small midline density that was not enhanced after injection of contrast. (B) This density was a clot within a 2.0 cm, bluish bleb in the region of the vein of Galen (arrows).



A



B

Fig 3. Anterior surface (A) and posterior surface (B) of serial sections from the posterior right hemisphere show several large and small thrombosed malformations on the cerebral surface and in the sulci. Multiple dilated vessels are seen within brain parenchyma. Arrows indicate softened, discolored margins of several gyri.

were all described by Bean as part of BRBNS [1]. These lesions are often, but not invariably, elevated. Occasionally pain or hyperhidrosis further distinguishes the skin lesion [4]. Histological section shows large and small cavernous spaces lined with endothelium and separated by varying amounts of collagenous and fibrous tissues [1, 2, 4]. The most frequent serious complication of BRBNS is hemorrhage from gastrointestinal tract hemangiomas [2]. Hemangiomas in other abdominal organs and the lungs have also been reported. In three families BRBNS has been reported to be genetically transmitted [2, 8].

Because of scattered telangiectasias and pulmonary shunting, a diagnosis of Osler-Weber-Rendu disease or hereditary hemorrhagic telangiectasia (HHT) was considered in our patient during his hospitalization. This diagnosis was discarded because of the presence of skin lesions more typical for BRBNS and absence of the inherited flat, reddish pinhead angiomas of HHT. Furthermore, our review of the neuropathology of HHT failed to disclose vascular lesions within the brain that grossly resembled those in our patient.

Three past reports of multiple hemangiomatosis involving brain might now be recognized as manifesting dermatological features of BRBNS. Jaffe [7] described a patient with skin, thyroid, lung, intestine, spleen, cervical anterior nerve root, and asymptomatic leptomeningeal hemangiomas which resembled those of our patient. Wood and associates [10] reported similar coincidental hemangiomas of brain, skin, liver, spleen, and kidney in an elderly woman with a cerebral infarction. Burke et al [3] found multiple hemangiomas of the brain in an infant with seizures, hydrocephalus, and many large, protuberant skin hemangiomas. To our knowledge this is the first patient described with focal neurological signs accompanying the now established BRBNS.

Thrombosis in the malformations of the cerebral surface and vein of Galen in our patient were remarkable neuropathological findings. Thrombosis in the skin hemangiomas of BRBNS has been described [4]. Thus, discovery of thrombi in similar appearing vascular malformations of the brain is not unex-

pected. Polycythemia possibly contributed further to thrombus formation. The composite of multiple patchy zones of necrotic cerebrum underlying the thrombosed malformations on the cerebral surface accounted for the left homonymous hemianopia and spike discharges.

Spontaneous thrombosis of an arteriovenous malformation is rare. There are only 2 reports of complete thrombosis of a vein of Galen aneurysm [5, 9]. In both reports the histological description is incomplete. A thrombosed cavernous hemangioma in the pineal region of a patient without skin lesions was recently described. That report is relevant to our patient because of a remarkably similar CAT scan [6]. In each patient with a thrombosed vein of Galen aneurysm, as in our own, angiography failed to reveal internal cerebral veins or the vein of Galen. Recognition of the vascular lesions of BRBNS, the possible association with vascular malformations in the brain, and the tendency of the latter to thrombose should assist proper interpretation of similar radiographic findings in the future.

References

1. Bean WB: Vascular Spiders and Related Lesions of the Skin. Springfield, IL, Charles C Thomas, 1958, pp 178-185
2. Berlyne GM, Berlyne N: Anemia due to "blue-rubber-bleb" nevus disease. *Lancet* 2:1275-1277, 1960
3. Burke EC, Winkelmann RK, Strickland MK: Disseminated hemangiomatosis. *Am J Dis Child* 108:418-424, 1964
4. Fretzin DF, Potter B: Blue rubber bleb nevus. *Arch Intern Med* 116:924-929, 1965
5. Heinz ER, Schwartz JF, Sears RA: Thrombosis in the vein of Galen malformation. *Br J Radiol* 41:424-428, 1968
6. Hubschmann O, Kasoff S, Doniger D: Cavernous hemangioma in the pineal region. *Surg Neurol* 6:349-351, 1976
7. Jaffe RH: Multiple hemangiomas of the skin and of the internal organs. *Arch Pathol* 7:44-54, 1929
8. Walshe MM, Evans CO, Warin RP: Blue rubber bleb nevus. *Br Med J* 2:931-932, 1966
9. Weir BKA, Allen PBR, Miller JDR: Excision of thrombosed vein of Galen aneurysm in an infant. *J Neurosurg* 29:619-622, 1968
10. Wood MW, White RJ, Kernohan JW: Cavernous hemangiomatosis involving the brain, spinal cord, heart, skin, and kidney. *Proc Mayo Clin* 32:249-254, 1957