

Neurosurgical Clinic of the University of Pavia and Centre for the Study and Medical and Surgical Treatment of Cerebrovascular Diseases, Pavia<sup>1</sup>; Paediatric Clinic of the University of Pavia<sup>2</sup> and Department of Morbid Anatomy and Histopathology, State University of Milan<sup>3</sup>, Italy

## Saccular Aneurysm of Infancy and Early Childhood

### Report of a Case

By

P. Paoletti<sup>1</sup>, S. Pezzotta<sup>1</sup>, M. Scotta<sup>2</sup>, and L. Mosca<sup>3</sup>

With 4 Figures

#### Summary

A case of intracranial saccular aneurysm with intracerebral haematoma occurring in early childhood and presenting with sudden loss of consciousness and right hemiparesis is reported. The aneurysm was located in the opercular portion of the left middle cerebral artery. Surgery, besides removing the intracerebral haematoma, involved clipping and complete removal of the aneurysmal sac. The child made an uneventful recovery, and he is completely safe after 40 months. Microscopic examination of the lesion shows disruption of the normal sequence of the original layers, with widespread inflammatory cells.

*Keywords:* Cerebral aneurysm; infancy; congenital anomaly.

#### Introduction

Intracranial arterial aneurysms are rare in childhood. They accounted for 17 of the 1,125 intracranial aneurysms reported by McDonald and Korb<sup>29</sup>. Laitinen<sup>22</sup> observed that 1.3% of the aneurysms studied were in paediatric patients. Matson<sup>28</sup> reported a series of 15 cases varying from 1 to 17 years in age, while Cambria *et al.*<sup>9</sup> described a case of congenital saccular aneurysm in a four-year-old child. Locksley<sup>27</sup> had one case in a group of 2,627 patients, while Breschi *et al.*<sup>8</sup>, Thompson and Pribram<sup>37</sup>, Arai *et al.*<sup>4</sup>, Shucart and Wolpert<sup>34</sup>, Becker *et al.*<sup>5</sup>, and Milhorat<sup>30</sup> added one case each. Grode *et al.*<sup>17</sup> described two cases of middle cerebral artery aneurysms in young babies, while Bolander *et al.*<sup>6</sup> described the death of an 11-month-old patient due to the rupture of an anterior com-

municating artery aneurysm. Finally Gerosa *et al.*<sup>16</sup> in 1980 reported 15 cases of cerebral artery aneurysms in children between 8 and 15 years of age.

### Case Report

A 34-month-old boy was admitted to the Paediatric Clinic of the University of Pavia on 6 October 1977. He presented with a deficit of the left third cranial nerve and right hemiparesis. He had been drowsy for two days

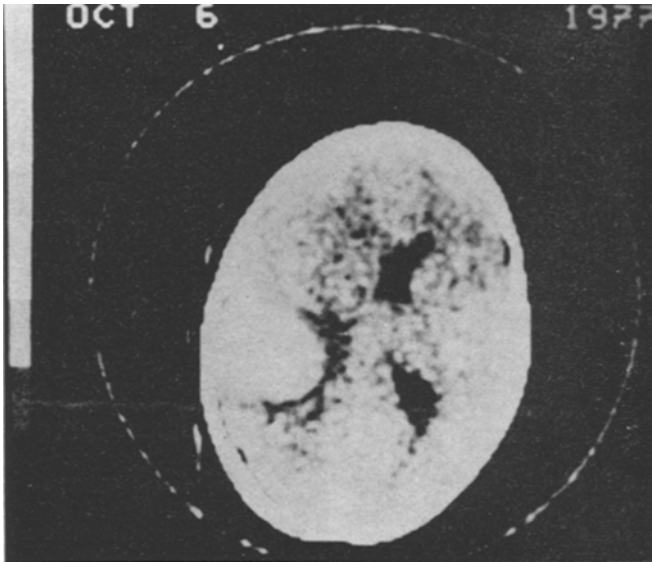


Fig. 1. CT scan (6 October 1977) showing a left insulo-parietal haematoma

prior to admission. An examination of the fundus oculi revealed that the left disc had blurred edges. CT scan was done immediately, and showed a left insulo-parietal haematoma (Fig. 1). A lumbar puncture showed clear CSF with no cells and normal protein and sugar values. Left carotid angiography showed an aneurysm of the opercular portion of the left middle cerebral artery, with a haematoma in the left insular region (Fig. 2). The boy was treated with mannitol, dexamethasone, and tranexamic acid intravenously, and fourteen days later a left temporo-parietal craniotomy was performed. A partially coagulated 40 ml haematoma was removed. The aneurysmal sac, which appeared very large and partially thrombosed, was clipped at the neck and removed. The boy was awake after 24 hours of intensive care, but a monoparesis of the right upper limb remained for 15 days. A CT scan was performed 45 days after surgery, and showed a slight ventricular dilatation with no periventricular hypodensity (Fig. 3). Other CT scans were done 4 and 12 months later, and they showed the same ventricular dilatation. The clinical situation is continuously improving, and the patient's neurological and psychic conditions 40 months after the operation are excellent.

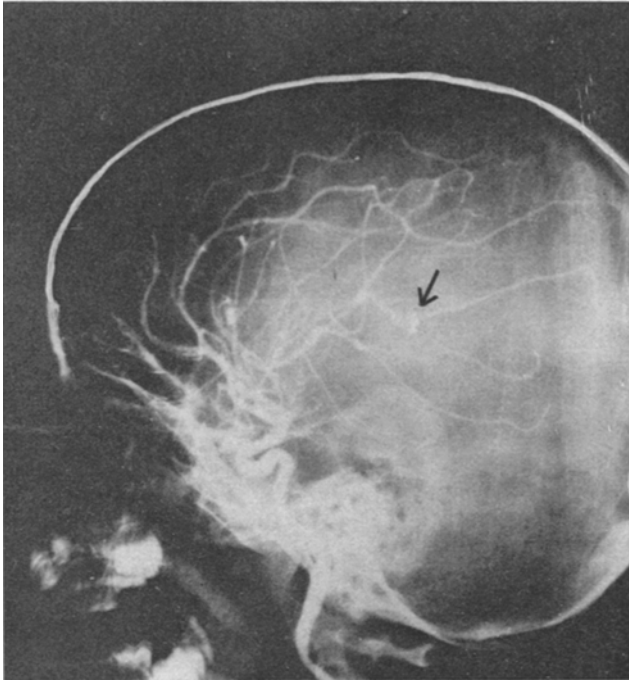


Fig. 2. Left carotid angiogram (lateral view) showing an aneurysm in the opercular portion of the left middle cerebral artery

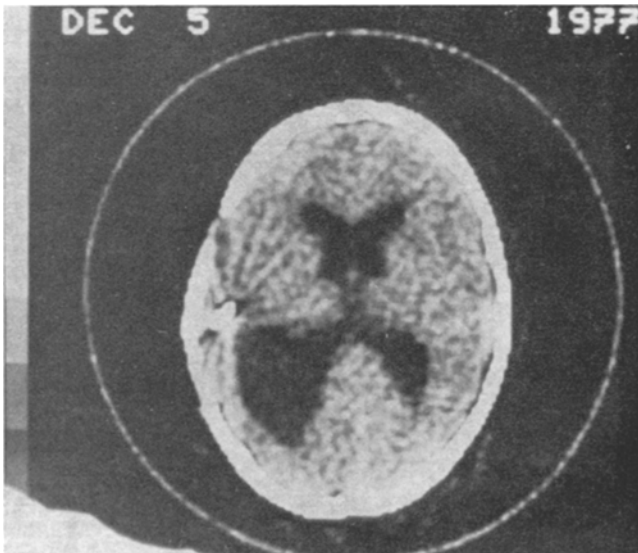
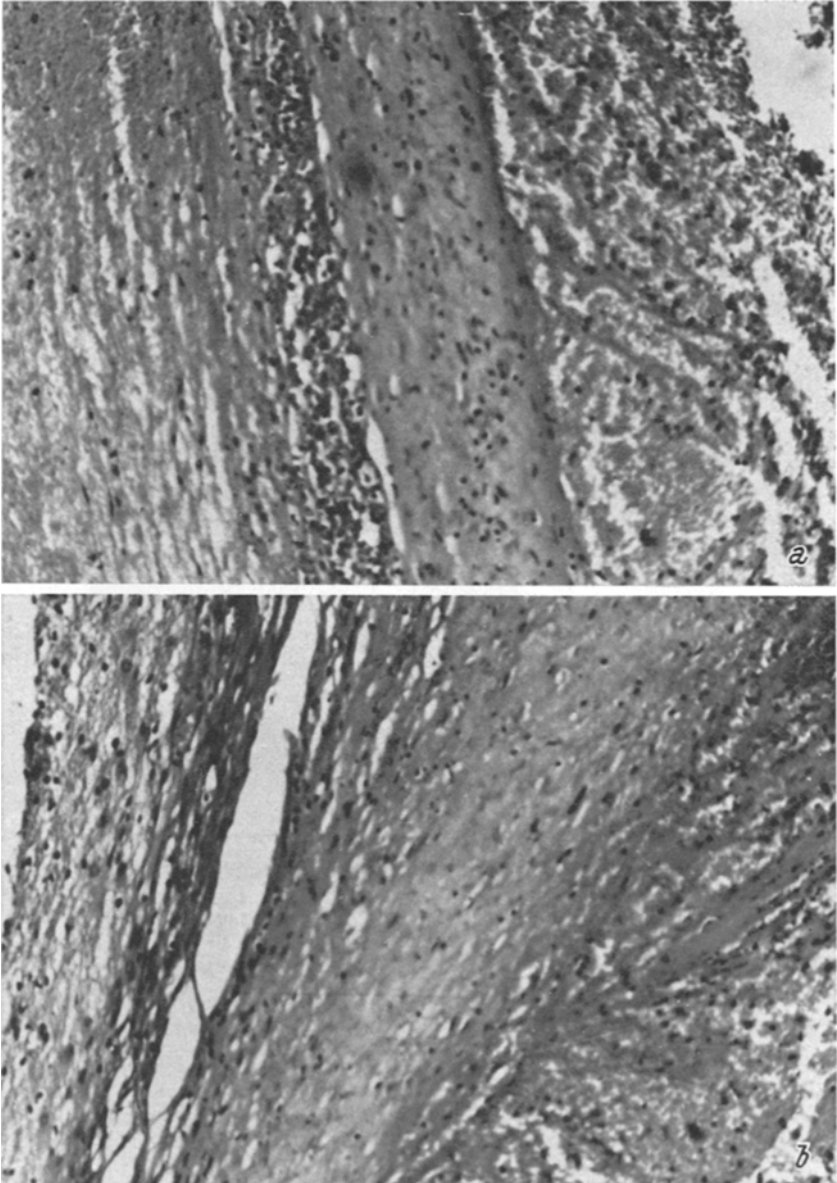


Fig. 3. CT scan (5 December 1977) showing a slight ventricle dilatation with no periventricular hypodensity



Figs. 4 a, b. The surface of the aneurysm, considered in various sections, shows different architecture and pathology: disruption of the normal sequence of the original layers, widespread inflammatory cells, badly organized thrombosis, recent haemorrhages

*Microscopic Examination of the Aneurysm*

The architecture of the original vessel wall appears definitely disturbed. The muscular layer is irregularly thinned and the endothelial covering is frequently disrupted. An incompletely organized thrombus adheres firmly to the inner surface of the aneurysm, while leucocyte nests are widespread among the different structures. On the outer surface of the "berry" a recent blood effusion is detectable. The specific stains for elastic tissue clearly show a complete disappearance of both the internal and external elastic layers with a few randomly distributed residual fibres along the varying thickness of the aneurysmal wall (Figs. 4 a and b).

**Discussion**

There are only 25 reported cases of saccular intracranial aneurysm diagnosed during life in children less than 3 years old (Table 1). The sex was given in 24 out of the 25 cases, and only 7 were female. Clinical presentation was subarachnoid haemorrhage (SAH) due to aneurysm rupture in only 14 out of 25 patients. In three cases it was due to head injury, in three other cases to hydrocephalus, in one case to macrocephalus, in three cases to seizures, and in six cases to motor deficits.

The aneurysm in the 24 cases fully described was located 13 times at the level of the middle cerebral artery (MCA) or its branches, 7 times at the level of the internal carotid artery (ICA), anterior carotid artery (ACA), or anterior communicating artery (ACoA) and their branches, twice at the level of the posterior cerebral artery (PCA), and only twice in the posterior fossa (basilar artery and posterior inferior cerebellar artery). Surgery was performed 21 times in the 25 cases described. Results were excellent or good in 16 cases, fair in 3 cases, and there were two deaths (0.5%). The youngest patient to be operated on was a four-week-old girl reported by Jones and Sheaburn in 1961<sup>20</sup>. The largest intracranial aneurysm was reported by Ventureyra *et al.* in 1980<sup>40</sup>. It was a giant globoid aneurysm, 8 × 9 cm in size, arising from an anomalous posterior cerebral artery. Histology was examined in only seven cases.

Nineteen other cases were discovered at autopsy in children less than three years old (Table 2). The sex was given in 16 cases out of 19, and 7 were female. The youngest infant was 64 hours old, and a 42 mm embryo with a basilar aneurysm was also reported. The clinical presentation was SAH in five cases, hydrocephalus with posterior fossa or third ventricle mass in two cases, hydrocephalus alone in 1 case, seizures in two cases, head injury in two cases, and motor deficits in two cases. The aneurysm location was infratentorial in 8 cases out of 19, at the level of PCA in 3 cases, at the level of ICA, ACA, ACoA and their branches in 5 cases, and at the level of

Table 1. *Early Childhood Arterial Aneurysms Diagnosed During Life*

Authors	Location of aneurysm <sup>*</sup>	Sex	Age	Clinical presentation	Surgical outcome	Histology
Amacher and Drake <sup>2</sup>	MCA (peripheral branch)	M	12 months	head injury	good	—
Amacher and Drake <sup>2</sup>	P. call (L)	M	6 months	head injury, coma	fair	—
Arai <i>et al.</i> <sup>3</sup>	MCA (L)	M	20 months	seizures	no surgery, died of respiratory arrest	—
Arai <i>et al.</i> <sup>4</sup>	MCA (R)	M	24 months	SAH, L. hemiparesis	good	—
Becker <i>et al.</i> <sup>5</sup>	MCA (L)	F	26 months	right hemiparesis	excellent	—
Bolander <i>et al.</i> <sup>6</sup>	ACoA	M	11 months	SAH	no surgery died 2 days after SAH	—
Breschi <i>et al.</i> <sup>8</sup>	DNP	M	4 months	SAH	hydrocephalus, mild deficits	yes
Ferry <i>et al.</i> <sup>13</sup>	BA	M	3 months	SAH, hydrocephalus, L. hemiparesis, ophthalmoplegia	no surgery, died at 5 months	yes
Garcia-Chavez and Moossy <sup>15</sup>	MCA (L)	M	5 months	SAH	R. hemiparesis	yes
Grode <i>et al.</i> <sup>17</sup>	MCA (L)	F	7 weeks	SAH	excellent	—
Grode <i>et al.</i> <sup>17</sup>	MCA (R)	F	3 months	SAH	excellent	—

Hamhill and Carter <sup>18</sup>	MCA (L)	DNP	5 months	DNP	good	yes
Jones and Sheaburn <sup>20</sup>	MCA (R)	F	4 weeks	seizures, SAH	excellent	—
Kimbell <i>et al.</i> <sup>21</sup>	MCA (R)	M	16 months	head injury, SAH	minimal deficits	yes
Lapras <sup>23</sup>	AChA (R)	M	11 months	headache, vomiting	excellent	—
Lemmen and Schneider <sup>25</sup>	PCA	M	8 months	hydrocephalus	died	—
Matson <sup>28</sup>	PICA (L)	M	23 months	SAH	excellent	—
Matson <sup>28</sup>	MCA (R)	M	16 months	SAH, sudden coma	died	—
Milhorat Th. H. <sup>30</sup>	P. call (R)	M	12 months	DNP	excellent	—
Morelli <i>et al.</i> <sup>31</sup>	ACA (L)	M	4 months	SAH, R. hemiparesis	excellent	—
Paoletti <i>et al.</i> (this paper)	MCA (L)	M	34 months	SAH, R. hemiparesis	excellent	yes
Shucart and Wolpert <sup>34</sup>	ICA (L)	M	6 months	diabetes insipidus	excellent	—
Thompson and Pribram <sup>37</sup>	ICA (R)	F	1 month	ophthalmoplegia, L. hemiparesis	no surgery	—
Vapalathi <i>et al.</i> <sup>39</sup>	MCA (R)	F	3 months	SAH, seizures	excellent	yes
Ventureyra <i>et al.</i> <sup>40</sup>	PCA (L)	F	6 months	macrocephalus, anemia	excellent	—

\* Key to table: ACA = anterior cerebral artery, AChA = anterior choroidal artery, ACoA = anterior communicating artery, BA = basilar artery, C of W = circle of Willis, DNP = data not presented, ICA = internal carotid artery, L = left, MCA = middle cerebral artery, PCA = posterior cerebral artery, PICA = posterior inferior cerebellar artery, P. call = pericallosal artery, R = right, V = vertebral

Table 2. *Early Childhood Arterial Aneurysms Discovered at Autopsy*

Authors	Location of aneurysm *	Sex	Age	Clinical presentation	Histology
Alpers <sup>1</sup>	BA	F	2 months	DNP	—
Bremer <sup>7</sup>	BA	DNP	embryo (42 mm)	DNP	—
Devadiga <i>et al.</i> <sup>10</sup>	ICA (?)	M	14 months	seizures, hemiparesis, ophthalmoplegia	—
Dial and Maurer <sup>11</sup>	V (R)	M	33 months	head injury, SAH	yes
Fearnside <sup>12</sup>	ACoA	DNP	19 months	DNP	—
Forster and Alpers <sup>14</sup>	BA (bifurcation)	M	3 months	seizures, sudden coma	yes
Garcia-Chaves and Moossy <sup>15</sup>	ACA (L)	F	2 months	SAH	yes
Jane <sup>19</sup>	PICA (L)	M	12 months	hydrocephalus, posterior fossa mass	yes
Lee and Kandall <sup>24</sup>	BA (bifurcation)	F	13 days	DNP	yes
Lemmen and Schneider <sup>25</sup>	PICA (?)	M	8 months	hydrocephalus, posterior, 3rd ventricle mass	—
Lipper <i>et al.</i> <sup>26</sup>	PCA (L)	F	19 days	SAH	yes
McDonald and Korb <sup>29</sup>	MCA (L)	M	18 months	DNP	—
Newcomb and Munns <sup>32</sup>	PCA (?)	M	64 hours	SAH	—
Newcomb and Munns <sup>32</sup>	C of W	M	23 days	head injury, SAH	yes
Pool and Potts <sup>33</sup>	MCA (L)	DNP	11 months	hydrocephalus	—
Talbot <sup>35</sup>	MCA (?)	M	18 months	DNP	—
Thompson and Pribram <sup>37</sup>	ICA (?)	F	9 months	ophthalmoplegia, quadriplegia	—
Thompson <i>et al.</i> <sup>36</sup>	PCA (?)	F	12 months	DNP	—
Valle and Cavalcanti <sup>38</sup>	BA	F	2 months	DNP	yes

\* Key to table: See Table 1.



MCA and its branches in 3 other cases. Histological examination was performed in 8 cases out of 19.

In conclusion, it appears that the incidence of saccular intracranial aneurysm in infancy is very low, because only 44 cases have been described in 65 years (from the report of Fearnside's in 1916 to date). SAH was present in only 19 cases out of the 35 fully described (54.3%), while an intracerebral haematoma was present in 12 cases (34.3%). Aneurysm in this age group occurs in unusual locations compared to those in late childhood and in adults. Peripheral branches of the MCA and ACA and the bifurcation of the ICA are frequent sites, but infratentorial aneurysms were also present 10 times in the 43 cases described (23.3%).

#### Acknowledgements

We are grateful to Mrs. N. Gnes for preparing the manuscript.

#### References

1. Alpers, B. J., Aneurysms of the circle of Willis: Morphological and clinical observations. In: Intracranial aneurysms and subarachnoid hemorrhage, pp. 5—24 (Fields, W. S., *et al.*, eds.). Springfield, Ill.: Ch. C Thomas. 1965.
2. Amacher, A. L., Drake, C. G., Cerebral artery aneurysms in infancy, childhood and adolescence. *Child's Brain* 1 (1975), 72—80.
3. Arai, H., Sugiyama, Y., Kawakami, S., Miyazawa, N., Multiple intracranial aneurysms and vascular malformations in an infant: Case report. *J. Neurosurg.* 37 (1972), 357—360.
4. Arai, H., Ueki, K., Takahara, Y., Intracranial aneurysm in an infant. *Surg. Neurol.* 1 (1973), 94—96.
5. Becker, D. M., Silverberg, G. D., Nelson, D. H., Hanbery, J. W., Saccular aneurysm of infancy and early childhood. *Neurosurg.* 2 (1978), 1—7.
6. Bolander, H., Hassler, O., Liliquist, B., West, K. A., Cerebral aneurysm in an infant with fibromuscular hyperplasia of the renal arteries. Case report. *J. Neurosurg.* 49 (1978), 756—759.
7. Bremer, J. L., Congenital aneurysms of the cerebral arteries: An embryologic study. *Arch. Pathol.* 35 (1943), 819—831.
8. Breschi, F., Passerini, A., Migliavacca, F., L'emorragia subaracnoidea: aspetti clinici, chirurgici e radiologici. *Gaslini* 8 (1976), 107—112.
9. Cambria, S., Cardia, E., Macri, E., Anévrysme géant de l'artère Sylvienne chez un enfant de quatre ans (ésérèse, guérison). *Neurochirurgie* 22 (1976), 85—90.
10. Davadiga, K. V., Mathai, K. V., Chandy, J., Spontaneous cure of intravenous aneurysm of the internal carotid artery in a 14 month old child: Case report. *J. Neurosurg.* 30 (1969), 165—168.
11. Dial, D. L., Maurer, G. B., Intracranial aneurysms: Report of 13 cases. *Amer. J. Surg.* 35 (1937), 2—21.
12. Fearnside's, E. G., Intracranial aneurysms. *Brain* 39 (1916), 224—296.
13. Ferry, P. C., Kerber, C., Peterson, D., Gallo, A. A., Jr., Arteriectasis, subarachnoid hemorrhage in a three-month-old infant. *Neurology (Minneapolis)* 24 (1974), 494—500.

14. Forster, F. M., Alpers, B. J., Aneurysm of the circle of Willis associated with congenital polycystic disease of the kidneys. *Arch. Neurol. Psychiat.* 50 (1943), 669—676.
15. Garcia-Chavez, C., Moosy, J., Cerebral artery aneurysm in infancy: Association with agenesis of the corpus callosum. *J. Neuropathol. Exp. Neurol.* 24 (1965), 492—501.
16. Gerosa, M., Licata, C., Fiore, D. L., Iraci, G., Intracranial aneurysms of childhood. *Child's Brain* 6 (1980), 295—302.
17. Grode, M. L., Saunders, M., Carton, C. A., Subarachnoid hemorrhage secondary to ruptured aneurysms in infants. Report of two cases. *J. Neurosurg.* 49 (1978), 898—902.
18. Hamill and Carter, cited in Reference 10.
19. Jane, J. A., A large aneurysm of the posterior inferior cerebellar artery in a 1-year-old child. *J. Neurosurg.* 18 (1961), 245—247.
20. Jones, R. K., Sheaburn, E. W., Intracranial aneurysm in a four-week-old infant: Diagnosis by angiography and successful operation. *J. Neurosurg.* 18 (1961), 122—124.
21. Kimbell, F. D., Jr., Llewellyn, R. C., Kirgis, H. D., Surgical treatment of ruptured aneurysm with intracerebral and subarachnoid hemorrhage in a 16-month-old infant. *J. Neurosurg.* 17 (1960), 331—332.
22. Laitinen, L., Arteriella aneurysm med. subarahnoidalblödning hos barn. *Nord. Med.* 71 (1964), 329—333.
23. Lapras, Cl., cited in Reference 22.
24. Lee, Y. J., Kandall, S. R., Gahli, V. S., Intracerebral arterial aneurysm in a new born. *Arch. Neurol.* 35 (1978), 171—172.
25. Lemmen, I. J., Schneider, R. C., Aneurysm in the third ventricle. *Neurology (Minneap.)* 3 (1953), 474—476.
26. Lipper, S., Morgan, D., Krigman, M. R., Staab, E. V., Congenital saccular aneurysm in a 19-day-old neonate: Case report and review of the literature. *Surg. Neurol.* 10 (1978), 161—165.
27. Locksley, H. B., Report on the cooperative study of intracranial aneurysms and subarachnoid hemorrhage, Section 5, Part 1. Natural history of subarachnoid hemorrhage, intracranial aneurysms and arteriovenous malformation. *J. Neurosurg.* 25 (1966), 219—239.
28. Matson, D. D., Intracranial arterial aneurysms in childhood. *J. Neurosurg.* 23 (1965), 578—583.
29. McDonald, C. A., Korb, M., Intracranial aneurysms. *Arch. Neurol. Psychiat.* 42 (1939), 298—328.
30. Milhorat, Th. H., *Pediatric neurosurgery*, pp. 334—335. Philadelphia: F. A. Davis Co. 1978.
31. Morelli, R. J., Laubscher, F., Intracranial aneurysm in infancy. Case report. *J. Neurosurg.* 46 (1977), 832—834.
32. Newcomb, A. L., Munns, G. F., Rupture of aneurysm of the circle Willis in the newborn. *Pediatrics* 3 (1949), 769—772.
33. Pool, J. L., Potts, D. G., Aneurysms and arteriovenous anomalies of the brain: diagnosis and treatment. New York: Harper and Row. 1965.
34. Shucart, W. A., Wolpert, S. M., An aneurysm in infancy presenting with diabetes insipidus. *J. Neurosurg.* 37 (1972), 368—370.
35. Talbot, F. B., *Contribution to Medical and Biological Research*, Vol. 2. New York: B. Hoeber Publishers, Inc. 1919.
36. Thompson, J. R., Harwood-Nash, D. C., Fitz, C. R., Cerebral aneurysms in children. *Amer. J. Roentgenol.* (1973), 163—175.

37. Thompson, R. A., Pribram, H. F. W., Infantile cerebral aneurysm associated with ophthalmoplegia and quadriparesis. *Neurology (Minneap.)* 19 (1969), 785—789.
38. Valle and Cavalcanti in Alpers, B. J., Aneurysms of the circle of Willis: Morphological and clinical considerations. In: *Intracranial aneurysms and subarachnoid hemorrhage*, p. 7 (Fields, W. S., Sahs, A. L., eds.). Springfield, Ill.: Ch. C Thomas. 1965.
39. Vapalahti, P. M., Schugk, P., Tarkkanen, L., Björkesten, G., Intracranial arterial aneurysm in a three-month-old infant: Case report. *J. Neurosurg.* 30 (1969), 169—171.
40. Ventureyra, E. C. G., Choo, S. H., Benoit, B. C., Super giant globoid intracranial aneurysm in an infarct. Case report. *J. Neurosurg.* 53 (1980), 411—416.

Authors' address: P. Paoletti, M.D., Direttore, Clinica Neurochirurgica dell'Università di Pavia, Piazza Golgi, I-27100 Pavia, Italy.