

Bilateral Deafness of Vascular Origin

521

RAMESH K. KHURANA, M.D., PHILIP P. O'DONNELL, M.D.,
CHARLES M. SUTER, PH.D., AND M. INAYATULLAH, M.D.

SUMMARY Two patients with reversible bilateral deafness of vascular etiology are reported. Serial audiometric studies in the first patient before and after a brainstem stroke indicated retrocochlear auditory dysfunction. The second patient showed bitemporal infarction on cranial CT scan which was subsequently confirmed postmortem.

Stroke, Vol 12, No 4, 1981

REPORTS of bilateral lesions causing auditory deficit in man are infrequent.¹ In 1967, for example, Jaffe reported 4 patients with bilateral deafness among 143 patients who developed sudden sensorineural hearing loss.² Deafness of vascular etiology is stated to occur unilaterally and permanent impairment of hearing is a frequent sequel.³ In this paper we describe 2 patients with reversible, sudden bilateral deafness of vascular origin.

Patient 1

At age 50, a hypertensive black man developed dizzy spells. These spells occurred irregularly, 3 to 4 times a day and lasted 3–4 minutes. They were described as a "feeling of being drunk" and were associated with low-pitched tinnitus and slurred speech. Neurological examination, including visual fields and optokinetic nystagmus, was normal. Electronystagmography was normal and audiometry revealed mild, bilateral, high frequency sensorineural hearing loss with good speech discrimination (see table). He was prescribed aspirin. Two months later he complained of aggravation of episodic dizziness, double vision, numbness marching down the left arm and band-like headaches while using the right hand for painting walls and ceiling. His blood pressure was 110/80 mm Hg in both arms; the patient being on thiazide diuretics and potassium supplement. Neurological examination was again normal. Roentgenograms of the skull revealed calcification of the basilar artery posterior to the clivus and of the carotids overlying the sella turcica. Brain scan, electroencephalogram and arch aortogram were normal. Cerebrospinal fluid examination, including glucose and protein values, was also normal.

Two weeks later, after having used the bathroom, the patient suddenly felt vertiginous with a tendency to fall either sideways, forward or backward. He complained of roaring in both ears and deafness. He denied dysarthria, dysphagia, diplopia, focal weakness, sensory loss, or loss of consciousness. General physical examination was normal. Neurological ex-

amination disclosed an alert individual with normal higher cortical functions. Examination of cranial nerves revealed bilateral counterclockwise rotatory nystagmus as well as vertical nystagmus, both accentuated upon standing. He had bilateral hearing loss, right greater than left; and cold caloric stimulation of the left ear caused nystagmus to the right while the right ear stimulation produced no response. Examination of the motor and sensory systems, including plantar responses, were normal. His station was broad-based and ataxic, with a tendency to fall to the left. Tests of coordination revealed an intention tremor of the left upper extremity. Laboratory data on admission included normal results of complete blood count, electrolytes, glucose and electrocardiogram.

Selective cerebral angiography showed normal carotid circulation. The arch study revealed marked stenosis of the right vertebral artery at its origin but this artery could not be selectively catheterized. Selective angiography of the left vertebral artery showed significant stenosis with minimal flow into the posterior fossa. The intracranial portion of the basilar artery could not be visualized.

Audiometry revealed bilateral sensorineural deficit with poor speech discrimination on the right (table). There was a type IV Bekesy audiogram in the right ear as well as total loss of the acoustic reflex in that ear. In the left ear there was loss of the acoustic reflex at 2 and 4 KHZ. Acoustic reflex decay was present at 1 KHZ in the left ear.

The patient continued to improve and 2 weeks later neurologic findings included rotary nystagmus to the left, improved hearing, broadbased gait and a tendency to fall to the left. Audiometry demonstrated mild improvement in speech reception threshold (table).

In another 2 weeks, the patient developed vertical upward nystagmus, horizontal nystagmus, left peripheral seventh nerve paresis, right hemiparesis with a right Babinski sign and incoordination of the right extremities. The patient continued to improve and was discharged on aspirin.

During the next 3 months, he was able to hear people talk and able to walk unaided. Nine months after discharge, he showed mild right hemiparesis, normal plantar responses and normal cerebellar and sensory findings. Audiometry showed recovery of hearing to the pre-infarction level (table). There was a type II Bekesy audiogram in the right ear and the acoustic reflex had returned except at 4 KHZ. There was no acoustic reflex decay in either ear.

From the Department of Neurology (Drs. Khurana and O'Donnell), Otolaryngology (Dr. Suter) and Medicine (Dr. Inayatullah), University of Maryland Hospital, Baltimore, MD 21201.

Reprints: Dr. Khurana, Dept. Neurology, University of Maryland School of Medicine, 22 South Greene St., Baltimore, MD 21201.

TABLE Audiometric Results: Patient 1

Time	Hearing Loss		dB HL		AD/AS		SRT	PB %
	250	500	1000	2000	4000	8000Hz		
3 months before stroke	20/20	10/10	15/15	25/25	30/35	40/40	15/10	92/92
3 days after stroke	65/35	70/35	75/35	60/40	70/55	75/60	70/35	Poor/92
16 days after stroke	45/40	45/35	50/25	55/30	50/55	80/55	50/25	28/84
10 months after stroke	20/5	20/5	10/5	25/25	35/40	55/50	15/5	96/92

One year later, brainstem evoked audiometry was performed. His behavioral thresholds for the click stimulus were 30 and 25 dBHL, AS and AD respectively. Wave V latencies and I-V latency differences were normal for both sides. However, there appeared to be a consistent reduction in wave III amplitude for the right ear stimulation as compared to the left.

Patient 2

A 24-year-old right-handed black man suffered the sudden onset of a left hemiparesis with dysarthria. Serological tests for syphilis, erythrocyte sedimentation rate, lupus erythematosus cell preparation, antinuclear antibody titers, blood culture, echocardiography and cerebrospinal fluid examination were normal. The electroencephalogram showed a right frontotemporal delta wave focus. Cranial computed tomography revealed a right temporal infarction. Multiple distal branch occlusions of the right middle cerebral artery complex were evident on cerebral angiography. The patient improved gradually.

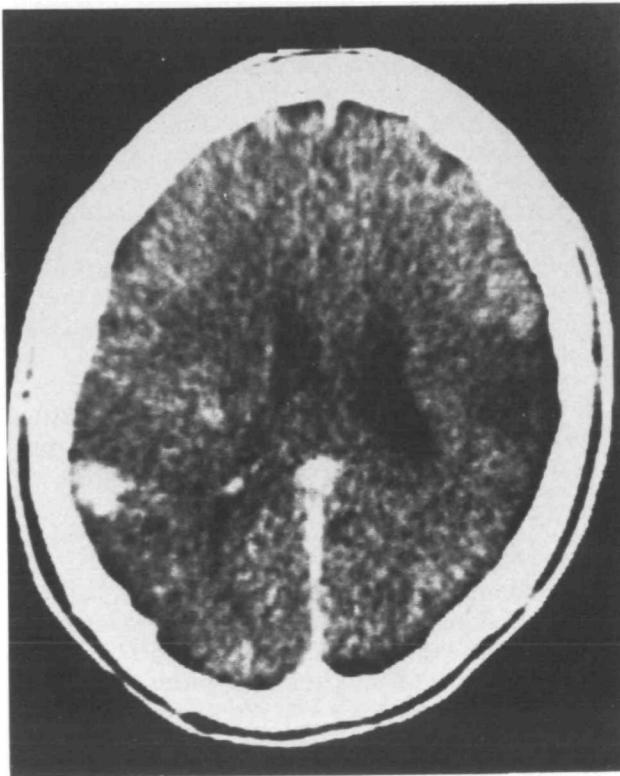


FIGURE 1. Computerized axial tomogram showing temporo-parietal lesion on the left and temporal lesion on the right.

Five months later, the patient experienced sudden deafness while watching television. Physical examination now revealed a hitherto undetected loud holosystolic murmur at the cardiac apex. He was afebrile and without signs of peripheral emboli. Neurological examination showed the patient to be completely deaf for spoken language as well as non-language sounds. He could not be startled by sudden loud noises. Communication was achieved by writing notes and occasional paragraphic errors were noted. Spontaneous speech was fluent with infrequent phonetic paraphasias. The remainder of the neurological examination was normal except for the residual left hemiparesis.

A repeat cranial computed scan showed a new area of damage in the left temporo-parietal region (fig. 1). Correspondingly, new theta activity in the left mid-temporal area was present on the electroencephalogram. The cerebrospinal fluid was normal. A repeat echocardiogram revealed an intracardiac mass attached to the anterior mitral valve leaflet. Intravenous heparin was started.

On the second hospital day, brainstem evoked audiometry was performed with 70 decibel rarefaction clicks delivered monaurally at a rate of 10.3 clicks per second. Well-defined responses with normal absolute latencies of waves I, III, and V were obtained bilaterally. The patient's behavioral hearing threshold could not be tested.

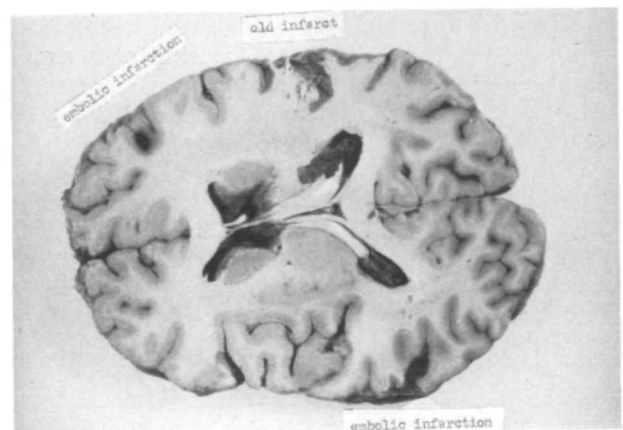


FIGURE 2. Horizontal section of the cerebral hemispheres demonstrating tumor emboli in the left superior temporal and the right middle frontal convolutions. An area of encephalomalacia is seen in the right superior temporal gyrus.

On the fourth hospital day a myxomatous tumor was removed from his mitral valve and a prosthetic valve inserted. In the immediate postoperative period the patient's hearing was improved so that he could comprehend spoken language but he continued to encounter difficulty conversing if extraneous noises, e.g. television, were present. He declined further neuro-otologic assessment. The final histologic diagnosis of the tumor was malignant myxosarcoma.

Three weeks later, the patient died of an acute pericardial tamponade. Postmortem examination disclosed tumor emboli in the left superior temporal and right middle frontal convolutions (fig. 2). Microscopic examination of the emboli showed myxosarcomatous tissue identical to the surgical pathologic specimen from the heart. An old infarction was also present in the right superior temporal gyrus. Sections of the brainstem were normal.

Discussion

These 2 patients illustrate the 2 different sites of vascular damage to the auditory pathways that produced bilateral deafness. The first patient developed deafness due to brainstem involvement as indicated by the absent caloric response of the right ear, vertical nystagmus, a left peripheral facial paresis, left-sided intention tremor and right hemiparesis. In addition, the audiometric studies demonstrated retrocochlear dysfunction.⁴ Deafness and neurologic dysfunction gradually improved.

Our second patient developed transient deafness for all sounds due to bitemporal infarction from a myxosarcoma of the mitral valve as documented by the cranial CT scan and autopsy.^{5, 6} The normal brainstem auditory evoked responses suggested the intactness of auditory pathways from the acoustic nerve to inferior colliculi⁷ and no lesion affecting the brainstem was found postmortem. These patients suggest that vertebral-basilar insufficiency should be included in the differential diagnosis of bilateral sudden deafness⁹ and that computed tomography and neuro-otological studies can help in the precise localization of the lesion to the auditory pathways.

It is interesting to note that compared to vestibular disturbances cochlear disturbances in vertebralbasilar

insufficiency are rare.⁹ For example, Fisher, in his study of 112 cases of vertebralbasilar insufficiency, reported dizziness in 86 patients while only 10 patients complained of deafness.³ This contrast becomes more apparent when one observes the anatomical proximity of the peripheral and central cochlear and vestibular pathways, lack of collaterals to the labyrinthine artery and the limited cochlear tolerance for ischemia in the experimental and human studies.¹⁰⁻¹² Could it be that a unilateral or incomplete bilateral deafness goes unnoticed by the patient and the physician? If this is so, audiometric evaluation of patients with vertebralbasilar insufficiency may show the incidence of partial deafness to be higher than previously reported.

Acknowledgment

The authors wish to thank Mrs. Anne Dimiceli for secretarial help.

References

1. Howe JR, Miller CA: Midbrain deafness following head injury. *Neurology (Minneapolis)* **25**: 286-289, 1975
2. Jaffe BF: Sudden deafness, an otologic emergency. *Arch Otolaryng* **86**: 55-60, 1967
3. Fisher CM: Vertigo in cerebrovascular disease. *Arch Otolaryng* **85**: 529-534, 1967
4. DeJong RN: The Acoustic Nerve. *In* The Neurologic Examination, Chapter 14. Hagerstown, Maryland, Harper and Row, 1979, pp 199-224
5. Earnest MP, Monroe PA, Yarnell PR: Cortical deafness: demonstration of the pathologic anatomy by CT scan. *Neurology (Minneapolis)* **27**: 1172-1175, 1977
6. Joynt RJ, Zimmerman G, Khalijeh R: Cerebral emboli from cardiac tumors. *Arch Neurol* **12**: 84-91, 1965
7. Chiappa KH, Gladstone KJ, Young RR: Brain stem auditory evoked responses—studies of waveform variations in 50 normal human subjects. *Arch Neurol* **36**: 81-87, 1979
8. Williams D, Wilson GT: The diagnosis of the major and minor syndromes of basilar insufficiency. *Brain* **85**: 741-774, 1962
9. Millikan CH, Siekert RG, Whisnant JP: The syndrome of occlusion of the labyrinthine division of the internal auditory artery. *Transactions of the American Neurological Association* **84**: 11, 1959
10. Smith CA: Vascular patterns of the membranous labyrinth. *In* de Lorenzo AJ (ed) *Vascular Disorders and Hearing Defects*. Baltimore, University Park Press, pp 1-21, 1973
11. Suga F, Preston J, Snow JB: Experimental microembolization of cochlear vessels. *Arch Otolaryng* **92**: 213-220, 1970
12. Gussen R: Sudden deafness of vascular origin: a human temporal bone study. *Ann Otol* **85**: 94-100, 1976