

Chronic Intracerebral Hematoma

David Yashon, M.D., and Edward J. Kosnik, M.D.

Division of Neurological Surgery, College of Medicine, The Ohio State University, Columbus, Ohio

Twelve patients with chronic intracerebral hematoma are reported. This condition may be unrecognized as possibly being benefited by relatively simple diagnostic and therapeutic measures. The neurological symptoms and signs may be acute but may also be intermittent and progressive. The etiology is usually systemic hypertension, but trauma, coagulopathies, and obscure etiologies have been implicated. After diagnosis by computerized tomographic scan and/or arteriography, aspiration of the liquid hematoma usually results in improvement. It is hypothesized that recovery is hastened by removal of the hematoma. Often complete recovery ensues, but mild to severe neurological signs may persist depending on the initial damage.

Key words: Hematoma, Intracerebral mass, Cerebrovascular disease, Brain hemorrhage

Intracerebral hemorrhage is generally regarded as a rapidly progressive, fulminating disease, sudden in onset, with the outcome being death or profound neurological deficit. There are, however, patients who are found to have chronic intracerebral hematomas, who are relatively easily treated, and who may do well. We have had occasion to treat 12 such patients over a 6-year period (Table 1). This report was prepared because this condition is uncommon and may remain unrecognized.

CASE REPORTS

Case 1

Patient E. B. was a 59-year-old male who sustained a closed head injury with loss of consciousness 5 years before admission. He subsequently developed headaches relieved by aspirin. Three years before admission he had a generalized seizure. One year before admission he again had a seizure and was hospitalized; he was evaluated for hypertension but remained asymptomatic. He was admitted to an outlying hospital for 2 weeks after multiple seizures and was then transferred to our facility. On examination he was lethargic, confused, and aphasic with a right hemiparesis. He had skull roentgenograms, an electroencephalogram (EEG), a left carotid arteriogram, and a pneumoencephalogram, all of which indicated a mass in the left parietal region. A left parietal craniotomy was carried out, and a chronic intracerebral hematoma was drained. Biopsy of the cyst wall was negative for tumor. Postoperatively, the right hemiparesis rapidly improved. The patient was left with a mild expressive dysphasia but returned to a completely functional life.

Case 2

Patient H. B. was a 48-year-old male who was found to be aphasic with a right hemiplegia. He was confused but could follow simple commands; there was a right homonymous hemianopsia. A left carotid arteriogram demonstrated only a 2-mm shift of the anterior cerebral arteries to the right. He was treated with bed rest and steroids. Two weeks later the carotid arteriogram was repeated and suggested a greater shift of the left anterior cerebral artery and the deep veins. A pneumoencephalogram revealed a mass lesion in the left parietal area. A left parietal trephine opening was made, with aspiration of a 75-ml thin bloody intracerebral hematoma. Postoperatively, there was marked improvement in left cerebral function.

Case 3

Patient P. H. was a 62-year-old hypertensive female who had a 4-week history of progressive headache, lethargy, and weakness. Twenty-four hours before admission she fell and sustained a laceration of her left occipital scalp. On examination she was found to be

drowsy with a right hemiparesis. She had decreased spontaneous speech and difficulty in following simple commands. A left carotid arteriogram demonstrated an avascular mass lesion in the left frontal area. Because localization was incomplete, pneumography was carried out. With the diagnosis of a chronic intracerebral hematoma, she was taken to the operating room and 10 ml of old blood was removed by needle aspiration through a burr hole. She made an uneventful recovery and was released on the seventh postoperative day with no deficit.

Case 4

Patient P. A. was a 47-year-old hypertensive male who was admitted after the sudden onset of loss of consciousness. When first seen in the emergency room, he was obtunded and aphasic, and he responded poorly to verbal or painful stimuli. His left pupil was dilated, and he had a dense right hemiparesis (arm worse than leg). A left carotid arteriogram was consistent with a deep ganglionic hematoma, and his prognosis was thought to be grave. He was treated with steroids and supportive care; his status improved slowly for a few days and then stabilized. Early papilledema was noted on the 14th hospital day, and a repeat left carotid arteriogram revealed findings similar to those of the first study. At this time it was felt that the hematoma had liquified. The patient was taken to the operating room where, through a trephine opening, the hematoma was aspirated. His recovery seemed to be speeded by this procedure. He was released with a mild right hemiparesis and mild expressive dysphasia.

Case 5

Patient E. L. was a hypertensive 70-year-old female who was markedly obtunded, with a left hemiparesis. An angiogram revealed a deep avascular mass in the right parietal region. This was felt to be a hypertensive intracerebral hematoma lateral to the thalamus. This patient was observed for 10 days with gradual improvement. On the 11th day trephination and needle aspiration of 25 ml of old hematoma was carried out. The patient's clinical status improved. She became more alert and began to follow simple commands. There was no change in the dense hemiparesis.

Case 6

Patient E. S. was a 37-year-old male who was admitted after being found beaten and unconscious. On examination he was unconscious with no localizing neurological signs. He was treated with steroids and fluid restriction and was observed. He slowly improved over 3 weeks to the point of being disoriented and belligerent. Arteriography at that time demonstrated a left avascular temporal lobe mass. A burr hole was placed over the left temporal lobe, and a 30-ml intratemporal hematoma was evacuated. It seemed that recovery was hastened by this surgical procedure, and the patient was released 2 weeks later with no deficit.

TABLE 1
Case Summary

Patient	Sex	Age (yr)	Location	Neurological Symptoms and Signs	Time from Onset to Surgery	Etiology	Outcome
E. B.	M	59	Left parietal	Seizures, right hemiparesis, aphasia	5 yr	Trauma	Mild expressive aphasia
H. B.	M	48	Left parietal	Confusion, aphasia, right hemiparesis	2 wk	Hypertension	Mild aphasia
P. H.	F	62	Left frontal	Headache, lethargy, right hemiparesis	4 wk	Hypertension	No residua
P. A.	M	47	Left basal ganglia	Stupor, right hemiplegia, aphasia	2 wk	Hypertension	Mild expressive aphasia, mild right hemiparesis
E. L.	F	70	Right parietal	Obtundation, left hemiplegia	10 days	Hypertension	Left hemiparesis
E. S.	M	37	Left temporal	Disorientation	3 wk	Trauma	No residua
N. F.	F	39	Left parietal	Expressive aphasia, right hemiparesis	1 wk	Hypertension	Mild right hemiparesis
H. Q.	F	72	Left parietal	Obtundation, aphasia, right hemiplegia	3 wk	Hypertension	Obtunded, right hemiparesis
K. L.	F	27	Left temporal	Expressive aphasia, seizure	2 wk	Contraceptive medication	No residua
D. S.	M	37	Right frontal	Right frontal headache, left hemiparesis	3 wk	Chemotherapy	No residua
V. K.	M	65	Left frontal	Headache, mild right hemiparesis, lethargy	2 wk	Trauma	No residua
F. J. M.	M	59	Right parietal	Transient left hemisensory symptoms	2 wk	Hypertension	No residua

Case 7

Patient N. F. was a 39-year-old female who had an episode of loss of consciousness and progressive weakness of the right side of the body. There was no history of trauma, but she had been treated for hypertension for 3 years. She was noted to have an expressive aphasia and a right hemiparesis. An arteriogram demonstrated a left parietal avascular mass lesion. She was treated with steroids and antihypertensive medication. After stabilization for 7 days, a cortical incision was made through a left parietal trephine opening and at 2 cm below the surface a hematoma cavity was entered. This contained about 20 ml of old dark blood. The margins of the cavity were biopsied, but no tumor or vascular malformation was found. She did well postoperatively. One year later she had only a mild residual right hemiparesis.

Case 8

Patient H. Q. was a 72-year-old hypertensive female who was found markedly obtunded. She was aphasic with a right hemiparesis. Roentgenograms of the skull showed a 4 to 5-mm shift of the pincal from left to right. She was treated with bed rest, antihypertensive medication, and steroids, and she appeared to be making gradual improvement. By the 10th hospital day, she was able to follow simple commands, although the right hemiparesis persisted. Her improvement reached a plateau, and no further change was noted over the next week. An arteriogram demonstrated a left parietal avascular mass. On the 20th hospital day, a burr hole was placed and needle aspiration of a 30-ml chronic intracerebral hematoma was performed. Postoperatively, the patient gradually improved. She was more lucid and was able to respond verbally to simple commands.

Case 9

Patient K. L. was a 27-year-old female who had a 2-week history of difficulty with word usage. Her speech was intermittently dysphasic. There was no difficulty with comprehension, headache, or other neurological complaint until the morning of admission when she complained of a headache, went to bed, and awakened 1 hour later with a global aphasia. Shortly thereafter, she had a generalized seizure. Postictally, she had a mild expressive aphasia with a minimal receptive component. There were no other objective findings on neurological or physical examination. The only pertinent past history was an 8-year history of the use of contraceptive medication. An EEG demonstrated left temporal slowing. A brain scan was positive, and a carotid arteriogram showed a left temporal mass. A left temporal craniotomy showed that the middle temporal gyrus was edematous and discolored, with the appearance of an underlying intracerebral hematoma. Needle aspiration of the brain recovered

20 ml of chronic dark hematoma fluid with subsequent marked reduction of brain bulk. Dissection along the needle tract into the cavity and biopsy showed only normal brain. The postoperative course was benign with complete resolution of neurological deficit.

Case 10

Patient D. S. was a 37-year-old male with known metastatic melanoma. He had been on chemotherapy for 2 years. Three weeks before admission he noted the onset of a right frontal headache. The headache was mild but constant. He developed a dilated right pupil and a left hemiparesis. A right carotid arteriogram demonstrated a massive frontal shift. The preoperative diagnosis was metastatic tumor. A right craniotomy showed the brain to be markedly edematous. Dissection was carried 3 cm into a chronic hematoma cavity. Multiple areas about the margins of the cavity were biopsied, all of which showed no tumor. There was no evidence of any tumor in the exposed brain or dura. He made a complete and uneventful recovery and was released on the seventh postoperative day with no neurological deficit.

Case 11

Patient V. K. was a 65-year-old male who had a head injury 2 weeks before admission. He initially complained only of mild headache until 24 hours before admission, at which time he developed a right hemiparesis and obtundation. On examination, he had a right hemiparesis and a right "panda bear" eye and was somewhat disoriented. Arteriography demonstrated a large left frontal mass. The diagnosis of chronic intracerebral hematoma was made. Needle aspiration of the left frontal hematoma cavity via a burr hole recovered 50 ml of chronic hematoma fluid. Postoperatively, the patient was alert and the hemiparesis resolved over 36 hours.

Case 12

Patient F. J. M. was a 59-year-old hypertensive male who noted gradually increasing numbness of the entire left side of his body. These symptoms cleared in 12 hours. Examination was negative. Blood pressure averaged 155/90. An EEG, a computerized tomographic (CT) scan (Fig. 1), and a right carotid arteriogram revealed a right parietal avascular mass. Needle aspiration of the mass was carried out 2 weeks after the onset of symptoms, and 30 ml of old blood was aspirated. The patient has been asymptomatic for 1 year.

DISCUSSION

There were 12 patients in this series, 7 males and 5 females ranging in age from 27 to 72. Six patients had

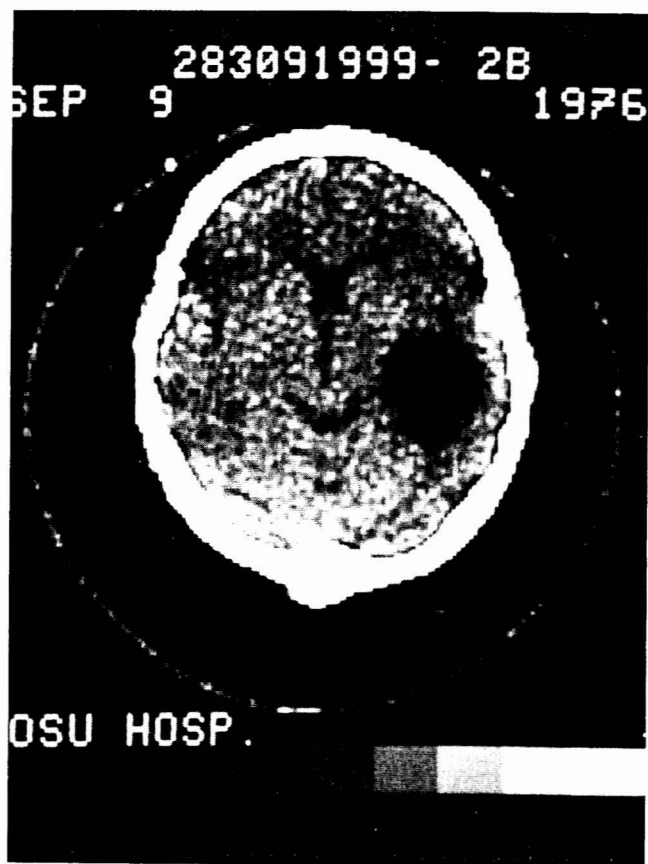


FIG. 1. Case 12. CT scan showing lucent right parietal mass that did not enhance.

parietal hematomas, three had frontal lesions, two had temporal lesions, and one had a deep basal ganglionic hemorrhage. Ten patients had more superficial white matter hemorrhages, as compared to two who had hemorrhages in deep ganglionic areas. This differs considerably from published series of acute intracerebral hematomas (1, 6, 8).

The most common underlying disorder in these patients was hypertension (about 50%). This figure is somewhat lower than that generally encountered in patients with acute intracerebral hematomas (3). Patients with extensive hypertensive intracerebral hematomas generally have a more rapid course and either are operated upon earlier or succumb to the lesion (7).

There were three patients with traumatic intracerebral hematoma. All underwent evacuation of the hematoma with good results. Baratham and Dennyson reported that only 21 of 7866 patients with head injuries developed this complication (2). They noted that these patients initially had done well postinjury, but this was followed by deterioration in level of consciousness and development of neurological signs and symptoms. Bleeding in the form of slow "oozing from the venules" into an area of contusion complicated by hypoxia or venous congestion was postulated as the pathological basis of the chronic hematoma.

One patient in this series had been treated with chloroethyl cyclohexyl nitrosourea (CCNU) for malignant melanoma and had apparently bled 3 weeks before developing symptoms. When initially seen, his laboratory values were normal; however, CCNU characteristically causes leukopenia and thrombocytopenia in a cyclic fashion and probably caused a

transient coagulopathy 3 weeks before admission. There was no evidence either on biopsy or by his subsequent course that an intracerebral metastasis was present.

Another patient was on contraceptive medication. The intracerebral hematoma possibly was a consequence of coagulopathy secondary to medication, although this supposition could not be proven.

Treatment in these patients consisted of evacuation of the hematoma. If there was a question of tumor, biopsy of the walls of the cavity was carried out through a craniotomy. Where surgery could be delayed, as in the case of some hypertensive intracerebral lesions, the hematoma cavity was then later easily aspirated. For this reason, delay in treatment of these lesions when possible has been advocated by Lazorthes (4), McKissock *et al.* (5), and Cuatico *et al.* (3). Surgical intervention in our patients, however, was directed by the clinical status of each patient and not by time.

When the hematoma mimics a slowly growing process such as tumor, postoperative improvement may be rapid. This has been described by others and seems to be true judged by our data (8).

It appears clear that chronic intracerebral hematoma is a condition that should be recognized and possibly treated depending on clinical judgment. The etiology is commonly systemic hypertension, but the hematoma may be due to trauma, coagulopathy, or obscure causes. The diagnosis of a space-occupying lesion is made by CT scan or arteriography. Pneumography should not be performed but was done in two of our patients because of puzzling presentations before the availability of the CT scan. Treatment consists of simple aspiration of the hematoma. When required, biopsy of the intracerebral cavity can be done. Recovery is complete in many cases, but in any event we hypothesize that neurological deficit is lessened by this simple surgical measure.

Received for publication, August 8, 1977; accepted, October 28, 1977.

Reprint requests: David Yashon, M.D., Professor of Neurosurgery, Room N-911, 410 West 10th Avenue, Columbus, Ohio 43210.

REFERENCES

1. Bagley, C. Spontaneous cerebral hemorrhage: Discussion of four types, with surgical considerations. *Arch. Neurol. Psychiatry*, 27:1133-1174, 1932.
2. Baratham, G., and Dennyson, W. G. Delayed traumatic intracerebral hemorrhage. *J. Neurol. Neurosurg. Psychiatry*, 35:698-706, 1972.
3. Cuatico, W., Adib, S., and Gaston, P. Spontaneous intracerebral hematomas: A surgical appraisal. *J. Neurosurg.*, 22:569-575, 1965.
4. Lazorthes, G. Surgery of cerebral hemorrhage: Report on the analysis of the results of 52 surgically treated cases. *J. Neurosurg.*, 16:355-364, 1959.
5. McKissock, W., Richardson, A., and Walsh, L. Primary intracerebral haemorrhage. Results of surgical treatment in 244 consecutive cases. *Lancet*, 2:683-686, 1959.
6. Ojemann, R. G. Intracerebral and intracerebellar hemorrhage. In *Neurological Surgery*, edited by Youmans, J. R., pp. 844-851, Philadelphia, W. B. Saunders, 1973.
7. Paillas, J. E., and Alliez, B. Surgical treatment of spontaneous intracerebral hemorrhage: Immediate and long-term results in 250 cases. *J. Neurosurg.*, 39:145-151, 1973.
8. Pia, H. W. The surgical treatment of intracerebral and intraventricular haematomas. *Acta Neurochir. (Wien)*, 27:149-164, 1972.

COMMENTS

Dr. Yashon and Dr. Kosnik have correctly emphasized that these chronic hematomas differ considerably from the acute intracerebral hematomas that are the subject of most published reports. The prognosis of patients with intracerebral hemorrhages (especially hypertensive hemorrhages) is determined by the amount of brain destroyed initially. In this series no patient was operated upon earlier than 1 week after the hemorrhage.

Although Patient 1 had an injury 5 years earlier, it is open to question whether he still had the same hematoma. Although there may be clinical pressure not to operate upon a patient who is improving, it is interesting that the condition of Patient 8, which had reached a plateau, improved postoperatively. Case 12 is interesting because it showed a radiolucent defect on the CT scan that did not enhance with the contrast agent.

Stewart B. Dunsker, M.D.
Cincinnati, Ohio

The authors have demonstrated well the excellent prognosis after surgical evacuation of nonacute intracerebral hematomas. The operative results should be comparable to the results for removing other benign mass lesions in similar locations. CT scanning is the diagnostic test of choice and will usually allow differentiation between hematomas, abscesses, and tumors. In the early stage, the scan will show a hematoma with varying degrees of blood density. In the chronic stage, there will be a symmetrical ring, seen only on infusion, surrounded by a narrow area of edema.

Angiography should probably be done to rule out a small arteriovenous malformation or aneurysm or perhaps a tumor with a vascular stain. I would favor performing a small

craniotomy for evacuation of the hematoma to ensure complete removal and for biopsy of the wall of the lesion in patients suspected of having tumors.

Although Dr. Yashon and Dr. Kosnik have made a contribution to our understanding of the natural history and management of chronic intracerebral hematomas, they might have mentioned that some patients with large hematomas improve and make a good recovery without evacuation of the lesion, whereas the condition of other patients with similar-sized hematomas in similar locations does not improve or even deteriorates. It is in the latter group that it is necessary to evacuate the hematoma. Thus, the patient's clinical course and the size of the mass dictate the course of action. Why patients with similar lesions similarly located behave differently is not clear.

Contrary to what has been reported (1), we have had a number of patients with traumatic temporal lobe hematomas who presented with a rapid downhill course requiring urgent evacuation of the clot. This problem is more common in the older age group.

The majority of our future efforts should be directed to improving the high mortality and morbidity secondary to acute hypertensive hematomas. In a few patients we have had dramatic results with early removal of large lesions, even intraventricular hemorrhages. Precise localization of the lesion by the CT scanner and the advantages of the operating microscope have made this possible.

David L. Kelly, Jr., M.D.
Winston-Salem, North Carolina

-
1. Courville, C. B., and Blomquist, O. A. Traumatic intracerebral hemorrhage with particular reference to its pathogenesis and its relation to "delayed traumatic apoplexy." *Arch. Surg.*, 41:1-28, 1940.