

Left Unilateral Agraphia and Tactile Anomia

Disturbances Seen After Occlusion of the Anterior Cerebral Artery

Atsushi Yamadori, MD; Yukio Osumi, MD; Hiroto Ikeda, MD; Yasuhisa Kanazawa, MD

• A 53-year-old right-handed Japanese man had a callosal disconnection syndrome associated with an occlusion of the left pericallosal artery. Computerized tomography scan confirmed a left medial lesion affecting the cingulate gyrus, the paracentral lobule, the precuneus of the left hemisphere, and most probably the corpus callosum. This anterior cerebral artery syndrome was characterized by right hemiparesis with predominant crural involvement, unilateral left-sided "disconnection" agraphia, and left unilateral "disconnection" tactile naming deficit.

To our knowledge, this is the first case in the literature of the anterior cerebral artery syndrome in which unilateral left-sided apraxia was not associated with agraphia. The case is also the first in which Kanji-Kana dissociation of an aphasic nature has been reported as a feature of isolated left agraphia.

(*Arch Neurol* 37:88-91, 1980)

When one anterior cerebral artery is occluded, several characteristic signs may develop, depending on the exact site of occlusion. According to Critchley,¹ the most frequently encountered signs are contralateral paralysis of the lower extremity, forced grasping or groping of the ipsilateral upper limb, and ideomotor apraxia of the left arm, regardless of the side of the infarction.

Left-sided ideomotor apraxia was first described by Liepmann and

Maas^{2,3} in a patient with left anterior cerebral artery occlusion. They postulated that it was due to involvement of the corpus callosum, the anterior four fifths of which is nourished by the anterior cerebral artery.^{1,4} According to Liepmann, apraxia of the left hand is a result of disturbed impulse transmission from the leading sensory-motor cortex of the left hemisphere to the right hemisphere.

The role of the callosal lesions as a cause of the left ideomotor apraxia was soon accepted by Liepmann's contemporaries. Tumor cases^{5,6} as well as right-sided anterior cerebral artery occlusion^{7,8} have been reported.

In addition to the left-sided apraxia, left-sided agraphia and left-sided astereognosis had also been observed and were attributed to a lesion of the corpus callosum. The agraphia had been explained as a partial symptom of the left-sided ideomotor apraxia.⁹ The astereognosis had been explained as a loss of the dominant left hemisphere influence of stereognostic capacity over the right hemisphere because of callosal disconnection.⁹

Geschwind and Kaplan,^{10,11} however, presented a consistent and persuasive interpretation of these three unilateral left-sided signs. They explained them as a manifestation of disconnection of the left hemisphere language zones from the right hemisphere due to callosal destruction. Thus the left-sided apraxia to verbal command is a result of disconnection of the verbal order from the right motor cortex. The left-sided agraphia is not simply a partial phenomenon of apraxia, but a sign of disturbed flow of linguistic information from the left hemisphere to the right. The left-sided astereognosis is not an agnosia,

but a failure to name resulting from failure of tactile information to be transmitted from the right to the left hemisphere. The hypothesis based on Geschwind and Kaplan's case of left anterior cerebral artery infarction associated with a left frontal tumor has since been confirmed in patients with callosal section,¹²⁻¹⁵ with tumor,¹⁶ and after trauma.¹⁷

We report a case of the left anterior cerebral artery syndrome with left-sided agraphia and left-sided tactile naming deficit but without left-sided apraxia. Agraphia not accompanied by apraxia has not so far been reported in the anterior cerebral artery syndrome. In addition, the writing behavior observed in this Japanese patient handling Kanji (ideogram) and Kana (phonogram) was aphasic in nature and thus presented further evidence that the left-sided writing disorder has definite linguistic abnormalities.

REPORT OF A CASE

The patient was a 53-year-old right-handed businessman. He had been hypertensive for 18 years. There was diminished hearing and tinnitus in the right ear, resulting from acoustic trauma in childhood. For the past ten years, he had had transient episodes of nausea accompanied by transverse streaming of visual images lasting about 30 minutes and occurring once or twice a month. In December 1976, he experienced sudden loss of power of the right half of the body, which cleared rapidly. There was no loss of consciousness. In July 1977, he experienced general weakness for several minutes. The next day, weakness of the right side appeared. He has continued to drag the right leg since. In the early morning of Dec 14th, 1977, brief painful clonic convulsion of the right leg occurred. Standing was impossible because of weakness of the right leg; in the after-

Accepted for publication Feb 7, 1979.

From the Departments of Neurology and Psychiatry (Drs Yamadori, Osumi, and Ikeda), and Neurosurgery (Dr Kanazawa), Kobe University School of Medicine, Kobe, Japan.

Reprint requests to Department of Neurology and Psychiatry, Kobe University School of Medicine, Kusunokicho 7-chome, Ikutaku, Kobe 650, Japan (Dr Yamadori).

noon the right arm became weak. The right hemiparesis soon worsened and he became dysarthric. Drooling from the right corner of the mouth and inappropriate laughing were noted. He was admitted to the Department of Neurosurgery, Kobe University School of Medicine, on Jan 11, 1978.

On Jan 24, 1978, detailed neuropsychological testing was performed. The patient was observed closely for two weeks until his discharge, but it was not possible to perform subsequent examinations.

The patient was attentive, cooperative, and oriented to time, place, and person. Digit span was five forward. Recent memory was not impaired. Speech comprehension, naming, and repetition were within normal range but with slight slurring and hesitancy. There were no paraphasic or grammatical errors. Reading and calculation were good. Serial sevens were performed without error. Copying of a cube and drawing of a human face were done well with either hand. No apraxia to verbal command was detected in buccofacial, limb, and whole body movements, or in object handling. He could imitate with eyes closed and with either hand postures imposed on the fingers of the other hand by the examiner.

There was right-sided weakness with predominant involvement of the lower extremity, which was almost immobile. In the right upper extremity, there was predominantly proximal weakness, with the hand least affected. The right hand showed a strong grasp response and he had difficulty releasing objects placed in that hand. Often he had to release the grasp by extending each finger with the help of the left hand. Muscle stretch reflexes were hyperactive on the right with a Babinski sign. Sensation to touch and pain was slightly impaired in the right lower extremity (30% decreased, by the patient's description), but there was no loss in the upper extremity. Position sense of both toes and fingers was uncertain and often incorrect on the right side. Two-point discrimination was normal in both hands. Point localization was intact on the right side. In the left arm and hand, there was wandering of the pointing right index finger, although it reached the correct spot eventually. Double simultaneous stimulation was correctly perceived on both sides. Vibration sense was reduced slightly on the right side. Cranial nerve functions were intact except for slight right central facial weakness. Details of specific findings are described below.

SPECIAL EXAMINATION RESULTS

Writing

Despite the mild paresis and strong grasp reflex, the right hand made no linguistic errors in spontaneous writing or writing to dictation. There was a tendency for letters to become smaller and for the space between the letters to get narrower as the patient continued to write.

In contrast, writing with the left hand was markedly impaired. There were many unintelligible letters. Some letters could be made out but were not graphically correct because of added or missed strokes. Also, graphically correct letters were arranged in wrong order, substituted for by different letters, or perseverated. There was a definite tendency for Kanji (ideograms or logograms, nonphonetic representations of word meaning) to be correctly produced more often than Kana (phonograms, words written phonetically). For instance, an ideogram *kumo* (cloud) was written correctly, but the two phonograms of *ku* and *mo* were written incorrectly. (Note: Substantive words such as *kumo* can be written either way.) He wrote a complex Kanji graphem of *kumo* correctly after he had written a different character, "thunder," which resembles the former character in shape and meaning. On the other hand, when he was asked to write these characters in Kana he produced two unintelligible Kana-like patterns and two correct Kana *mo* and *ku* (ie, in reversed order).

Copying of letters and sentences was correctly performed with either hand, although left-handed copying was very clumsy.

Written Calculation

Written calculations were tested using both hands. Unilateral (left hand) acalculia was present. For example, multiplication of 126×41 was correctly performed with the right hand. However, the left hand produced many perseverative 1s and 6s and could not produce a correct answer. The patient kept saying that he could not help producing "6." It seemed that incorrect production of digits by the left hand made a correct operation impossible.

Tactile Object Identification

Objects were placed in either hand for identification. The patient was blindfolded. The right hand could not manipulate objects, which usually remained tightly held in the location in which they had been placed by the examiner. Naming of objects placed in this hand, however, was prompt and correct without exception. In contrast, the left hand could manipulate an object appropriately and adroitly. But naming of objects held in this hand was slow, hesitant, and often incorrect; 52 objects were presented over three sessions, with 38 correct responses and 13 incorrect. Incorrect answers were characterized by per-




Fig 1.—Kanji writing. Right, Correct writing by right hand of Kanji *kumo*. Left, Writing by left hand of Kanji "thunder" instead of "cloud" (*kumo*). Second attempt by left hand (center) was correct.




Fig 2.—Kana writing. Right column in descending order, *ku* and *mo* were correctly written by right hand. Left column in descending order, unintelligible character, correct *mo*, correct *ku*, and unintelligible character were produced by left hand.

severation of the same name or by gross confabulation.

For example, "toothbrush" was correctly used on the first occasion and was then used for such dissimilar objects as scissors, pencil, and wire. The patient described a handkerchief as "something like a toothbrush," or "something is attached on top."

When naming was incorrect, the patient was given the opportunity to choose the object from five objects using the same left hand. With vision shielded, this was easily done, demonstrating good preservation of stereognostic capacity.

Graphesthesia

Arabic numerals and Kana letters were traced on the palms of both hands for naming. Surprisingly, all numerals written on the left hand were identified correctly and promptly. However, the patient showed defi-

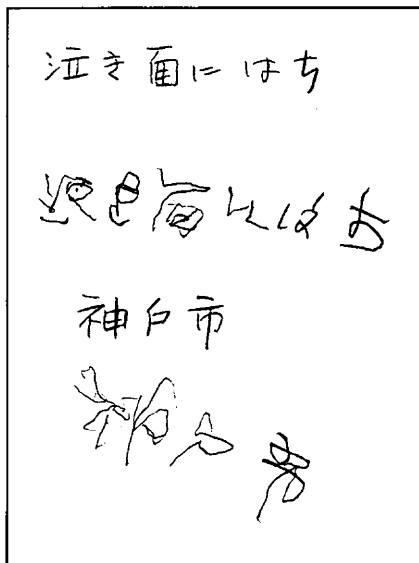


Fig 3.—Copying with left hand. Characters are written clumsily but are correct in their essential pattern. First and third lines are model sentences; second and fourth lines show patient's performance.




Fig 4.—Right, correctly performed multiplication by right hand. Left, unsuccessful performance by left hand. Note perseverative tendency.

nite difficulty in naming numerals written on the right palm; he was slow and hesitant in response and very often stated that he did not know the answer. Of 20 digits tested on the two occasions, only five were correct. The pattern of failure is a reversal of that seen on the test of tactile naming, but it should be noted that there was not a single perseverative or confabulatory error, in contrast to what was observed in the naming test.

In reading of Kana no such distinct differences between the two hands were observed, but those Kana presented on the left palm tended to be identified more frequently than ones on the right. Of eight Kana written on each palm, none was named on the right, while four were correctly named on the left. Again, there were no perseverative, confabulatory, or paraphasic errors. Kanji was not tested

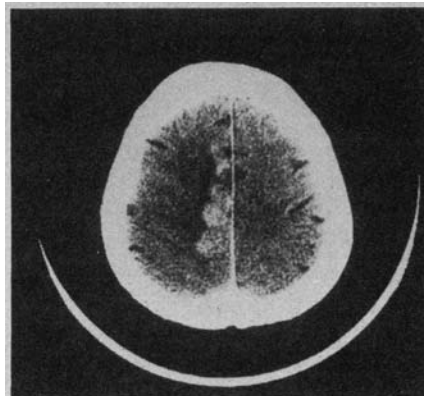


Fig 5.—Computerized tomography scan with contrast enhancement demonstrates a marked high-density area along medial aspect of left hemisphere, surrounded by low-density area.

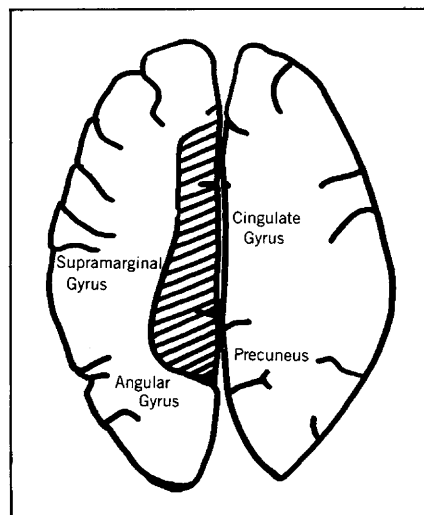


Fig 6.—Schematic representation of Fig 5. Hatched area represents extent of infarction.

because of graphic complexity.

Thus, the patient showed poor performance of the right hand in identifying Kana and numbers. But the lack of aphasic features in the errors seems to distinguish this performance from the poor naming of objects held in the left hand. This is very probably due to impairment of the discriminative sense of the right hand and may be attributable to a possible left parietal lobe lesion.

Computerized Tomography

Computerized tomography (CT) scan showed a low-density area in the parasagittal region of the left hemisphere. The lesion showed enhancement with contrast. There was no deviation of the ventricular system. The lesion most probably involved part of the cingulate gyrus, the paracentral lobule, and the precuneus of

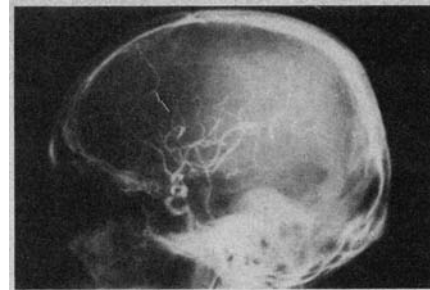


Fig 7.—Left carotid arteriogram demonstrates occlusion of left pericallosal artery (white arrowhead).

the left hemisphere. The state of the corpus callosum could not be discerned from the CT scan but it is possible that the structure was involved.

A left carotid arteriogram showed diffuse sclerotic change of the intracranial arteries. The anterior cerebral artery showed stenosis of a modest degree at its origin from the internal carotid artery, and the pericallosal artery was occluded just after the callosomarginal artery branched off. A right brachial arteriogram showed the same diffuse sclerotic change of the intracranial arteries as the other side. The right anterior cerebral artery was not visualized from its origin. The peripheral portion of the right anterior cerebral artery territory was partially visualized by collaterals from the middle cerebral artery.

It was concluded from these findings that the lesion responsible for the symptomatology of the present case was produced by infarction of the territory supplied by the left pericallosal artery. Other areas of the brain were intact, despite sclerotic change of the intracranial arteries.

COMMENT

Foix and Hillemand⁴ classified the anterior cerebral artery syndrome into three subtypes: simple crural monoplegia, hemiplegia with predominant crural involvement, and crural monoplegia (or predominantly crural hemiplegia) with left-sided unilateral ideomotor apraxia. The third type, which has a callosal lesion, is most relevant to the present discussion, although apraxia was absent in our case. Reported cases of this type of anterior cerebral artery syndrome are few. Foix and Hillemand collected three autopsy verified cases of the third type^{2,7,18} and added another of their own. Critchley in 1930 added two more cases from the literature.¹ But reports of such cases have almost disappeared from the literature since then. Only Sweet¹⁹ reported a case of aneurysm of the anterior cerebral

artery with this type of symptoms. In the 1960s, interest was revived by Geschwind and Kaplan,^{10,11} but even after their work, reports of the syndrome have been very rare. The case reported by Balaceanu et al in 1970²⁰ is perhaps the only one.

The left-sided agraphia in the present case had some interesting features that were manifested by clumsiness, production of occasional unintelligible scribbles, substitution of letters, displacement of letter order, neologistic letter formation, and superior performance of Kanji writing over Kana. The patient could also copy letters well. These symptoms cannot be explained as a partial symptom of apraxia, as has been repeatedly attempted, because the present case had no accompanying ideomotor apraxia of the left side. On the other hand, all of the features enumerated are essentially the same as those usually observed in agraphia of aphasic patients. Dissociation of Kanji and Kana writing of this kind is a characteristic phenomenon found in some types of Japanese aphasics.^{21,22} This finding is in accordance with Geschwind and Kaplan's observation¹⁰ as well as Bogen's.¹⁴

This type of agraphia is aphasic in nature but cannot be identified with aphasic agraphia. In our patient, the left hemisphere speech zone was not affected and aphasia in the strict sense was not present. The essential mechanism lay in the failure of transmission of the programs of writing from the left speech hemisphere to the right hemisphere across the corpus callosum. Thus, as Geschwind suggested,¹¹ it would be appropriate to call this type of agraphia "disconnection agraphia," to emphasize the dissociative nature of the disturbance.

Apart from writing, the patient responded well and without signs of apraxia to various tasks involving the left hand. Why should this happen? According to Geschwind,^{11,23} callosal fibers responsible for praxis probably arise from the motor association cortex of one hemisphere and terminate in the same area of the other hemisphere. These fibers are concentrated in the anterior portion of the corpus callosum. The absence of left-sided apraxia in our patient might be due to sparing of the anteriormost part of the callosum, since the portion of the pericallosal artery thought to serve this region was visualized, as already mentioned. Sugishita and others²⁴ reported a remarkable case in relation to the independence of left agraphia from left ideomotor apraxia.

Their patient underwent an operation for an arteriovenous malformation of the corpus callosum. Part of the posterior half of the trunk of the callosum was coagulated, and about 2 cm was subsequently sectioned. The patient was left with isolated left agraphia without other neuropsychological abnormalities. The agraphia was characterized by aphasic errors only. This case and ours suggest the existence of independent functional channels of linguistic information for writing from channels of linguistic information for other motor performance within the corpus callosum.

The difficulties in naming objects placed in the left hand observed in the present case were aphasic in nature. The linguistic nature of this left-sided difficulty was again made clear by Geschwind and Kaplan¹⁰ for the first time and has since been confirmed by many workers, especially by the observation of commissurotomy patients^{12,13,15} and tumor patients.¹⁶ Balaceanu's patient also had similar difficulty.²⁰ In the present case as well as in these cases, tactile recognition itself was not impaired, nor was speech mechanism affected. The patients' abnormal responses are a manifestation of failure of tactile infor-

mation of the right hemisphere to reach the intact speech mechanism of the left hemisphere across the corpus callosum. Thus the left speech hemisphere tries to fill this information blank by confabulation or by repeating a previous response (perseveration). This is an associative difficulty, a failure to name because no stimulus to naming reaches the left hemisphere. Here also "disconnection tactile naming deficit" would be a more accurate term.

In summary, our patient apparently had a purely linguistic disconnection syndrome that was represented by difficulty of the left hand in coordinating linguistic information. This disconnection agraphia and disconnection naming deficit can be explained as a result of a callosal lesion that disturbs the flow of linguistic information from the left hemisphere speech area to the right hemisphere. Transfer of other motor, auditory, and visual information between the two hemispheres seemed to be grossly undisturbed.

Norman Geschwind, MD, Department of Neurology, Harvard Medical School, aided us considerably in highlighting the issues involved and in correcting the text. We are extremely grateful for his invaluable help.

References

1. Critchley M: The anterior cerebral artery and its syndromes. *Brain* 53:120-165, 1930.
2. Liepmann H, Maas O: Fall von linksseitiger Agraphie und Apraxie bei rechtseitiger Lähmung. *J Psychol Neurol* 10:214-227, 1907.
3. Liepmann H: Die linke Hemisphäre und das Handeln, in *Drei Aufsätze aus dem Apraxiegebiet*. Berlin, S Karger, 1908.
4. Foix C, Hillemand P: Les syndromes de l'artère cérébrale antérieure. *Encéphale* 20:209-232, 1925.
5. Van Vleuten CF: Linksseitige motorische Apraxie. *Allg Z Psychiatr* 64:203-239, 1907.
6. Hartmann F: Beiträge zur Apraxielehre. *Monatsschr Psychiatr Neurol* 21:97-118, 248-270, 1907.
7. Goldstein K: Zur Lehre von der motorischen Apraxie. *J Psychol Neurol* 11:169-187, 270-283, 1908.
8. Goldstein K: Der makroskopische Hirnbefund in meinem Falle von linksseitiger motorischer Apraxie. *Neurol Centralbl* 28:898-906, 1909.
9. Hoff F: Balkentumor mit linksseitiger Astereognosie und Apraxie. *Dtsch Z Nervenheilkd* 123:89-100, 1931.
10. Geschwind N, Kaplan E: A human cerebral disconnection syndrome. *Neurology* 12:675-685, 1962.
11. Geschwind N: Disconnection syndromes in animals and man. *Brain* 88:237-294, 585-644, 1965.
12. Gazzaniga MS, Bogen JE, Sperry RW: Some functional effects of sectioning the cerebral commissures in man. *Proc Natl Acad Sci* 48:1765-1769, 1962.
13. Gazzaniga MS, Sperry RW: Language after section of the cerebral commissures. *Brain* 90:131-148, 1967.
14. Bogen JE: The other side of the brain: 1. Dysgraphia and dysopia following cerebral commissurotomy. *Bull Los Angeles Neurol Soc* 34:73-105, 1969.
15. Sperry RW, Gazzaniga MS, Bogen JE: Interhemispheric relationships: The neocortical commissures; syndromes of hemisphere disconnection, in Vinken PJ, Bruyn GW (eds): *Handbook of Clinical Neurology*. Amsterdam, North Holland Publishing Co, 1969, vol 4, pp 273-290.
16. Brion S, Jedynak CP: Troubles du transfert interhémisphérique (callosal disconnection). *Rev Neurol* 126:257-266, 1972.
17. Rubens AB, Geschwind N, Mahowald MW, et al: Posttraumatic cerebral hemispheric disconnection syndrome. *Arch Neurol* 34:750-755, 1977.
18. Claude H, Loyez M: Etude anatomique d'un cas d'apraxie avec hémiplegie droite et cécité verbale. *Encéphale* 8:289-307, 1913.
19. Sweet WH: Seeping intracranial aneurysm simulating neoplasm. *Arch Neurol Psychiatr* 45:86-104, 1941.
20. Balaceanu C, Gheorghiu M, Lupu A, et al: Syndrome de dysconnexion interhémisphérique dans un cas de thrombose du tronc artériel brachio-céphalique. *Rev Neurol* 123:44-48, 1970.
21. Sasanuma S, Fujimura O: Selective impairment of phonetic and non-phonetic transcription of words in Japanese aphasic patients: Kana vs kanji in visual recognition and writing. *Cortex* 7:1-18, 1970.
22. Sasanuma S, Fujimura O: An analysis of writing errors in Japanese aphasic patients: Kanji versus kana words. *Cortex* 8:265-282, 1972.
23. Geschwind N: The apraxias: Neural mechanisms of disorders of learned movement. *Am Sci* 63:188-195, 1976.
24. Sugishita M, Yamada R, Yoshioka M: Agraphia of the left hand after section of the posterior half of the trunk of the corpus callosum. *Clin Neurol* 15:218-225, 1975.