

## References

1. Jones HR Jr, Millikan CH: Temporal profile (clinical course) of acute carotid system cerebral infarction. *Stroke* 7: 64-71, 1976
2. Millikan CH, Siekert RG, Whisnant JP: The clinical pattern in certain types of occlusive cerebrovascular disease. *Circulation* 22: 1002-1010, 1960
3. Kubik CS, Adams RD: Occlusion of basilar artery — clinical and pathological study. *Brain* 69: 6-121, 1946
4. Millikan CH, Siekert RG: Studies in cerebrovascular disease: syndrome of intermittent insufficiency of basilar arterial system. *Mayo Clin Proc* 30: 61-68, 1955
5. Siekert RG, Millikan CH: Studies in cerebrovascular disease: some clinical aspects of thrombosis of basilar artery. *Mayo Clin Proc* 30: 93-100, 1955
6. McDowell FH, Potes J, Groch S: The natural history of internal carotid and vertebral-basilar artery occlusion. *Neurology (Minneapolis)* 11 Pt 2: 153-157, 1961
7. Williams D, Wilson TG: The diagnosis of the major and minor syndromes of basilar insufficiency. *Brain* 85: 741-774, 1962
8. Fields WS, Ratnov G, Weibel J, et al: Survival following basilar artery occlusion. *Arch Neurol* 15: 463-471, 1966
9. Archer CR, Horenstein S: Basilar artery occlusion: clinical and radiologic correlation. *Stroke* 8: 383-390, 1977
10. Caplan LR, Rosenbaum AE: Role of cerebral angiography in vertebrobasilar occlusive disease. *J Neurol Neurosurg Psychiatry* 38: 601-612, 1975
11. Caplan LR: Occlusion of the vertebral or basilar artery: follow up analysis of some patients with benign outcome. *Stroke* 10: 277-282, 1979
12. Fogelholm R, Aho K: Characteristics and survival of patients with brain stem infarction. *Stroke* 6: 328-333, 1975
13. Mayo Clinic Section of Neurology: *Clinical Examination in Neurology*. 2nd ed, Philadelphia, W B Saunders Co, 1963, p 145
14. Peterman AF, Siekert RG: The lateral medullary (Wallenberg) syndrome: clinical features and prognosis. *Med Clin North Am* 44: 887-896, 1960
15. Leirich JR, Winkler GF, Ojemann RG: Cerebellar infarction with brain stem compression: diagnosis and surgical treatment. *Arch Neurol* 22: 490-498, 1970
16. Sybert GW, Alvord EC Jr: Cerebellar infarction: a clinicopathological study. *Arch Neurol* 32: 357-363, 1975
17. Whisnant JP, Cartledge NEF, Elveback LR: Carotid and vertebral-basilar transient ischemic attacks: effect of anticoagulants, hypertension, and cardiac disorders on survival and stroke occurrence — a population study. *Ann Neurol* 3: 107-115, 1978
18. Marshall J: The natural history of transient ischaemic cerebrovascular attacks. *Q J Med* 33: 309-324, 1964
19. Mohr JP, Caplan LR, Melski JW, et al: The Harvard Cooperative Stroke Registry: a prospective registry. *Neurology (Minneapolis)* 28: 754-762, 1978
20. Cartledge NEF, Whisnant JP, Elveback LR: Carotid and vertebral-basilar transient cerebral ischemic attacks: community study, Rochester, Minnesota. *Mayo Clin Proc* 52: 117-120, 1977

# Bilateral Nothnagel Syndrome

## Clinical and Roentgenological Observations

IRAJ DERAKHSHAN, M.D., MANUCHEHR SABOURI-DEYLAMI, M.D.,  
AND BENJAMIN KAUFMAN, M.D.

**SUMMARY** The clinical features of a patient with bilateral oculomotor palsy, ataxia, disturbance of memory, and hypokinesia are described. Pneumography and CT scanning showed dilation of the posterior portion of the third ventricle, indicating involvement of the postero-medial thalamic structures. The relation of this finding to the patient's amnesia and hypokinesia is briefly discussed. It is concluded that the patient suffered an infarction within the region served by penetrating branches which arise from the cephalad end of the basilar artery, probably including the mesencephalic artery.

*Stroke*, Vol 11, No 2, 1980

ACUTE BILATERAL THIRD NERVE palsy of midbrain origin is rare. This report concerns the clinical features of a patient who had sudden development of bilateral ophthalmoplegia due to bilateral third nerve paralysis, ataxia, hypokinesia, and memory disturbance. The patient was studied with computerized tomography (CT), pneumoencephalography, and angiography.

From the Department of Neurology, Dariush-Kabir Medical School, Tehran University (Dr. Derakhshan), Department of Radiology, Reza Pahlavi Hospital (Dr. Sabouri-Deylami) Tehran, Iran, and Department of Radiology, University Hospitals of Cleveland (Dr. Kaufman), Case Western Reserve University, Cleveland, OH.

Reprints: Dr. Derakhshan, Dept. Neurology, University of Cincinnati Medical Center, 231 Bethesda Ave., Cincinnati, OH 45267.

The patient was a 50-year-old farmer, previously in good health. Following the acute onset of vertigo and vomiting (lasting 1 to 2 hours) he became unresponsive and remained so for about 48 hours. Upon regaining consciousness, he was unable to open his eyes or to keep his balance while walking. Vomiting and vertigo did not recur. There was no history of fever, trauma or headache. He was admitted to Dariush-Kabir Hospital (Tehran, Iran) 4 months after the episode. According to family members, he had lost control of urination 3 weeks prior to admission. Otherwise, there had been no change in his condition.

On repeated examinations he was alert and oriented to person and place but not to the date. He knew what season it was but could not remember or retain any new information such as the date or the name of the

hospital. Past memory was intact and he could recognize his family and close relatives. He could not do simple arithmetic. His judgment was intact, as was his awareness of his disabilities. He was calm but slow in responding to verbal inquiries. He would sit in bed, eyes closed for hours, uncomplaining. When he was lying in bed, it was difficult to ascertain whether he was awake or asleep as he was unable to open his eyes. His blood pressure and general physical examination were unremarkable. His speech was slurred but he did not have dysphasia. Visual fields were normal in both eyes on confrontation testing and bilateral simultaneous stimulation. His optic fundi were normal. Bilateral complete third nerve palsy was evident as both eyes were abducted to the extremes (fig. 1). There was a sustained horizontal nystagmus when he looked at an object at the extreme right or left. No other ocular movement was possible, either voluntarily or by changes in head position. His pupils were round and unequal (right 5 mm, left 3.5 mm). Both pupils were non-reactive to light and accommodation. Caloric testing with ice water induced appropriate nystagmus in the ipsilateral eye with only occasional (and irregular) participation of the other eye which retained its original (abducted) position. Bilateral simultaneous caloric testing with ice water failed to induce any change in eye position. The remaining cranial nerves functioned normally.

Motor and sensory examination revealed no abnormality. Stereognosis and 2-point discrimination tests were normal. Finger-to-nose and heel-shin tests elicited an intention tremor. His gait was ataxic, wide-based, and lurching. All tendon reflexes were present and normal and plantar reflexes were flexor. He had urinary incontinence. Ten days after admission he suffered a right-sided stroke with mild hemiparesis and motor aphasia from which he recovered. No other changes developed in 2 months of hospitalization.

Complete hemogram, glucose tolerance test (4 hour), serum cholesterol, blood urea nitrogen, complete evaluation for collagen diseases, liver function tests, serum VDRL, and electrocardiogram were all normal. Cerebrospinal fluid cell count, VDRL, protein and glucose contents were also normal. Eight-

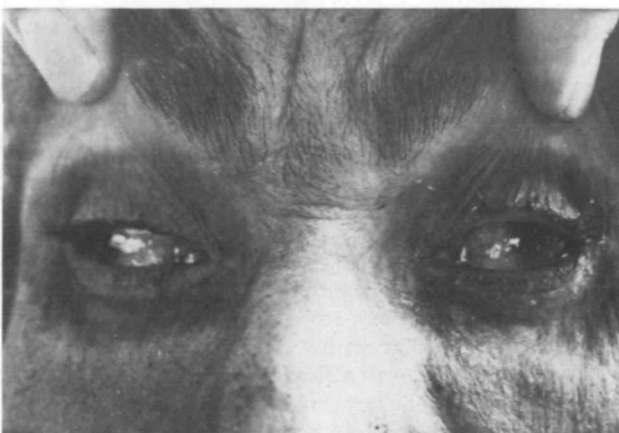

FIGURE 1. Depicts the patient's divergent strabismus.

channel electroencephalography (on 2 occasions) showed a normal pattern with a well-organized and well-developed 7-8 cycle/sec activity. On vertebral angiography an area of narrowing of the right vertebral artery was observed and interpreted as due to atheromatous disease. Pneumoencephalography showed widening of the posterior portion of the third ventricle (fig. 2), and widening of the third ventricle was corroborated by CT scan. Neither of the latter 2 tests showed cortical atrophy.

### Comment

The association of unilateral oculomotor palsy of midbrain origin with contralateral ataxia is referred to as the Nothnagel Syndrome.<sup>1,2</sup> Historically, this is based on Nothnagel's remark in 1879 in a review of clinico-pathological data (available to him and reported by others) of lesions involving corpora quadrigemina.<sup>2</sup> The following is a translation of Nothnagel's concluding remarks pertaining to the title of the present article:

"Bilateral, symmetrical lesions of specific branches of the oculomotorius indicates involvement of lamina quadrigemina, especially if there is no concomitant alternate paralysis of extremities. . . . It appears that with lesions of posterior gemini there are disturbances of balance and coordination

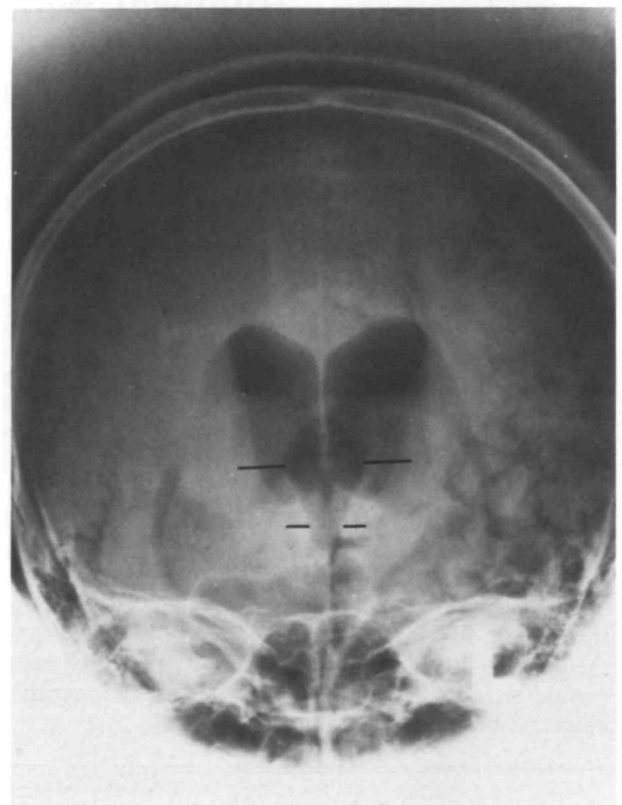


FIGURE 2. Pneumoencephalography, antero-posterior view. The upper and lower bars delineate posterior and anterior diameters of the third ventricle, respectively. Widening of the posterior portion of the third ventricle is evident.

which are very similar to those seen with lesions of the cerebellum. However, this point is not indisputable."

The close proximity of the oculomotor nuclear complex to the dendato-rubro-thalamic fibers (within the midbrain tegmentum) constitutes the accepted anatomic basis of this semeiological association (see below). Detailed clinical descriptions of this syndrome are rare, partly due to the rarity of its occurrence. Kubik and Adams<sup>3</sup> reported 2 patients with partial bilateral third nerve palsy of mesencephalic origin due to infarction. Anderson and Jaros<sup>4</sup> briefly described the clinico-pathological findings of one patient in their discussion of a series of 35 patients with vertebro-basilar disease. Masucci's<sup>5</sup> series consisted of 6 patients but bilateral oculomotor palsy was incomplete in all of his patients and ataxia was present (or mentioned) in 2 patients. The corticospinal tract was involved in all but one patient but pathologic data were not available. Memory function was not specifically described in any of the above reports.

More recently, Shutt, David and Smith<sup>6</sup> reported the clinical findings of 2 patients with "complete" bilateral third and fourth nerve palsy of vascular cause. Judging from the photographs, however, their second patient seems to have retained some function of both medial rectus muscles. Both patients had ataxia, dysarthria and amnesia and the latter symptoms apparently lasted only a few days. The nature of memory disturbance in these 2 patients was not described. Contrast studies were not performed on these patients.

Although the occurrence of cortical cerebellar damage in our patient remains a possibility, the cerebellar findings can also be explained by tegmental midbrain damage. Partial ophthalmoplegia, ataxia and dysarthria in the absence of a cerebellar lesion, has been reported in patients with vascular lesions involving the region under consideration.<sup>7-9</sup> The probable pathologic basis of such an association was mentioned above.

The memory disorder in the present case was predominantly that of retaining (or recalling) recent information, indicating possible additional involvement of thalamic structures.<sup>10</sup> Pathogenesis of hypokinesia and memory disturbances, with or without an associated eye movement disorder, has been recently reviewed.<sup>11</sup> Bilateral involvement of dorsomedial thalamic nuclei and periaqueductal gray matter appeared to be the area of the brain commonly involved in these patients.

Dilatation of the posterior third ventricle, shown by

pneumoencephalography, was present in our patient and was confirmed by CT scanning. The latter finding is consistent with involvement of the dorsomedial thalamus. The sudden onset (preceded by vertigo and vomiting) and the angiographic finding both point to a probable cerebral infarction. The location of the ischemic insult falls within the region supplied by the median (penetrating) branches of the basilar artery arising from its cephalad end, probably including the mesencephalic artery.<sup>12</sup>

In the absence of pathological data, comments regarding the nystagmus and urinary incontinence remain hypothetical. The occurrence of nystagmus in the presence of an apparently complete third nerve palsy can be explained by phasic contraction, followed by relaxation, of the unopposed lateral rectus muscle in each eye. The urinary incontinence was difficult to ascribe to the presence of a lacunar state in the absence of spasticity, gagenhalten or other pseudo-bulbar findings. Based on the pervading hypokinesia, reflected by the patient's verbal and nonverbal behavior, it was our belief that the incontinence was probably due to the patient's inability to voice his needs.

## References

1. Duke-Elder S, Scott GI: Ocular dissociations. *In* System of Ophthalmology, St. Louis, CV Mosby Co, 12: 741-745, 1971
2. Nothnagel H: Corpora Quadrigemina. *In* Gehirnkrankheiten, Eine Klinische Studie, Berlin, Verlag Von August Hirschwald, 204-220, 1879
3. Kubik CS, Adams RD: Occlusion of the basilar artery: A clinical and pathological study. *Brain* 69: 73-121, 1946
4. Anderson WW, Jaros RM: Basilar artery disease: Clinical manifestations. *Calif Med* 92: 400-402, 1960
5. Masucci EF: Bilateral ophthalmoplegia in basilar-vertebral artery disease. *Brain* 88: 97-106, 1965
6. Shutt HKR, David MJ, Smith JL: Complete bilateral III and IV nerve palsies due to basilar artery disease. *In* Smith JL (ed) Neuro-ophthalmology: Symposium of the University of Miami and the Bascom Palmer Eye Institute. Hallendale, FL: Huffman, 5: 356-362, 1971
7. Cogan DG: Paralysis of downgaze. *Arch Ophthalmol* 91: 192-199, 1974
8. Jacobs L, Anderson PG, Bender MB: The lesion producing paralysis of downward but not upward gaze. *Arch Neurol* 28: 319-323, 1973
9. Reagan TJ: Combined nuclear and supranuclear defects in ocular motility: A clinico-pathologic study. *Arch Neurol* 35: 133-137, 1978
10. Victor M, Adams RD, Collins GH: The Wernicke-Korsakoff syndrome. Philadelphia, FA Davis Co, 132-133, 1971
11. Mills RP, Swanson PD: Vertical oculomotor apraxia and memory loss. *Ann Neurol* 4: 149-153, 1978
12. Segarra JM: Cerebrovascular disease and behaviour. 1-The syndrome of the mesencephalic artery. *Arch Neurol* 22: 408-418, 1970