

NEGLECT FOLLOWING DAMAGE TO FRONTAL LOBE OR BASAL GANGLIA

ANTONIO R. DAMASIO, HANNA DAMASIO and HELENA CHANG CHUI

Department of Neurology,
(Division of Behavioral Neurology and Benton Laboratory of Neuropsychology),
University of Iowa College of Medicine

(Received 27 September 1979)

Abstract—Though neglect is often thought to be a sign of parietal lobe damage, particularly of the non-dominant hemisphere, there is evidence that lesions in the frontal lobes and in the basal ganglia can produce neglect also. We present five patients, with lesions in both the mesial and dorsolateral aspects of the frontal lobe, and in the basal ganglia, as examples of "non-parietal" neglect. It is possible that all of these structures belong to an anatomically interconnected system subserving selective attention and that lesions in each of the components are capable of producing neglect although with slightly different characteristics.

THE presence of neglect is usually considered a sign of parietal lobe dysfunction and the finding of left sided neglect is almost synonymous with right parietal damage. Yet HEILMAN and VALENSTEIN [1] have described the presence of neglect in association with frontal lobe lesions, in a report which included six cases with circumscribed lesions of the right frontal lobe, three of which were located in the mesial aspect and the other three in the lateral convexity. All patients had right sided lesions thus leaving unanswered the question of whether left frontal lobe lesions might fail to produce the phenomenon as is generally the case with the parietal lobe.

For a number of years we have seen several instances of neglect in association with lesions of the frontal lobe in either hemisphere and, in addition, of the basal ganglia. This report exemplifies the condition and emphasizes the association of left frontal damage with unilateral neglect.

MATERIALS AND METHOD

Five patients in whom neglect was a prominent manifestation, and in whom a cerebral lesion could be localized by means of CT scan (four cases) or radionuclide scan (one case), were studied. The working concept of unilateral neglect encompassed such manifestations as visual, auditory or tactile inattention, as well as lateralized akinesia (of the hemiface or of limbs of one side of the body). The localization of the lesions seen in CT scans was made according to a method described by DAMASIO and DAMASIO [2, 3] in which images of abnormal density are plotted in templates of brain sections corresponding to the planes of cut of CT scan and the results read as a three-dimensional construct.

The evaluation of neglect was made by clinical means at the bedside, and completed in a laboratory setting using a visual cancellation task [4]. The patient was instructed to cross 94 lines in various orientations approximately 2 cm in length presented with a 17 × 15 cm area centered on a standard 8½ × 11 in. white card. Four lines, one in each corner, served as demonstration items. The remaining 90 lines were distributed in 9 columns of 10 lines each with 5 lines of each column appearing above and below the horizontal meridian. There were no other marks on the page. The examiner placed the stimulus page in front of the patient with the long edge of the paper aligned in parallel and centered on the patient's mid-sagittal plane. A score of one was given for each line crossed. Also, credit was given for any mark which touched a stimulus

Table 1.

	Location of lesion	Side neglected
Case 1	Left frontal (dorsolateral)	Right
Case 2	Left frontal (mesial)	Right
Case 3	Left frontal (mesial)	Right
Case 4	Right basal ganglia	Left
Case 5	Left basal ganglia	<i>Left</i>

line. Total score was the number of lines crossed. This score was subdivided into left, center and right field scores by counting the number of points in the three left, center and right columns, respectively, making this task similar, though more complex, than the one described by ALBERT [5]. Table 1 summarizes the data for the cases. Details are elaborated below.

Case 1. GG is a 74-yr-old right-handed woman with a high school education. In December 1978 she suffered a stroke which left her fully alert and with good aural comprehension but unable to speak. She retained full use of her limbs, readily produced meaningful gestures with both upper extremities and attempted to write on a pad only to discover she merely produced a scribble. Other than her mute, but not akinetic state, the most remarkable clinical finding was neglect of the right half of her surrounding space manifested by (a) inattention to visual and auditory stimuli presented to her right side, (b) paucity of visual saccades towards the right, (c) defective performance in a visual neglect test (Fig. 1). Neglect improved dramatically over a period of 10 days. During the same period mutism was followed by Broca's and then transcortical motor aphasia.

The lesion involved the dorsolateral frontal lobe on the left side (Fig. 2). The focus of damage included areas 44 and 45, area 46, area 6 and the associated underlying white matter. The area of edema extended into the basal ganglion region. Prefrontal areas 9 and 10 and the mesial part of area 6 were spared.

Case 2. JC is a 35-yr-old right-handed female who suffered an embolic stroke in May 1977. She became mute immediately and markedly akinetic though appearing alert. Her right leg and foot were paralyzed. For the ensuing 3 days, although no spontaneous speech was recorded, it became apparent that the patient could repeat elaborate sentences, and could read and understand complex speech. It also was noted that the initial global akinesia was now more prominent in the face and right upper extremity (both had full strength in hard to elicit voluntary maneuvers) and that the patient was inattentive to visual and auditory stimuli presented from the right. A visual neglect test showed defective performance which subsequently improved. The clinical signs of neglect however, persisted longer and their improvement, around 2 weeks post-onset, paralleled improvement in spontaneous speech.

The lesion, located in the territory of the left anterior cerebral artery, in all likelihood involved the supplementary motor area, anterior cingulate gyrus and leg region of the motor cortex.

Case 3. MM is a 60-yr-old right-handed artist, who in 1978 underwent resection of a single metastasis of adenocarcinoma located in the left mesial frontal cortex (Fig. 3). As a result, she sustained damage to the supplementary motor area, the leg region of area 4, the superior portion of the anterior cingulate gyrus and to the white matter underlying these areas. Immediately after surgery she was akinetic and mute but during the ensuing weeks her clinical status evolved in much the same manner as that of patient JC (Case 2). Her global akinesia focused on the right side and face and there was clear neglect of visual and auditory stimuli presented to the left side. At a slower pace than in patient JC the neglect cleared and some spontaneity of speech and general movement was regained.

Case 4. CC is a 60-yr-old right-handed woman who suffered a stroke in September of 1978. For approximately 1 day she was somnolent though arousable and fully oriented. Speech was linguistically intact but dysprosodic and dysarthric. After the third day comprehensive testing was possible and it was noted that the patient had little spontaneous movement or speech, and, in addition, systematically neglected stimuli presented on her left side. A visual cancellation task revealed defective performance, although this improved over a period of 7 days (Fig. 4).

The lesion (see Fig. 5) was located in the right medial basal ganglion region, and involved the right putamen, body of the caudate nucleus, and portions of the internal capsules (anterior and posterior limbs).

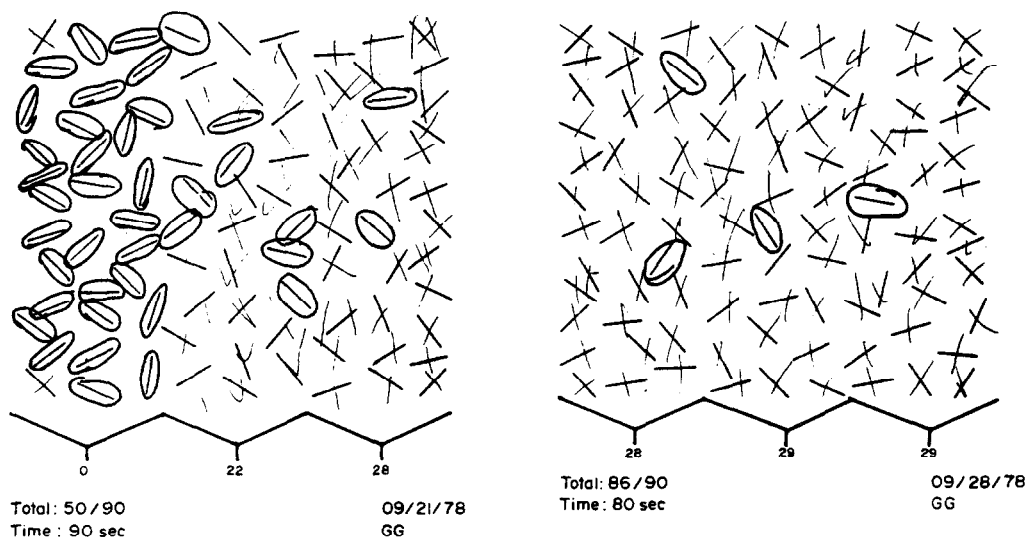


FIG. 1. Case 1. Performance in visual cancellation task at time of first exam (left) and on re-evaluation (right).

Case 5. BF is a 46-yr-old right-handed woman with a personal and familial history of manic-depressive illness and the history of a stroke event 2 yr prior to admission. Treatment took place in a different institution and though it was not possible to obtain details, the disease rendered her "confused and paralyzed on the right side" for a long period of time with gradual recovery. Admission to our department in 1977 was prompted by the finding of severe left-sided visual neglect in a routine clinic visit. Although examination of the patient was difficult due to her disturbed emotional status (manic phase), it was clear that she systematically failed to attend stimuli presented to her left hemispace (to the extent that she was erroneously thought to have a left hemianopia). In addition she had a tendency for left turning immediately after she initiated walking even though urged to follow a straight line. Additionally, her right upper extremity was relatively less used than the left, though not paralyzed or entirely neglected.

A CT scan revealed a circumscribed area of low density in the left basal ganglion region. It involved the head of the left caudate, nucleus as well as the surrounding white matter, including the anterior limb of internal capsule and the anterior part of the putamen. It is likely that this represented the result of resolution of an old infarction (Fig. 6).

DISCUSSION

In view of experiments in non-human primates, it should not be surprising to find neglect in association with non-parietal lesions. WELCH and STUTTEVILLE [6] were able to produce unilateral neglect by placing lesions in area 8 of the frontal lobe in the rhesus monkey. Also in the monkey, WATSON *et al.* [7] obtained neglect after unilateral damage to the anterior cingulate gyrus but not the supplementary motor area, and they have, in addition, produced neglect with unilateral lesions placed in the mesencephalic reticular formation [8]. Damage to the basal ganglia confined to one hemisphere has also produced neglect associated with turning behavior [9] and finally, unilateral lesions of the lateral hypothalamus in the rat have produced neglect also [10, 11].

Integrating these various findings HEILMAN [12] has proposed an animal model of neglect encompassing sensory (e.g. visual or auditory inattention) and motor (e.g. akinesia) components and indicating that the process of attention to each half of the stimulating environment and of the subject's body, calls for the coordinated participation of neocortical (parietal

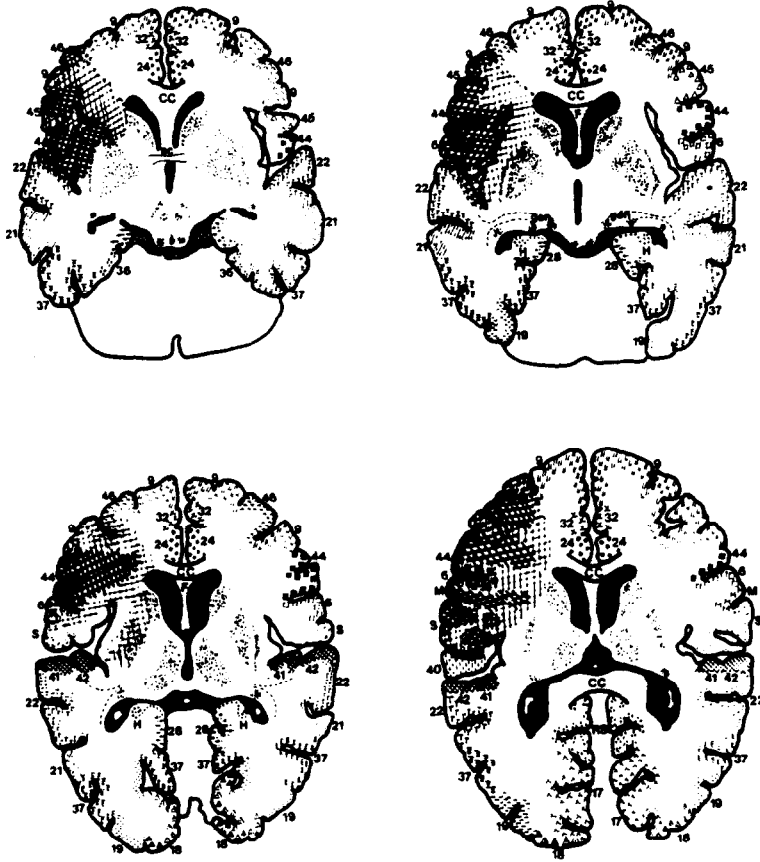


FIG. 2. Case 1. Plotting of CT scan low density images in corresponding templates.

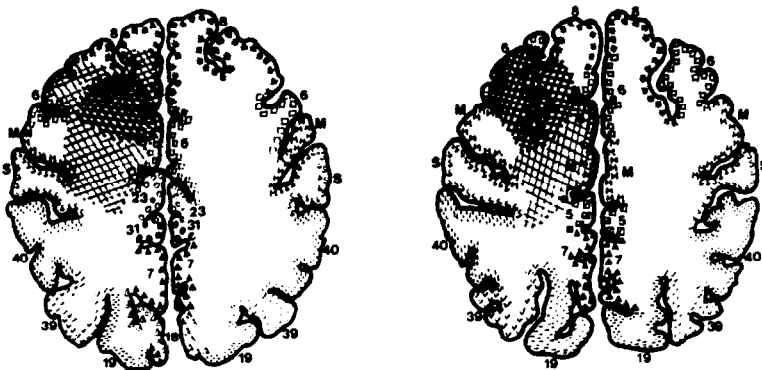

FIG. 3. Case 3. Plotting of CT scan low density images in corresponding templates.

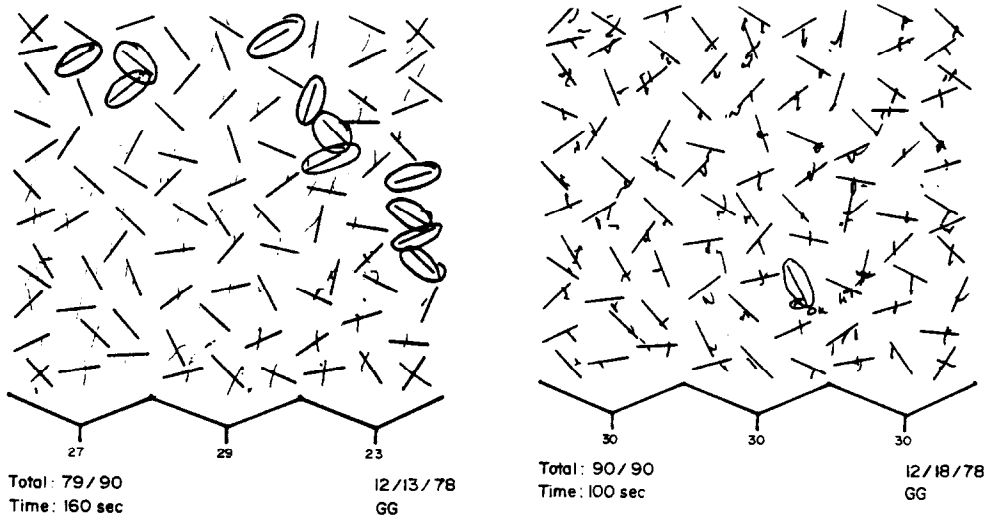


FIG. 4. Case 4. Performance in visual cancellation task at time of first exam (left) and on re-evaluation (right).

and frontal), limbic, and reticular activating neural components. In our version of the model we would add the neostriatum to the aforementioned structures. Our findings support the notion that in man, too, similar components are at work in attentional processes and that the disruption of any of them can produce neglect which will be lateralized or global depending on whether the lesion is unilateral or bilateral.

The lesions in two of our patients affected the crucial mesial frontal cortex (compromising the supplementary motor area, anterior cingulate and their connectivity), in another the lesion was in the dorsolateral frontal lobe cortex which strongly projects to the SMA/cingulate complex; and, in the two remaining patients, lesions were in the basal ganglia (striatum), a region strongly connected to the latter two. In short, two of the structural components of the proposed attention subserving anatomical structures are affected in our cases, failure of each being capable by itself of producing neglect.

It is interesting to note that the neocortical and limbic-cortical structures damaged in our patients are strongly interconnected with area 7 in the parietal lobe, damage of which produces the classically recognized parietal neglect. In addition, following a recently identified principle of cortico-striatal projections it is quite likely that those reciprocally connected cortical structures strongly project in part to the same regions of the striatum [13, 14]. We would suggest that these lesions, which produce neglect in the parietal and frontal cortices as well as in basal ganglia comprise a part of the system subserving attention, with the several components exerting different forms of control depending on their hierarchy and consequently producing different forms of neglect when their function is affected. As an example, unilateral frontal lobe lesions produce neglect for shorter periods than parietal lobe lesions and recovery in both animals [15] and man (cf. our cases) occurs more readily. In man the differences may be particularly pronounced. The longer lasting forms of unilateral neglect are related to lesions of the right parietal lobe while the shorter lasting unilateral neglect following frontal lobe lesions appears after damage to either side. But the

most severe form of neglect is the bilateral akinetic and mute state which follows bilateral mesial frontal lobe damage in man or monkey. Those clinical differences shed some light on the question of the respective roles of parietal and frontal hierarchies in attentional mechanisms.

The cortex of area 7 in the parietal lobe is generally considered the crucial structure as far as selective attentional processes are concerned. In regard to processes of lateralized visual attention and lateralized upper extremity movement, there is little doubt that in animals and man neurons in area 7 constitute a high level guidance system [16–18]. In fact, MOUNTCASTLE [16, 19] views that region and those neurons as containing a “command” mechanism for selective visual attention and visually guided reaching. However, the concept of “command” can be challenged not only on the basis of specific aspects of the data [20, 21] but also because these “command” cells are themselves commanded, e.g. dependent on the “external” control of the limbic system. At least in the case of man those cells are also dependent on a higher executive decision which takes into account complex internal rules and environmental contingencies. It is possible that the latter executive “commands”, as well as part of the limbic ones, come from the SMA/anterior cingulate complex, which receives inputs from the dorsolateral structures of the frontal lobe and from subcortical components of the limbic system. In our view, classical parietal neglect is principally related to damage of area 7, while neglect such as was seen in cases 1, 2 and 3, is the result of damage in two sectors of the frontal lobe which constitute a higher control for the so-called “parietal command device” (its “will”, as it were) and for other parietal lobe regions (such as areas 39 and 40, in all likelihood reduced or absent in the monkey).

The appearance of neglect in relation to lesions of the basal ganglia is seen in man, in moderate form, in disease processes of the striatum such as Parkinson's disease but, it has an animal counterpart also. Unilateral damage of the striatum in rats produces unilateral neglect [9] while bilateral damage leads to an akinetic state of global neglect [22]. In both instances neglect consists of a motor component (akinesia in the side contralateral to the lesion) and a sensory component. In addition, there may be turning behavior towards the side of the lesion and away from the akinetic side [23–25]. Case 5 is an example of this phenomenon which belongs with other interesting manifestations described in Parkinsonism such as postural deviation towards the side of the lesion, in standing or walking [26], or scoliosis with the concavity towards the side of the lesion [27]. The intensity of the phenomenon in patient BF, uncommon in our experience in patients with extrapyramidal disease, was possibly due to the type of lesion, since structures in the head of the caudate nucleus were, in all likelihood, effectively destroyed rather than merely dysfunctional. Finally it is intriguing to find a dissociation between the side neglected for vision and the one neglected for motion. It has been suggested that in some cases of left frontal lobe damage neglect can indeed be ipsilateral to the lesion [28]. Such deviant cases might be related to particular instances of dysfunction, in the basal ganglia rather than in the frontal cortex.

REFERENCES

1. HEILMAN, K. M. and VALENSTEIN, E. Auditory neglect in man. *Arch. Neurol.* **22**, 660–664, 1972.
2. DAMASIO, H. and DAMASIO, A. “Paradoxical” ear extinction in dichotic listening: Possible anatomic significance. *Neurology* **29**, 644–653, 1979.
3. DAMASIO, H., DAMASIO, A., HAMSHER, K. and VARNEY, N. CT scan correlates of aphasia and allied disorders. *Neurology* **29**, 572, 1979.

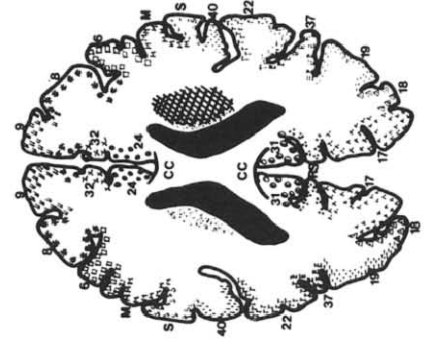
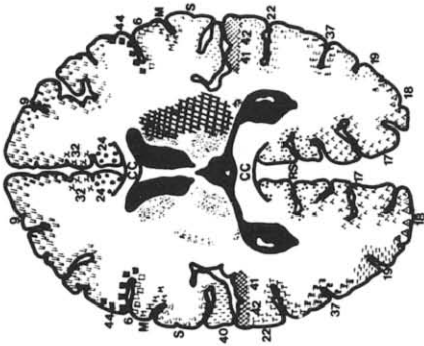
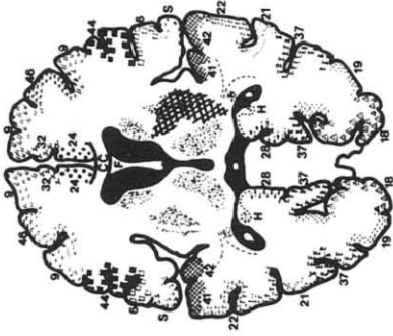
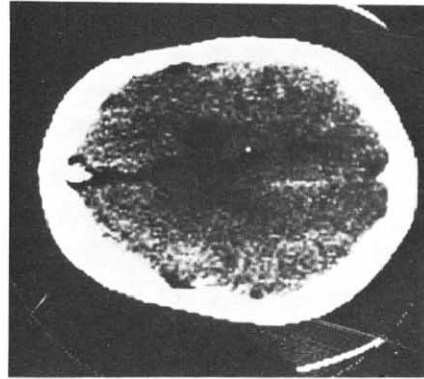
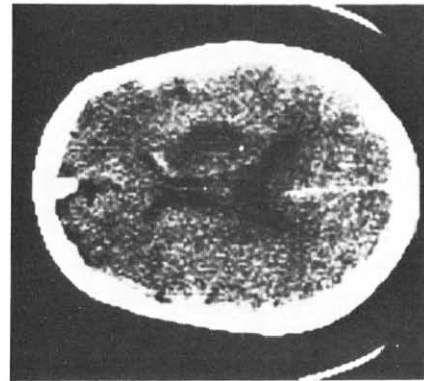
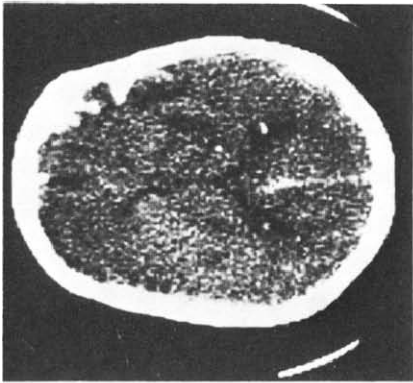


FIG. 5. Case 4. CT scan cuts and plotting of lesion images in corresponding templates.

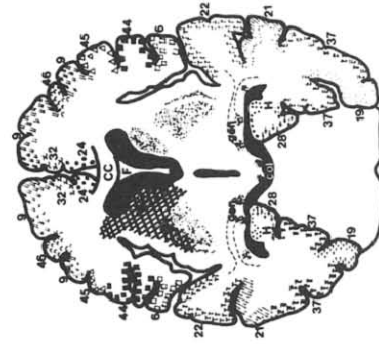
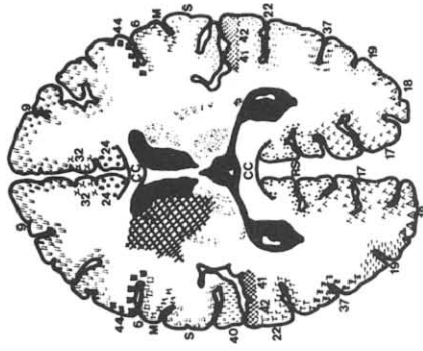
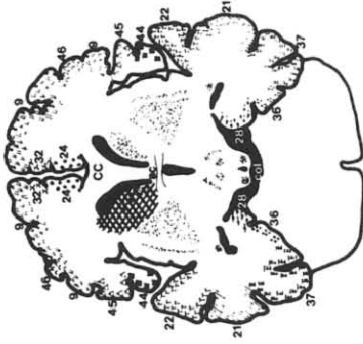
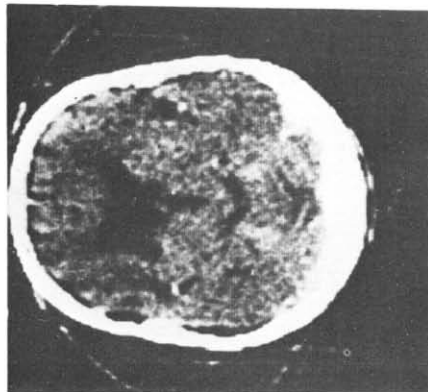
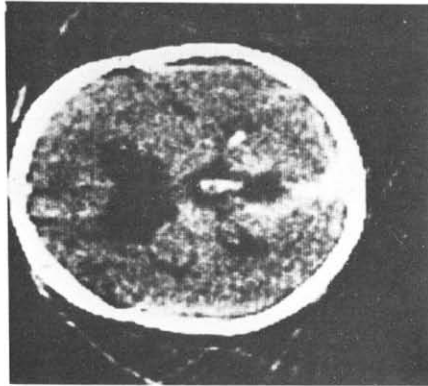
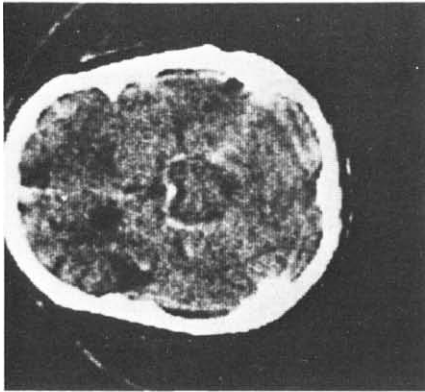


Fig. 6. Case 5. CT scan cuts and plotting of lesion images in corresponding templates.

4. HAMSHER, K. Line Cancellation Test, Department of Neurology, University of Iowa College of Medicine, 1976.
5. ALBERT, M. L. A simple test of visual neglect. *Neurology* **23**, 658–664, 1973.
6. WELCH, K. and STUTEVILLE, P. Experimental production of neglect in monkeys. *Brain* **81**, 341–347, 1958.
7. WATSON, R. T., HEILMAN, K. M., CAUTHEN, J. C. and KING, F. A. Neglect after cingulectomy. *Neurology* **23**, 1003–1007, 1973.
8. WATSON, R. T., HEILMAN, K. M., MILLER, B. D. and KING, F. A. Neglect after mesencephalic reticular formation lesions. *Neurology* **24**, 294–298, 1974.
9. IVERSEN, S. D. Striatal function and stereotyped behaviour. In *Psychobiology of the Striatum*, A. R. COOLS *et al.* (Editors). Elsevier/North-Holland Biomedical Press, New York, 1977.
10. MARSHALL, J. F., TURNER, B. H. & TEITELBAUM, P. Sensory neglect produced by lateral hypothalamic damage. *Science* **174**, 523–525, 1971.
11. MARSHALL, J. F., RICHARDSON, J. S. and TEITELBAUM, P. Nigrostriatal bundle damage and the lateral hypothalamic syndrome. *J. comp. Physiol. Psychol.* **87**, 808–830, 1974.
12. HEILMAN, K. M. and WATSON, R. T. The neglect syndrome—A unilateral defect of the orienting response. In *Lateralization in the Nervous System*, S. HARNAD *et al.* (Editors). Academic Press, New York, 1977.
13. VAN HOESSEN, G. W. and YETERIAN, E. H. A re-evaluation of the cortico-striate projection in the rhesus monkey, Cajal Club, American Association of Anatomists, Miami, 1979.
14. YETERIAN, E. H. and VAN HOESSEN, G. W. Cortico-striate projections in the rhesus monkey: The organization of certain cortico-caudate projections. *Brain Res.* **139**, 43–63, 1978.
15. WATSON, R. T., MILLER, B. D. and HEILMAN, K. M. Nonsensory neglect. *Ann. Neurol.* **3**, 505–508, 1978.
16. MOUNTCASTLE, V. B., LYNCH, J. C., GEORGOPOULOS, A. *et al.* Posterior parietal association cortex of the monkey: command functions for the operations within extrapersonal space. *J. Neurophysiol.* **38**, 871–908, 1975.
17. YIN, T. C. T. and MOUNTCASTLE, V. B. Visual input to the visuomotor mechanisms of the monkey's parietal lobe. *Science* **197**, 1381–1383, 1977.
18. DAMASIO, A. R., BENTON, A. L. Impairment of hand movements under visual guidance. *Neurology* **29**, 170–178, 1979.
19. MOUNTCASTLE, V. B. The world around us: neural command functions for selective attention, *Neurosci. Res. Prog. Bull.* **14**, 1976.
20. GOLDBERG, M. F. and ROBINSON, D. L. Visual mechanisms underlying gaze: Function of the cerebral cortex. In *Control of Gaze by Brain Stem Neurons*, BAKER and BERTHOZ (Editors), Vol. 1. Elsevier/North-Holland Biomedical Press, New York, 1977.
21. ROBINSON, D. L., GOLDBERG, M. E. and STANTON, G. B. Parietal association cortex in the primate: Sensory mechanisms and behavioral modulations. *J. Neurophysiol.* **41**, 910–932, 1978.
22. UNGERSTEDT, U. Selective lesions of central catecholamine pathways: Application in functional studies. In *Neuroscience Research*, Vol. 5, *Chemical Approaches to Brain Function*, S. EHRENPREIS and I. KOPIN (Editors). Academic Press, New York, 1973.
23. METTLER, F. A. and METTLER, C. C. The effects of striatal injury. *Brain* **65**, 242–255, 1942.
24. ANDEN, N. E., DAHLSTROM, A., FUXE, K. and LARSSON, K. Functional role of the nigro-neostriatal dopamine neurons. *Acta Pharmacol. Toxicol.* **24**, 263–274, 1966.
25. UNGERSTEDT, U. Striatal dopamine release after amphetamine or nerve degeneration revealed by rotational behavior. *Acta Physiol. Scand.*, Suppl. **367**, 49–68, 1971.
26. MARTIN, J. P. *The Basal Ganglia and Posture*, pp. 100–105. Pitman, London, 1967.
27. DUVOISIN, R. C. and MARSDEN, C. D. Note on the scoliosis of Parkinsonism. *J. Neurol. Neurosurg. Psychiat.* **38**, 787–793, 1975.
28. SCHWARTZ, A. S., MARCHOK, P. L. and FLYNN, R. E. A sensitive test for tactile extinction: results in patients with parietal and frontal lobe disease. *J. Neurol. Neurosurg. Psychiat.* **40**, 228–233, 1977.

Résumé :

Bien qu'on attribue souvent la négligence aux atteintes du lobe pariétal, particulièrement de l'hémisphère droit, il existe des preuves que les lésions frontales et les lésions des ganglions de la base peuvent aussi produire la négligence. Nous présentons comme exemple de négligence "non pariétale" 5 malades avec lésions frontales internes et dorsolatérales et des ganglions de la base. Il est possible que toutes ces structures appartiennent à un système anatomiquement interconnecté sous tendant l'attention sélective. Il est possible aussi que les lésions de chacune de ces composantes soient capables de produire la négligence bien qu'avec des caractères légèrement différents.

Zusammenfassung

Neglekt wird oft für ein Symptom der Schädigung des Parietallappens, besonders der nicht dominanten Hemisphäre gehalten. Es gibt jedoch Beobachtungen die zeigen, daß auch Läsionen im Frontallappen und in den Stammganglien zu Neglekt führen können. Wir beschreiben 5 Patienten mit Läsionen des medialen und dorso-lateralen Frontallappens und in den Stammganglien als Beispiel für "nicht parietalen" Neglekt. Es ist möglich, daß alle diese Strukturen zu einem anatomisch verbundenen System gehören, welches selektive Aufmerksamkeit vermittelt. Es könnte sein, daß Läsionen in jedem Anteil dieses Systems Neglekt hervorrufen, wenn auch mit geringfügig unterschiedlichen Charakteristika.