

Crossed Aphasia in a Right-handed Bilingual Chinese Man

A Second Case

Robert S. April, MD, Margaret Han, MA

• **A persistent nonfluent aphasia following a right cerebral infarction developed in a 74-year-old right-handed Chinese man. Computerized axial tomography localized the lesion in the right frontal lobe. This case is similar to a previously reported one, also with crossed aphasia in a bilingual and dextral Chinese person. Despite these two independent observations and in spite of the fact that unusual cerebral organization might be related to early learning of a nonalphabetic (ideographic) language, preliminary sampling has failed to demonstrate a greater incidence of crossed aphasia in two separate Chinese populations.**

(*Arch Neurol* 37:342-346, 1980)

A single case of crossed aphasia in a right-handed bilingual Chinese person has been reported.¹ We describe a second, similar patient.

Crossed aphasia in right-handed persons is rare. There are few reports of aphasia in Chinese patients.¹⁻³ Therefore, the cases of crossed aphasia in Chinese persons merit special study. A possible relationship has been suggested between learning to read and write a nonalphabetic language and the development of unusual cerebral organization,¹ a factor that might contribute to this presentation.

REPORT OF A CASE

A 74-year-old right-handed Chinese man worked as a bookkeeper in a Chinese restaurant in New York City. Born in China, he received six years of education in the Cantonese dialect. He learned English after emigrating to the United States at age 20. Although he wrote and spoke Chinese at work and home, he was also able to read and write English before the present illness. His son stated that the patient never wrote grammatically perfect English.

Medical history included treated hypothyroidism, adult-onset diabetes mellitus, and thalassemia minor (low α_2 -hemoglobin level). There was no history of loss of consciousness, focal neurologic signs, car-

diac failure, or psychiatric illness.

The patient lived with his wife, who speaks, reads, and writes Chinese exclusively. The sons, educated in the United States, speak English to each other but Chinese to their parents.

On March 26, 1978, the patient suffered transient loss of consciousness with residual left hemiparesis and inability to speak. The first detailed language examination was performed in another hospital.

After the patient was transferred to St Vincent's Hospital, New York, one of us (R.S.A.) examined him for the first time on April 22, 1978, approximately one month after onset.

Neurologic Examination.—The patient was alert, cooperative, bradykinetic, and mute. There was left hemiparesis, including the face, without hyper-reflexia or Babinski's sign. Knee and ankle tendon reflexes were absent with reinforcement. Confrontation did not reveal visual field loss. The range of gaze movements to the left was less complete than to the right. Face-hand test showed extinction on the left hand when the right side of the face was touched simultaneously. Oral movements were slow, but there was no atrophy of the tongue. Results of the general physical examination were normal except for the presence of a grade 3/6 aortic systolic ejection murmur that radiated to the neck.

Laboratory Studies.—Complete blood count, urinalysis, and blood chemistry study results were normal except for a decreased level of tetraiodothyroxine, elevated levels of thyroid-stimulating hormone, and hyperglycemia. Primary hypothyroidism was treated with exogenous thyroid hormone; diabetes mellitus was treated with diet. Chest and skull roentgenograms were normal. An ECG showed an old anterior infarction pattern. Dynamic radioisotope brain scan revealed decreased perfusion on the right, and a static scan showed an area of increased uptake in the right frontotemporal region. A pure-tone audiogram demonstrated normal thresholds for tones in the speech frequency range. A computerized axial tomogram (CT) scan indicated hemorrhagic infarction in the right frontotemporal region. Two months later, a single hypodense zone in the same location (Fig 1) was interpreted as cystic encephalomalacia in the distribution of a branch of the right middle cerebral artery. Mild cerebral atrophy was present. The computerized densities of the left cerebral hemisphere, position of midline structures, and shape of left lateral ventricle were normal.

EEG.—There was slow activity to 1.5 Hz in right frontotemporal leads. The α rhythm was less well organized on right

than left, where it was normal and averaged 10.0 Hz. No abnormality was recorded from left scalp leads.

First Hospital Admission.—The initial examination at St Vincent's Hospital revealed mutism. Tongue and lip movements were slow but correct. The patient communicated by head-nodding and gesturing with his right hand.

Verbal comprehension was relatively preserved. He followed three-step commands correctly.

He indicated objects, colors, body parts, and pictures on verbal instruction. Some right-left disorientation was observed. Reading comprehension was intact for simple statements.

Copying numbers, geometric figures, and Greek letters was unimpaired. He drew a clock and set the hands correctly to instruction. Writing single words and simple sentences was grossly preserved. Penmanship was cursive and unimpaired with the unaffected right hand.

Written arithmetic was faulty. He made errors in multiplication but could do simple addition and subtraction usually without error.

Completion of simple phrases included writing "butter" for "bread" and ____; "pepper" for "salt and ____"; and "cheese" for "ham and ____". He could not complete "a cup of ____"; "a slice of ____"; or "knife and ____".

These and other speech-language tests were administered in Chinese. No significant difference from the English performance was observed. That is, he had fluent, cursive penmanship in Chinese, but also made errors in reading and writing. There were no spontaneous or provoked speech utterances in Chinese.

A questionnaire for hand preference was adapted from the one used by Hécaen. The son stated that his father was right-handed for each of the 22 tasks. The children were also right-handed. There was no history of left-handedness in the family.

Standard neuropsychologic tests were administered 5½ weeks after onset. Results are summarized in the Table. The language subtests of the Wechsler Adult Intelligence Scale (WAIS) could not be administered because of mutism. Hence, scores are given from the performance subtests alone. The score of 28 on the Raven's Coloured Progressive Matrices is in a high range for aphasic subjects.⁴

The patient was observed and tested repeatedly in the hospital for 56 days. He had daily speech therapy. Seven weeks after onset of the present illness, he began to make verbal utterances. These were phonemes or single words. Later, phrases were produced. There was phonatory dysfunction; the voice was breathy and low

Accepted for publication May 30, 1979.

From the Department of Neurology, St Vincent's Hospital and Medical Center of New York (Dr April) and the Department of Rehabilitation Medicine, Gouverneur Hospital, New York (Ms Han).

Reprint requests to 4 E 88th St, New York, NY 10028 (Dr April).

in volume. Initiation of phonation was difficult. The voice emerged seconds after a few strained whispers and was unsustainable. Verbal production in Chinese and English was similar—namely, a few words with hesitation and perseveration. Verbal comprehension remained superior to verbal expression. The clinical picture observed at the time of discharge was nonfluent (Broca) aphasia with left hemiplegia. It did not change qualitatively during the subsequent two months.

Second Hospital Admission.—Six months after the stroke the patient suddenly experienced status epilepticus. Postictal neurologic examination showed complete left hemiplegia, left hemispatial inattention, and mixed aphasia with mutism. The premorbid status of nonfluent (Broca) aphasia with mild left hemiparesis gradually reemerged during seven days of anticonvulsant therapy. A repeated CT scan showed unchanged findings. It did not demonstrate a new lesion or extension of the original one in the right cerebral hemisphere. He was discharged on Nov 23, 1978, after successful treatment with anticonvulsants.

Subsequent Aphasia Status.—Spontaneous English conversation was fragmented and consisted of one- and two-word responses, generally “yes” or “no.” He shook or nodded his head to questions. Spontaneous Chinese conversation was less fragmented. For example, when asked about daily oral fluid intake he said in Chinese, “They would not give me.” He rarely spoke complete Chinese sentences and often terminated his statements with “Don’t remember.”

He indicated named objects and body parts correctly. Right-left orientation was normal. He followed one-step but made errors for two-step commands. Gesture mimicking was preserved.

Special Chinese tests were administered by one of us (M.H.). Where possible, the Boston Diagnostic Aphasia Examination (BDAE) was translated into Cantonese. A z-score profile is illustrated in Fig 2. The patient’s scores on subtests were as follows:

Auditory recognition (recognition of letters omitted)	48/66
Comprehension of complex material	4/6
Body part identification	13/20
Responsive naming	6/30
Visual confrontation nam- ing	15/105
Body part naming	0
Animal naming	2
Word repetition	8/8
Sentence repetition	3/10
Word-picture matching	9/10
Automatic speech	All correct
Sentence comprehension	3/10

The cookie theft picture subtest of the BDAE was described in Chinese as “Fall down. Water ran over. He wants to eat cookie.”

The first four sections of the Token Test³ were translated into Chinese and the

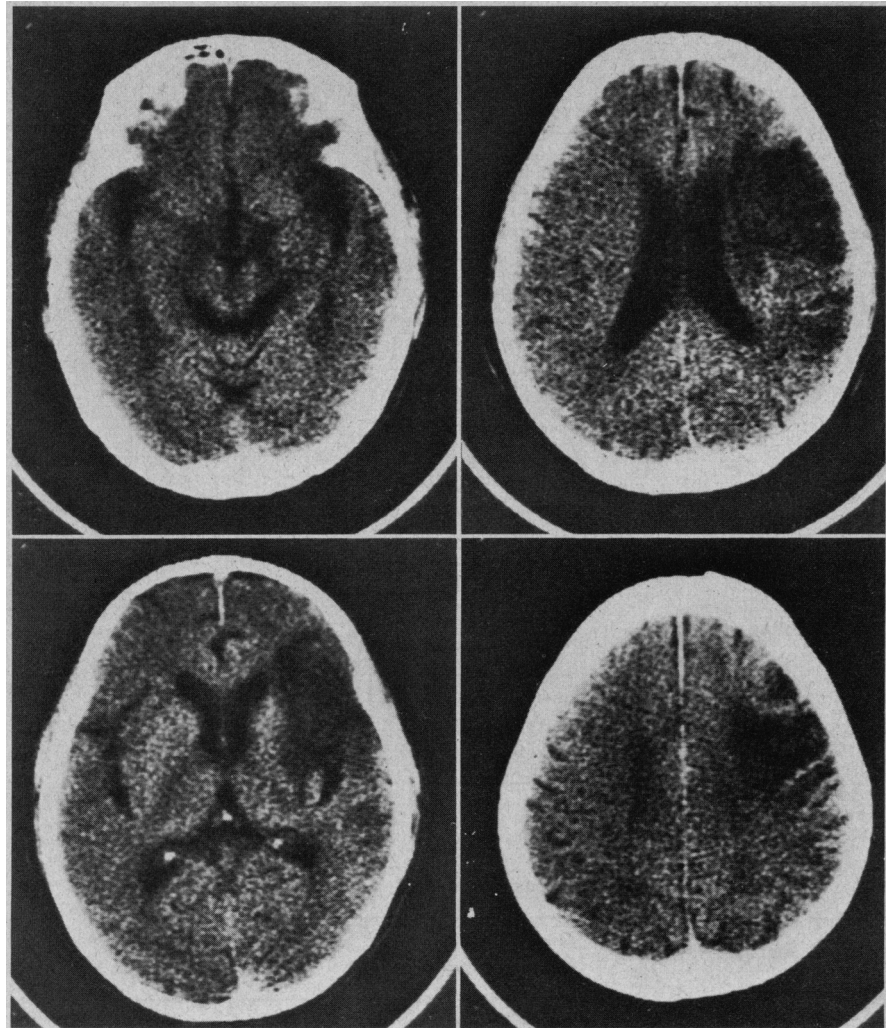


Fig 1.—Computerized tomograms, without contrast enhancement, showing encephalomalacia of right cerebral hemisphere in distribution of branch of middle cerebral artery. No lesion is seen in left cerebral hemisphere.

Neuropsychologic Test Scores					
	5½ wk After Onset	33 wk After Onset	34 wk After Onset	35 wk After Onset	39 wk After Onset
WAIS (raw score)*					
Digit symbol	0
Picture completion	3
Block design	4	†
Picture assembly	0
Object assembly	3
Performance intelligence quotient	74
Benton Test of Visual Retention (part A)	2/23
Wepman Auditory Discrimination Test	X = 5	Y > 3
Raven's Coloured Progressive Matrices	28	20	28
Color-naming	Good
Color recognition	Good
Match stick design copying (BDAE)‡	1/14
Finger-tapping	Good	...

*WAIS, Wechsler Adult Intelligence Scale.

†Cannot be scored. Performance duration in excess of time limit.

‡BDAE, Boston Diagnostic Aphasia Examination.

Z-SCORE PROFILE OF APHASIA SUBSCORES

NAME:

DATE OF EXAM:




Fig 2.—Boston Diagnostic Aphasia Examination translated into Chinese; Z-score profile of aphasia subscores (Fig 2 from Goodglass H, Kaplan E: *The Assessment of Aphasia and Related Disorders*. Philadelphia, Lea & Febiger Publishers, 1972, p 13).

following scores were recorded: part 1, 6/10; part 2, 6/10; part 3, 4/10; part 4, 3/10.

The patient could read and comprehend simple Chinese sentences, but failed to comprehend complex ideational material such as a newspaper caption. He was able to identify the type of business represented in newspaper advertisements. Since his stroke, he had lost interest in reading both Chinese and English daily newspapers.

Examples of premorbid Chinese writing were fluent and indicative of an educated class. Writing to dictation was severely affected. He wrote his name in English, even when told to write in Chinese. It was necessary to repeat the instructions several times before he would write his Chinese name. He wrote his children's names in English but could not write them in Chinese.

His Chinese writing was faulty and showed agrammatism. Word order and component parts of sentences were omitted or distorted. Handwriting errors included incorrect stroke order and stroke completion.

His difficulty writing did not correlate with the number of strokes in the dictated Chinese word. For example, an 11-stroke character was written correctly, but a four-stroke character of equal speech frequency could not be written at all.

As a baseline test of auditory discrimination function, the Wepman Test was administered in English. Performance did not reach criterion for scoring.

The Cantonese dialect has seven spoken tones.⁶ A test of tonal discrimination was devised (by M.H.) using pairs of Cantonese words that differ only in tone, not in phonemic content. For example, *dou* (island) is different from *dou* (arrived). The patient scored 12 of 15 on matching tasks of spoken test words and written symbols. For discrimination of "same or different" between two serially presented tonal words, he scored 7 of 10.

COMMENT

This case report is very similar to the previous one.¹ The present patient was also a true crossed aphasic. He had no history of familial ambilateral-ity, prior brain damage, or seizures, and studies failed to disclose left cerebral dysfunction on clinical, EEG, psychologic, or CT examinations.

Because the neuropsychologic and speech-language performances were similar to those reported in the first case, the arguments pertaining to right cerebral language dominance will not be repeated. However, some differences merit comment.

First, the present patient showed early persistent mutism that evolved to agrammatic speech. Second, no major preference was shown for performance in Chinese or English.

Reviews of crossed aphasia^{7,8} have described a characteristic clinical pic-

ture consisting of mutism evolving to agrammatism with less difficulty in comprehension. Brown and Wilson's single case report⁷ described mutism lasting two months before evolving into Broca's aphasia. Our cases are similar to those reviewed despite their different locations of the causal lesions in right cerebral hemisphere.

The similarity of aphasia type has been interpreted to indicate that cerebral organization of language in crossed aphasic patients is unusual and might resemble that of the developing brain more closely than it does that of the adult brain.⁸ This might explain why a focal lesion, anterior or posterior, in the language zone of crossed aphasic patients and young children with an acquired lesion is more likely to be associated with mutism than with fluent, paraphasic speech.

The present patient showed no major preference for Chinese or English. In our previous case, there was relative preservation of spoken English. In the case of Lyman et al.,² English was also relatively better preserved. There are many examples of different dissociations in reports of polyglot aphasia.⁹⁻¹³ Therefore, the so-called laws of Ribot and Pitres do not appear to be more valid for crossed than for standard aphasia. In any event, students of dissociative trends in Chinese-English bilingual aphasic patients will have to wait for a substantial number of case reports before conclusions can be reached.

It is important to reemphasize the rarity of reported cases of crossed aphasia in dextral patients—the incidence varying between 0.4% and 3.75% of all aphasics.¹⁴⁻¹⁶ A recent report has described a higher incidence in bilingual subjects.¹² The data are taken from reported cases in the neurologic literature, are very few in number, and cover more than 100 years of diverse observations. No personally studied case material was added by the authors. Moreover, when examples of sinistrality or ambilaterality are excluded from the bilingual cases, the overall frequency of crossed aphasia is not significantly different from the upper limit of 3.75% cited previously.¹⁴⁻¹⁶

The two cases of crossed aphasia we observed in Chinese dextral patients raise an important question. Are we seeing an aphasic syndrome of nonalphabetic languages or are the observations only fortuitous? It is tempting to suggest the possibility that learning to read and write a nonalphabetic language might influence the develop-

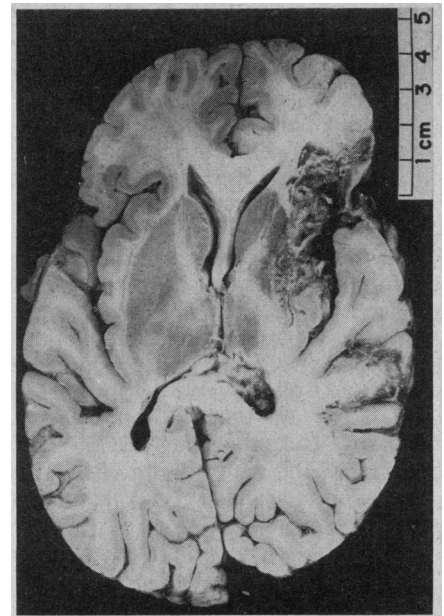


Fig 3.—Section of cerebral hemispheres showing no enlargement or displacement of ventricles.

ment of cerebral language organization, which is the result of diverse biologic and genetic factors.¹⁷⁻¹⁹ Could it be that reading ideographic characters is processed by visuospatial systems of the right hemisphere to a greater extent than reading phonetic letters of alphabetic Western languages?

As for aphasia in nonalphabetic languages, we know of only two other case reports of Chinese patients in the literature.^{2,3} However, there are numerous reports of aphasia in Japanese patients.²⁰⁻²³ The Japanese language has a double writing system—kanji, an ideographic semantic system borrowed from the Chinese, and kana, a phonetic, syllabic writing system. It has been reported that, according to the lesion site, a Japanese aphasic patient can manifest greater difficulty in either kana or kanji.²³

A similar phenomenon has not been reported in aphasia of Western languages. However, we recently studied two case reports of jargon agraphia in French crossed aphasic patients. Both manifested phonetic jargon without semantic content when asked to write a well-known story, even though oral recitation of the same story was fairly intact. We believe that this dissociation of phonetic-semantic performances in an alphabetic language represents the Western analogue of the kana-kanji dissociation in Gogi's aphasia.²³ Therefore, it is not necessarily unique to the Japanese language.

Recently, Sasanuma et al²⁴ reported

that tachistoscopic stimulation of either the right or the left visual half-fields in normal right-handed subjects revealed a significant superiority of the right half-fields for the recognition of kana characters and a nonsignificant trend of the left half-fields for kanji characters. This observation might support the hypothesis that kana and kanji systems are processed differently by the two cerebral hemispheres. Thus, it would follow that Chinese, a totally ideographic language, and English, a totally phonetic language, might also be processed differently by the two hemispheres and that the processing itself might be one of the determining factors in the cerebral organization of language in Chinese subjects.

Such a hypothesis might be further strengthened by the fact of the important tonal properties of the Chinese language and the fact that the right hemisphere has been implicated in musical pitch discrimination, especially in clinical cases of amusia.²³ Chinese words have distinct tones occurring on the voiced part of each syllable. These tones are major determinants of the meaning of the syllables.

Given our two observations and the hypothesis about language-processing in the right hemisphere, an attempt was made to test the relative incidence of crossed aphasia in a multiracial population. A systematic review of patients' hospital charts for the years 1976 and 1977 was carried out. Charts were studied from two New York City hospitals, one of which treats a large Chinese population. There was no trend toward increased incidence of crossed aphasia in any of the populations. Data received from a colleague at the National Taiwan University Hospital failed to show greater correlation between left hemiplegia and aphasia than the 4% upper limit cited previously from the European literature.¹²⁻¹⁴ From these population data, we have been unable to support the hypothesis of altered cerebral dominance in aphasic patients of nonalphabetic language background.

Subsequent to the preparation of this article the patient died of aspiration pneumonia after a prolonged terminal illness that consisted of a fractured hip, confinement to bed, and status epilepticus.

Pathology.—General pathologic examination was not performed; permission was granted only for examination of the brain.

Neuropathologic Examination.—Macroscopic examination of the brain and brainstem showed normal leptome-

ninges. The brain weighed 1,100 g. The cerebral hemispheres were asymmetrical; the right was smaller than the left. There was a circumscribed area of softening in the right frontal lobe, including the posterior inferior part of the lateral surface and measuring approximately 2 × 3 cm. Softening included orbital gyri and inferior part of the precentral gyrus. Minimal softening of the anterior tip of the right superior temporal gyrus was present. The softening extended caudally as a linear lesion on the frontoparietal operculum to the angular gyrus where it expanded to an area about 1 × 1 cm. Gross examination of the base revealed neither atheromas in cerebral vessels nor softenings of the brain stem. The right cerebral peduncle was smaller than the left.

Section of cerebral hemispheres (Fig 3) showed no enlargement or displacement of the ventricles. The right cerebral softening was orange-brown and involved the following cortical and subcortical structures: (1) frontal operculum and subjacent white matter; (2) insula and subjacent white matter (arcuate fasciculus); (3) lentiform nucleus, sparing a small portion of the most anterior and medial part; (4) internal capsule; (5) medial aspect of the tip of the superior temporal gyrus; (6) angular gyrus. Although the softening did not involve the right thalamus, the dorso-medial nuclei were smaller than those on the left.

No lesions were seen in the entire left cerebral hemisphere. No appreciable generalized cortical atrophy was present.

Neuropathologic diagnosis was cystic encephalomalacia (hemorrhagic, old), involving the right cerebral hemisphere in distribution of branch vessels of the middle cerebral artery, possibly embolic in origin.

The pathologic findings confirm the clinical diagnosis of crossed aphasia, since only right cerebral lesions were demonstrated. Both regions of softening—the anterior, larger one in the frontal operculum and the posterior, smaller one in the angular gyrus—were seen in the CT scan. This pathologic examination corroborates the clinical diagnosis and supports the accuracy of CT scanning for brain-language correlation.

Figure 2 is reproduced with permission from Lea & Febiger Publishers. The illustration originally appeared as Fig 1 in Goodglass H, Kaplan E: *The Assessment of Aphasia and Related Disorders*. Boutros Saadeh, MD, referred the patient; Peter C. Tse, MD, performed the Chinese language examination during the patient's first

hospitalization; Albert Messina, MD, interpreted the CT scans; Anne Polin typed the manuscript.

References

1. April RS, Tse PC: Crossed aphasia in a Chinese bilingual dextral. *Arch Neurol* 34:766-770, 1977.
2. Lyman RS, Kwan ST, Chao WH: Left occipito-parietal brain tumor with observations on alexia and agraphia in Chinese and English. *Chin Med J* 54:491-516, 1938.
3. Alajouanine T, Cathala HP, Metellus J, et al: La problématique de l'aphasie dans les langues à écriture non alphabétique: à propos d'un cas chez un chinois. *Rev Neurol* 128:229-243, 1973.
4. Kertesz A, McCabe P: Intelligence and aphasia: Performance of aphasics on Raven's Coloured Progressive Matrices (RCPM). *Brain Lang* 2:387-395, 1975.
5. DeRenzi E, Vignolo LA: The Token Test: A sensitive test to detect receptive disturbances in aphasics. *Brain* 85:665-678, 1962.
6. Huang P: *Cantonese Sounds and Tones*. New Haven, Conn, Yale University Far Eastern Publications, 1965.
7. Brown J, Wilson FP: Crossed aphasia in a dextral. *Neurology* 23:907-911, 1973.
8. Brown J, Hécaen H: Lateralization and language representation. *Neurology* 26:183-189, 1976.
9. Ribot T: *Disease of Memory: An Essay in the Positive Psychology*. London, Paul, 1882.
10. Pitres A: Etude sur l'aphasie chez les polyglots. *Rev Med* 15:873, 1895.
11. Minkowski M: On aphasia in polyglots, in Halpern L (ed): *Problems of Dynamic Neurology*. Jerusalem, Post Press, 1963, pp 119-161.
12. Albert M, Obler L: *The Bilingual Brain: Neuropsychological and Neuro-Linguistic Aspects of Bilingualism*. New York, Academic Press Inc, 1978, p 149.
13. Silverberg R, Gordon HW: Differential aphasia in two bilingual individuals. *Neurology* 29:51-55, 1979.
14. DeAjuriaguerra J, Hécaen H: *Le Cortex Cérébral*. Paris, Masson et Cie, 1964.
15. Penfield W, Roberts L: *Speech and Brain Mechanisms*. Princeton, NJ, Princeton University Press, 1959.
16. Gloning I, Gloning K, Haub G, et al: Comparison of verbal behavior in right-handed and non-right-handed patients with anatomically verified lesions of one hemisphere. *Cortex* 5:43-52, 1969.
17. Kennedy F: Stock-brainedness, the causative factor in the so-called crossed aphasia. *Am J Med Sci* 152:849-859, 1962.
18. April RS, Tse PC: Reply in LETTERS TO EDITORS, Crossed aphasia in a Chinese bilingual dextral. *Arch Neurol* 35:694, 1978.
19. Anastopoulos G, Kokkini D: Cerebral dominance and localization of the language functions. *Psych Neurol* 143:6-19, 1962.
20. Sasanuma S, Fujimara C: Selective impairment of processing phonetic and non-phonetic transcriptions of words in aphasic patients: Kana and Kanji in visual recognition of writing. *Cortex* 7:196-218, 1971.
21. Sasanuma S, Fujimara C: An analysis of writing errors in Japanese aphasic patients: Kanji versus Kana words. *Cortex* 8:265-282, 1972.
22. Imura T, Nogami Y, Asakawa K: Aphasia in the Japanese language. *Nikon Univ J Med* 13:69-90, 1971.
23. Sasanuma S, Monoi H: The syndrome of Gogi (word meaning) aphasia. *Neurology* 25:627-632, 1975.
24. Sasanuma S, Itoh M, Mori K, et al: Tachistoscopic recognition of Kana and Kanji words. *Neuropsychologia* 15:547-553, 1977.
25. Botez MI, Wertheim N: Expressive aphasia and amusia following right frontal lesion in right-handed man. *Brain* 82:186-202, 1959.