

Transient global amnesia as a manifestation of transient cerebral ischemia

TROELS STAEHELIN JENSEN AND BENT DE FINE OLIVARIUS

Ten patients with transient global amnesia (TGA) associated with symptoms of transient focal cerebral ischemia were seen at the University Department of Neurology, Århus Kommunehospital in the period 1966-1978. All had either prior to or following the amnesic attack transient ischemic attacks (TIA) in the territory of the posterior cerebral circulation. On admission minor neurological deficits were noted in three and normal findings in the remaining seven. There was no evidence of epilepsy in any case.

We studied the course (average, 77 months) and found that three had recurrent amnesic episodes. Four patients had only further transient focal cerebral ischemic attacks, while six developed a completed stroke, in five located in the distribution of the basilar artery. Seven patients had persistent memory impairment.

TGA is one manifestation of TIA in the vertebrobasilar arterial system.

When TGA appears in connection with other transient cerebral ischemic attacks, the prognosis is apparently grave with a great risk of a subsequent completed stroke or a permanent memory impairment.

Key words: Completed stroke - permanent memory impairment - prognosis - transient global amnesia - vertebrobasilar TIA.

Transient global amnesia (TGA) is a nosographically well-defined condition characterized by a sudden short-term memory defect in elderly people with inability to lay down new memory traces for a circumscribed period, but according to earlier observations without any other significant intellectual or neurological symptoms (*Benson et al. 1974, Evans 1966, Fisher & Adams 1964*). The results of most recent investigations (*Fogelholm et al. 1975, Heathfield et al. 1973, Mathew & Meyer 1974, Mumenthaler & von Roll 1969, Rowan & Protass 1979*) have suggested that pathophysiologically TGA is probably the result of transient ischemia affecting the hippocampal formation and other parts of the limbic system related to memory functions.

Despite a remarkable uniform and well-demarcated clinical picture, controversy still exists as to its etiology and prognosis. There is no explanation of the apparent paradox, that on one hand it has been claimed that TGA is usually connected with a good prognosis (*Fisher & Adams 1964, Fogelholm 1975, Godlewski 1968, Mumenthaler & von Roll 1969, Nausieda &*

Sherman 1979), while on the other hand that the amnesic episode is probably a result of transient ischemia in the posterior circulation of the brain, a condition which is generally associated with a rather grave prognosis giving warning of an impending stroke.

The present study was undertaken to elucidate this apparent paradox and to describe the clinical details of TGA when it occurs as a possible manifestation of transient ischemic attacks (TIA).

MATERIAL

Among 28 consecutive patients with one or several TGA episodes (defined according to *Fisher & Adams*) admitted to the University Department of Neurology, Århus Kommunehospital from 1966–1978, 10 patients (seven males and three females) were found who all had symptoms compatible with TIA either prior to or following the amnesic episode. The seven men and three females ranged in age from 49 to 74 years (average: 61 years).

Clinical presentation

The clinical features of the patients are summarized in Table 1. Three patients had experienced a previous amnesic attack, the duration of which was from ½–24 h. Precipitating factors were encountered in five cases, and in five patients (case Nos. 1, 4, 5, 7, 9) transient focal neurological symptoms were noted during the amnesic attack, suggesting a more widespread ischemia in the vertebrobasilar arterial system. All patients had either prior to or after the TGA experienced from one to several episodes of transient focal neurological symptoms compatible with TIA in the vertebrobasilar arterial distribution area. Episodic vertigo and transient visual disturbances were the most frequent complaints.

In three cases the TGA episode appeared to be the first manifestation of later appearing clearcut TIA's.

Findings at examination

The initial neurological assessment performed on an average of 21 days after the amnesic attack revealed minor neurological residua in three and normal findings in the remaining seven (Table 2). There was no history of epilepsy in any case at the primary examination. The EEG showed temporal theta activity either unilaterally or bilaterally in six cases and no abnormalities in four.

Cerebral angiography was carried out in four patients (2, 3, 4, 9) demonstrating arteriosclerotic lesions in all. One had a bilateral occlusion of the internal carotid arteries, with collateral cerebral circulation through the ophthalmic arteries.

Table 1. Clinical presentation of patients with transient global amnesia and concomitant transient ischemic attacks

Case No.	Age	Sex	Duration of amnesia	Previous attacks	Precipitating factor	Associated symptoms during attack
1	51	M	4-5 h	None	Neck extension	Dysarthria. Incoordination of upper extremity
2	71	M	½-1 h	One	Unknown	Speech difficulty
3	74	F	¾ h	None	Unknown	None
4	63	M	2-3 h	None	Exertion	Headache. Incoordination of extremities
5	62	M	1-7 h	None	Sunbathing	Speech difficulty. Coordination disturbance
6	49	M	1½ h	One	Unknown	Headache
7	61	F	6-7 h	One	Neck extension	Bilateral blurred vision. Incoordination
8	61	M	3 h	None	Neck extension	None
9	56	M	24 h	None	Unknown	Paraesthesia in both hands
10	60	F	5-6 h	None	Cold	None

Table 2. Findings at initial examination

Case No.	Time of examination following TGA	Neurological findings	EEG	Other findings
1	17 days	Normal	Normal	Right carotid angiography: normal
2	30 days	Bilateral dysdiadochokinesia, bilateral Babinsky	Left temporal theta focus	Angiography: bilateral occlusion of internal carotid arteries
3	22 days	Normal	Left temporal slow-wave activity	Left carotid angiography: arteriosclerosis
4	34 days	Normal	Right temporo-occipital theta activity	Angiography: bilateral arteriosclerosis of carotid arteries
5	8 days	Right dysdiadochokinesia	Bilateral temporo-occipital theta activity	
6	25 days	Normal	Normal	
7	1 day	Mild left hemiparesis Light-fixed pupils	Normal	
8	35 days	Normal	Normal	
9	7 days	Normal	Normal	Aorta-angiography: arteriosclerosis of left vertebral artery CT-scan.: normal
10	30 days	Normal	Bilateral temporal theta activity with scattered sharp-waves	

Table 3. The course. (Average follow-up: 77 months)

Case No.	Follow-up (months)	Recurrent TGA	Completed stroke (distribution)	Further TIAs only	Extra-cerebral vascular symptoms	Neurological deficit*	Memory impairment*
1	150	One	Vertebrobasilar			+	+
2	120	None	Vertebrobasilar			+++	++
3	90	Several	Carotid			+++	+++
4	84	None	Carotid vertebrobasilar		Myocardial infarction	+++	+
5	84	Several		Yes		○	○
6	72	None		Yes		○	○
7	60	None	Vertebrobasilar			+	+
8	54	None		Yes		○	○
9	48	None		Yes	Intermittent claudication	○	+
10	6	None	Vertebrobasilar			+	+

* ○ = none; + = mild; ++ = moderate; +++ = severe.

Results of follow-up investigations

The patients have been followed up with a range from 6–150 months (average: 77 months). Three patients developed an infarction in the distribution of the basilar artery. One had a stroke in the right hemisphere and two had probably had a small infarction in the brainstem. Three of these patients had a moderate to severe neurological deficit. All patients with neurological deficits complained of persistent memory impairment and only three had not noted permanent memory difficulties. The four patients without neurological deficits all suffered from TIA. Recurrent TGA were noted in three, in two cases several episodes were noted.

ILLUSTRATIVE CASE

Patient 1. A 64-year-old right-handed male with a 20 year history of dyspepsia, but with no previous neurological complaints. In September 1966, at the age of 51 he went alone to his summer residence. He had promised to return at 4 p.m., but didn't appear until 8:30 the same evening. On arrival his wife found him confused, anxious and with a complete memory loss for the foregoing 4–5 h, and he apparently didn't remember events for several days prior to the episode. The following day he complained of headache and he noticed a slight incoordination of the extremities and a dysarthria that subsided within a few hours. On examination 30 days later neurological examination was normal. An EEG showed a slight bilateral slowing, a right carotid angiogram was normal.

The patient remained well until March 1975. With his neck extended he suddenly felt unstable, complained of vertigo and nausea, symptoms that subsided within a few minutes. The following day he had an insidious memory loss for 5–6 h. During the amnesia his wife found him agitated, he kept looking around the house over and over again for hours. He knew his own data, but was disoriented and didn't recognize his house, although he has been living there for 10 years. Finally he calmed down and fell asleep. The next day he was alert, but noticed a slight incoordination of the right arm and a tingling sensation in both hands. Eight days later he had a single drop attack preceded by shortlasting vertigo. The neurological assessment performed 17 days after the amnesic episode revealed normal findings. The EEG showed some theta activity in both temporal regions.

He remained well until November 1978, at which time he suffered a 5-h dysarthria and a left-sided hemiparesis. These symptoms recurred the next day. On admission the same day he was found alert and cooperative. Neurological examination showed a left-sided upper quadrantanopsia, horizontal gaze palsy to the left, a dyspraxia of the tongue and a moderate dysidiadochokinesia on the left. An EEG 3 days later showed some delta ac-

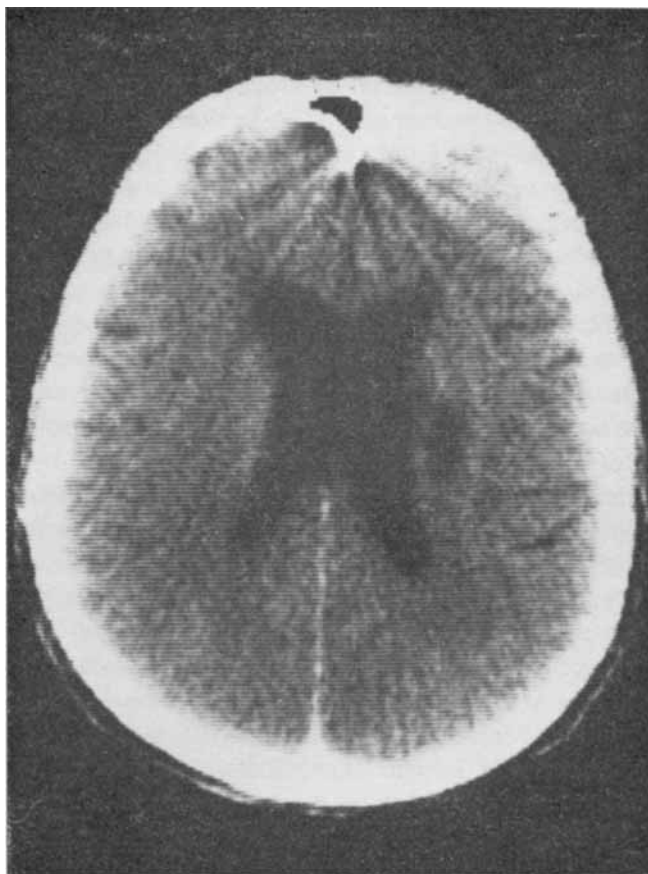


Figure 1. Computerized tomographic (CT) scan of patient No. 1, 1 year following completed stroke, revealing a dilatation of the ventricular system and a low-absorbing area in the right lenticular nuclei.

tivity in the right temporooccipital region with scattered sharpwaves. A computerized tomography 5 days after showed a low-absorbing area in the posterior part of the internal capsule. His condition improved markedly and when seen half a year later there remained a dyspraxia of the tongue and a mild left-sided dysdiadochokinesia. He had, however, a persistent memory difficulty, confirmed by a psychological testing. This disclosed a prosopagnosia, a reduced ability to learn and retain visual and auditory presented material. His digit span was within normal limits, however, and he had no difficulty recalling remote events.

Comment. This case demonstrates the evolution from a TGA episode, through other TIA manifestations, a further amnesic attack and finally a subsequent completed stroke 12 years after the initial TGA.

DISCUSSION

All patients in the present material had one or several amnesic episodes which conformed to the syndrome of TGA as described in detail by *Fisher & Adams* (1964), *Godlewski* (1968) and *Evans* (1966).

From a clinical point of view memory has traditionally been divided into three stages: immediate recall, short-term memory and long-term memory, a division depending on the timespan between the sensory stimulus and the retrieval of the memory trace that has been formed. This division of the memorizing process into three phases is supported by the memory defect seen in TGA and most other amnesic states, where the cardinal feature is an elective impairment of short-term memory and a certain retrograde amnesia of rarely more than a few hours duration (*Barbizet* 1963, *Benson et al.* 1974, *DeJong* 1973, *Weiskrantz & Warrington* 1975).

Both experimental and pathoanatomical studies have clearly established that amnesic disorders in man are intimately connected with lesions of the hippocampus, the parahippocampal formation and other parts of the limbic system (*Barbizet* 1963, *DeJong* 1973, *Whitty & Lishman* 1966). The role of the two temporal regions are apparently different: left temporal lobe lesions thus causes an auditory verbal memory defect, while the nondominant temporal lobe seems to be involved in the retention of nonverbally patterned modalities (*Steinmetz & Vroom* 1972). As regards the global short-term memory defect seen in TGA, bilateral hippocampal dysfunction appears to be necessary to produce the syndrome, although a unilateral temporal lobe lesion may in a few instances have the same effect upon memory as far as can be asserted (*Steinmetz & Vroom* 1972).

Various pathological states have been incriminated as the basis of the syndrome. *Fisher & Adams* (1964), who gave the first thorough description of TGA, favored an epileptic etiology. In two of our cases epilepsy was actually considered mainly because of the frequently recurrent amnesic attacks. The amnesia in these patients was, however, indistinguishable from that of the other patients where a vascular basis seemed more likely. The long duration of the amnesia, the lack of persistent epileptic discharges in the electroencephalogram and of other epileptic features make this cause less likely (*Rowan & Protass* 1979). Furthermore, the age range of the patients, the sudden onset of the syndrome and in particular symptoms of a coexistent basilar artery insufficiency point to a vascular etiology. This hypothesis is further strengthened by the fact that bilateral occlusion of the posterior cerebral arteries produces ischemia and infarction of the medio-basal parts of the temporal lobes, especially in the hippocampal formation, and the result is a profound permanent loss of recent memory (*Benson et al.* 1974, *Whitty & Lishman* 1966). *Benson et al.* (1974) mentioned that a

major objection to the vascular etiology was the lack of associated clinical findings. In the present series all 10 patients had actually TIA manifestations in the distribution of the vertebrobasilar arterial system and in five cases the amnesic attack was accompanied by symptoms of vertebrobasilar insufficiency, suggesting that the amnesia itself was due to ischemia in the same arterial distribution area: Our case 1 lends further support to a vascular mechanism, demonstrating that the transient memory disturbance can ultimately become permanent, when an infarction develops. Similar cases have been reported by *Steinmetz & Vroom* (1972) and *Heathfield et al.* (1973).

There have been only a few reports commenting on the prognosis of TGA. Most authors consider TGA an essentially benign condition, which bears a low risk of a subsequent completed stroke or recurrent TGA, and a general reluctance as regards neuroradiological investigations and treatment has been prevalent. *Fisher & Adams* (1964) thus, among 17 cases with a mean follow-up time of 3.2 years, found one patient who developed a moderately severe stroke 7 months after the TGA attack. *Godlewski* (1968) observed five cases out of 33 who had symptoms compatible with TIA in the vertebrobasilar distribution area, but none developed an infarction in subsequent years. No episodes of completed stroke were noted in the study of *Nausieda & Sherman* (1979) where 32 patients have been followed for an average of 46 months. This favorable prognostic view has recently been disputed by *Mathew & Meyer* (1974), who among 14 patients found that about 70 % developed a subsequent "amnesic" stroke or suffered from a disabling dementia. Our data are in accordance with this last study, since six patients in the present series developed a completed stroke during the follow-up period, and all these had a permanent short-term memory impairment.

In our view TGA should be considered as one of the symptoms of vertebrobasilar insufficiency, whether of arteriosclerotic origin, a consequence of embolism or merely a result of shortlasting vasoconstriction in the arterial branches supplying the hippocampal formation. The latter mechanism probably explains the favorable prognosis of TGA when it occurs in association with migraine (*Olivarius & Jensen* 1979). When TGA occurs in connection with other TIA manifestations either prior to, concomitant with or following the amnesic episode, it is apparently not a benign condition and the risk of further disablement from strokes, other "malignant" vascular diseases and permanent memory deficits is considerable. The practical implications are difficult to outline, but careful control of risk factors for cerebrovascular disease must be undertaken. Treatment to prevent platelet aggregation or anticoagulant medication should, in our view, be seriously considered.

REFERENCES

- Barbizet, J. (1963): Defect of memorizing of hippocampalmamillary origin: A review. *J. Neurol. Neurosurg. Psychiat.* 26, 127-135.
- Benson, D. F., C. D. Marsden & J. C. Meadows (1974): The amnesic syndrome of posterior cerebral artery occlusion. *Acta Neurol. Scand.* 50, 133-145.
- DeJong, R. N. (1973): The hippocampus and its role in memory. Clinical manifestation and theoretical considerations. *J. Neurol. Sci.* 19, 73-83.
- Evans, J. H. (1966): Transient loss of memory, an organic mental syndrome. *Brain* 89, 539-548.
- Fisher, C. M. & R. D. Adams (1964): Transient global amnesia. *Acta Neurol. Scand.* 40, Suppl. 9.
- Fogelholm, R., E. Kivalo & L. Bergström (1975): The transient global amnesia syndrome. *Eur. Neurol.* 13, 72-84.
- Godlewski, S. (1968): Les épisodes amnésiques (Transient global amnesia) (Étude clinique basée sur 33 observations inédites). *Sem. Hôp. Paris* 44, 553-577.
- Heathfield, K. W. G., P. B. Croft & M. Swash (1973): The syndrome of transient global amnesia. *Brain* 96, 729-736.
- Martin, E. (1970): Transient global amnesia. A report of 11 cases, including five amnesia at the seaside. *Irish J. Med. Sci.* 3, 331-335.
- Mathew, N. & J. S. Meyer (1974): Pathogenesis and natural history of transient global amnesia. *Stroke* 5, 303-311.
- Mumenthaler, M. & L. von Roll (1969): Amnestische episoden. Analyse von 16 eigenen beobachtungen. *Schweiz. Med. Wschr.* 99, 133-139.
- Nausieda, P. A. & I. C. Sherman (1979): Long-term prognosis in transient global amnesia. *J. Am. Med. Assoc.* 241, 392-393.
- Olivarius, B. de Fine & T. S. Jensen (1979): Transient global amnesia in migraine. *Headache* 19, 335-338.
- Rowan, A. J. & L. M. Protass (1979): Transient global amnesia: Clinical and electroencephalographic findings in 10 cases. *Neurol.* 29, 869-872.
- Serafetinides, E. A. & M. A. Falconer (1962): Some observations on memory impairment after temporal lobectomy for epilepsy. *J. Neurol. Neurosurg. Psychiat.* 25, 251-255.
- Steinmetz, E. F. & F. Q. Vroom (1972): Transient global amnesia. *Neurol.* 22, 1193-1200.
- Weiskrantz, L. & E. K. Warrington (1975): The problem of the amnesic syndrome in man and animals. The hippocampus. Volume 2: Neurophysiology and behaviour, ed. R. L. Isaacson & K. H. Pribram, pp. 411-428. Plenum Press, New York and London.
- Whitty, C. W. M. & W. A. Lishman (1966): Amnesia in cerebral disease. *Amnesia*, ed. C. W. M. Whitty & O. L. Zangwill, pp. 36-76. Butterworths & Co. Ltd., London.

Received October 21,
accepted November 13, 1979

Troels Staehelin Jensen, M.D.
Department of Neurology
Århus Kommunehospital
DK-8000 Århus C
Denmark