

## Barbiturate therapy in the management of cerebral ischaemia

M. BELOPAVLOVIC AND A. BUCHTHAL

### Summary

*Two patients who underwent surgery for cerebral aneurysms are presented. In the first case 31 g thiopentone were given postoperatively over 20 h after the patient had already been comatose for many hours. Such high doses raise considerable problems in patient management. In the second case a loading dose of 50 mg/kg thiopentone was given prophylactically to a patient undergoing cerebral aneurysm surgery beginning at the induction of anaesthesia and before surface cooling was begun. Cerebral activity was monitored continuously with a cerebral function monitor (CFM). There was no significant cardiovascular depression, little delay in postoperative recovery and no permanent neurological sequelae.*

*In cerebral aneurysm surgery, cerebral oedema following cerebral ischaemia, either associated with vasospasm or resulting from surgical occlusion of vessels, remains a major problem postoperatively and may be an indication for preventive treatment with barbiturates. The authors contend that this technique merits further evaluation in cerebro-vascular surgery, especially in high risk cases.*

### Key words

*Anaesthesia, neurosurgical*

*Hypnotics; barbiturates*

The action of barbiturates in protecting the brain against the effects of cerebral ischaemia has been reviewed in another paper in this issue.<sup>1</sup> There are now a number of clinical reports of their use in cerebral ischaemia resulting from cerebral oedema, cardiac arrest or local vascular insufficiency. In patients with head injuries or Reye's syndrome<sup>2-5</sup> barbiturates have been used only at a late stage after it was clear that their intracranial hypertension was uncontrollable by conventional means and the prognosis would otherwise be considered to be hopeless. The time interval from the injury or from the time at which the patient's condition began to deteriorate is often not described. The

experimental work reviewed by the present authors,<sup>1</sup> however, indicates that prompt action is crucial to the success of barbiturate therapy so that better results might be expected if this is initiated with minimum delay. Early treatment is attempted in the Pittsburgh trials<sup>6</sup> in which thiopentone is given to patients after cardiac arrest, if possible within 10 min of restoration of the circulation. Thiopentone has also been used intraoperatively for the rapid reduction of intracranial pressure.<sup>7</sup> Planned procedures where patients are pretreated with barbiturates before a time of potential risk to the cerebral circulation such as during carotid artery and cerebrovascular surgery might be expected to

yield the best results. However, in this case the results are very difficult to interpret as the risk to the patient cannot usually be assessed beforehand and subjects cannot be matched for a controlled trial.

Early initiation of barbiturate therapy after an episode of cerebral ischaemia not only calls for very precise definition of the indications for therapy but also presents a number of difficulties.

In patients who sustain head injuries it would appear that those who are conscious and rational immediately following the injury and begin to deteriorate later should be regarded as developing brain damage which is potentially reversible or preventable and should therefore be given barbiturates as soon as assessment on the Glasgow Coma Scale and neurological assessment indicate deterioration. This can be done regardless of the intracranial pressure or electro-encephalogram (EEG) at that time provided that a diagnosis has been made and that other treatable causes of the deterioration, such as intracranial haemorrhage or cardiopulmonary problems have first been excluded. This involves a full neurological assessment, obtaining skull and chest X-rays, computerised tomography (CT) scanning and angiography. These procedures necessarily take a certain time. Further, there may be some delay before the patient reaches hospital and a reliable neurological assessment can be made. The patient's prognosis may be difficult to assess when barbiturate therapy is begun and this should be explained to the relatives. The anaesthetist, neurologist and neurosurgeon should undertake such therapy in cooperation and every attempt should be made to avoid starting barbiturate therapy in patients who may be considered to have sustained irreversible brain damage.

Neurological assessment becomes very difficult in a comatose patient requiring artificial ventilation and receiving barbiturate therapy. Tendon reflexes, brainstem evoked responses and evoked potentials may persist while pupil signs, corneal reflexes and caloric responses disappear under the influence of large doses of barbiturates.

The intracranial pressure should be monitored continuously. If it is high initially a good response to barbiturates favours a good prognosis.<sup>2</sup> EEG's and CT scans should be made intermittently; a continuous record of cerebral

activity can be obtained with a cerebral function monitor (CFM) (Devices).

The electrocardiogram (ECG), arterial blood pressure via an arterial line, central venous pressure and end tidal CO<sub>2</sub> concentration should be routinely monitored, as should blood biochemistry. In some patients the use of a Swan Ganz catheter for the measurement of pulmonary artery wedge pressure and cardiac output by thermodilution may be indicated. Blood barbiturate levels should be estimated regularly and the maintenance of levels higher than the usual 2.5–3.5 mg/decilitre pentobarbitone should be considered if there has been a substantial delay before therapy was started. Discontinuing barbiturate administration in order to make a neurological assessment may be detrimental and predisposes to the development of tolerance if barbiturate therapy is resumed later. The result may be reduced efficacy of the same dose of barbiturates, or, if the dose is increased to maintain the same degree of cerebral depression, troublesome cardiovascular depression. The patient should be in a stable haemodynamic state before barbiturates are given. Cardiovascular depression may limit the dose and rate of administration of barbiturates which can safely be given, particularly to patients with cardiac disease. These patients may also be more prone than others to dysrhythmias so that the use of cardiotonic drugs may also be limited. Isoprenaline or dopamine or both may be needed to maintain cardiac output and peripheral perfusion. Urine output should be maintained at least at 60 ml/h.

Patients receiving barbiturate therapy also face all the problems associated with prolonged intubation, ventilation and immobility together with depressed responses, including the cough reflex. Frequent physiotherapy must therefore be given with efficient postural drainage and suction and the patient should be turned regularly in order to avoid atelectasis and hypostatic pneumonia as well as skin damage and venous thrombosis. The eyes should be covered to prevent corneal damage. These patients are very susceptible to infection since all body defences are depressed, particularly if they are also receiving steroids in high doses, so that antibiotics may be given prophylactically. Low dose heparin therapy may also be given in order to prevent thrombotic complications.

Blood barbiturate levels may take a consider-

able time to fall after the administration of high doses is discontinued and recovery may be much delayed.

### Case 1

The patient, a female aged 51 years, was admitted 25 days after a subarachnoid haemorrhage. This had been accompanied by headache and vomiting without loss of consciousness and was followed by labile hypertension. She had a history of repeated bronchitis and of mild hypertension for some years which had been treated with a diuretic. On admission there was no neurological deficit; the arterial pressure was 135/90 mmHg and the cerebrospinal fluid (CSF) was clear. Four vessel angiography showed a saccular aneurysm of the anterior communicating artery, three anterior cerebral arteries and an absent left vertebral artery.

Surgery was carried out under steroid cover. Seldinger angiography was repeated 45 minutes after premedication with atropine, promethazine, chlorpromazine and pethidine.

Endotracheal anaesthesia was induced with pancuronium, thiopentone, suxamethonium and pethidine and continued with pancuronium, pethidine, droperidol and ventilation with 33% O<sub>2</sub>, 67% N<sub>2</sub>O. After placing three large peripheral intravenous lines, an oesophageal stethoscope and oesophageal, rectal and skin temperature probes, the patient was moved to a water bath. The water bath is used as an operating table as well as for cooling and rewarming the patient. The patient was cooled to an oesophageal temperature of 32.5°C with iced water at 10°C. Water was then drained from the bath and lumbar puncture performed through a hatch. Arterial pressure was monitored via the Seldinger catheter and end-tidal CO<sub>2</sub> with a capnograph (Godart).

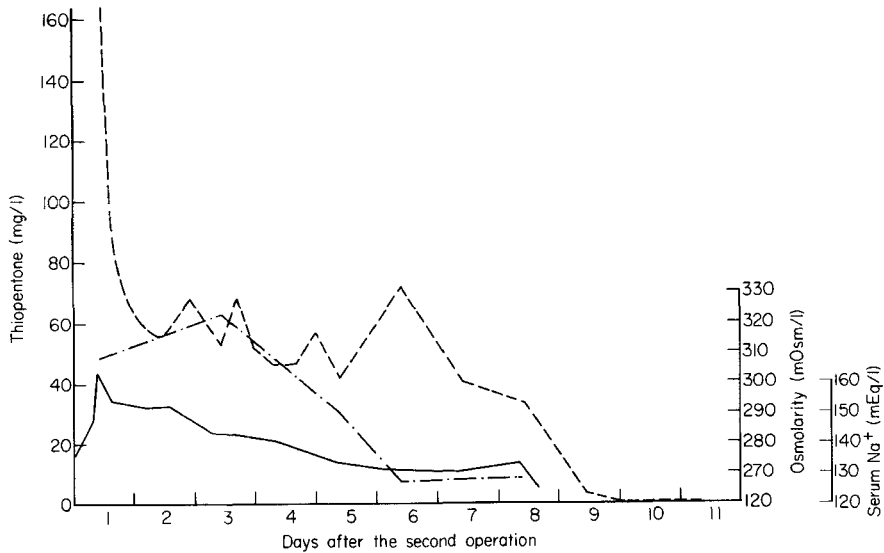
A right frontal craniotomy was undertaken; 120 ml CSF were drained to facilitate surgery after the dura was opened. The aneurysm was then localised by further angiography. Anaesthesia proceeded uneventfully. A sodium nitroprusside infusion was started at 80 mg/min as the arterial pressure rose to 160/100 mmHg with surgical retraction and the mean arterial pressure (MAP) was allowed to fall to 65 mmHg during dissection of the aneurysm.

The aneurysm was effectively excluded from the cerebral circulation with a clip but this

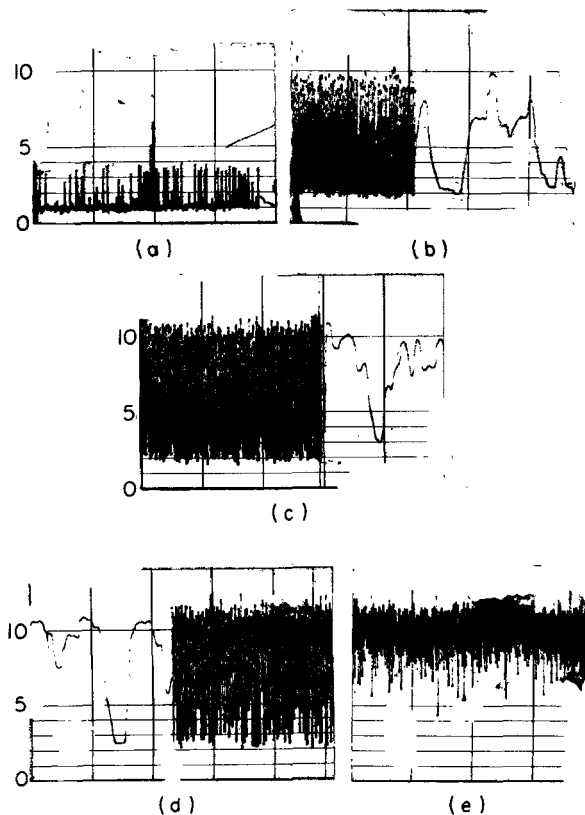
proved possible only at the expense of obliterating one of the three anterior cerebral arteries. The nitroprusside infusion was then discontinued, the arterial pressure rose to 120/70 mmHg and rewarming was begun. Epidural transducers (Philips) were placed symmetrically in frontal burr holes 3 cm from the midline on both sides during closure. At 18.15 hours the oesophageal temperature reached 35.7°C, the patient opened her eyes and was able to obey commands; she was extubated and transferred to the Intensive Therapy Unit. The pupils were equal and reactive but she was aphasic and had a right hemiparesis. The epidural pressures immediately postoperatively were 4.3 mmHg on the right and 1.1 mmHg on the left. The dexamethasone was continued and usual anticonvulsant doses of phenobarbitone and phenytoin given.

The patient's level of consciousness deteriorated during the night and the following morning she was comatose, unresponsive to painful stimuli and had a right hemiplegia. The pupils were equal and reactive. During the course of the day the epidural pressures rose to 33 mmHg on the right, 16 mmHg on the left. The patient became unresponsive and areflexic. At 19.00 hours she was taken back to theatre for re-exploration. A small extradural haematoma was found with global cerebral oedema. The bone flap of the craniotomy was removed and only the left epidural transducer was left in place.

Postoperatively, the patient was left intubated and ventilated and remained unresponsive and areflexic. The pupils were pinpoint, unequal, the right larger than the left, and unreactive. The left epidural pressure was 12 mmHg initially and rose to 15 mmHg. She was started on ampicillin and cimetidine. At this time it appeared that nothing more could be achieved with conventional therapy and barbiturate therapy was started at 23.00 hours in agreement with the neurosurgeons; 1.5 grams of thiopentone were given slowly intravenously followed by an infusion of 2.5 g/h (about 50 mg/kg/h). Neither EEG nor CFM control was available at this time. A dopamine infusion was required to maintain the MAP above 80 mmHg (a cerebral perfusion pressure of 70 mmHg for the left side as the left epidural pressure fell to 10 mmHg). Arterial and right atrial pressures were measured directly together with left epi-



**Fig. 1.** Case 1. Serum thiopentone levels, serum osmolalities and sodium concentrations: 1-12 days after the second operation. ---- Serum thiopentone levels (mg/l); — Serum Na<sup>+</sup> (mEq/l); - · - · - serum osmolality (mOsm/l).



**Fig. 2.** Case 1. Cerebral Function Monitor (CFM) record: 1-5 days after the second operation.

- (a) First day: 1730 hours. Thiopentone level 73 mg/l. Pupils pinpoint, unreactive and unequal (right > left). Patient areflexic and unresponsive. EEG iso-electric.
- (b) Second day: 0730 hours. Thiopentone 56 mg/l. Pupils unreactive but equal. EEG showed burst-suppression.
- (c) Third day: 2000 hours. Thiopentone 68 mg/l. Pupils intermittently reactive and unequal (right > left). No response to caloric testing.
- (d) Fourth day: 1000 hours. Thiopentone 54 mg/l. Pupils reactive and equal.
- (e) Fifth day: 1500 hours. Thiopentone 47 mg/l. Eyelash, corneal and tendon reflexes present, coughing on tracheal suction.

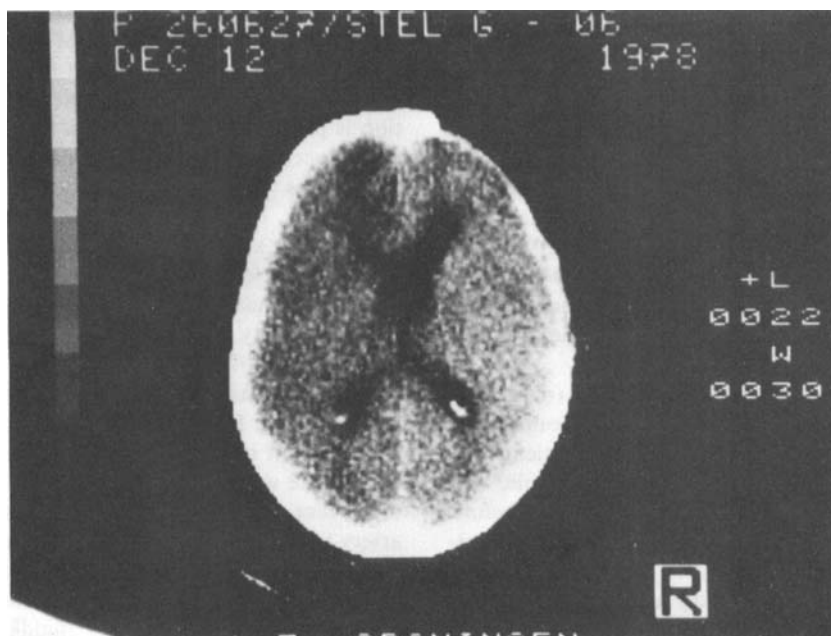


Fig. 3. Computerised tomography (CT) scan twenty days after the second operation showing a left frontal infarct.

dural pressure and end-tidal  $\text{CO}_2$  concentration which was maintained at 3.7–4.5%. The patient received 500 ml 5% human albumin and 6 mEq/h KCl and remained warm with a good urine output overnight.

Two days postoperatively the EEG was isoelectric and the pupils remained fixed, the right larger than the left. Cerebral activity was monitored continuously with a CFM (Devices). The thiopentone infusion was discontinued at 19.30 hours after a total dose of over 31 g had been given over 20 h. The highest measured serum thiopentone level was 166 mg/litre. The serum thiopentone levels are shown in Fig. 1. Ventilation was continued with 40%  $\text{O}_2$  in air. Diuresis continued at over 150 ml/h and the plasma  $\text{K}^+$  remained at 2.8 mmol/litre despite the administration of 4.8 mmol/h. Plasma  $\text{Na}^+$  rose to 164 mmol/litre and osmolality to 314 milliosmoles/litre.

On the fourth postoperative day the serum thiopentone level had fallen to 56 mg/litre while the EEG showed a burst-suppression pattern with much longer periods of suppression than of bursts. The neurological progress of the patient is shown in Fig. 2. On the sixth postoperative day the pupils were equal and reactive, there was a positive response to caloric testing;

corneal, lash and tendon reflexes were present and the patient was coughing on tracheal suction. The CFM trace was now much narrower and the baseline about 8  $\mu\text{V}$ . She developed a left lower lobe hypostatic pneumonia which required continued ventilation with +5 cm  $\text{H}_2\text{O}$  end-expiratory pressure, physiotherapy and gentamicin.

Nine days after starting thiopentone therapy the patient obeyed commands and appeared to be fully aware; the blood thiopentone level was now zero. She was extubated 14 days after barbiturate therapy was started; she appeared to be aphasic and had a right hemiplegia. A CT scan showed evidence of a left frontal infarct (Fig. 3). She began to talk after a few days and the power in her right arm and leg improved.

She was discharged home within 3 months postoperatively and has a mild, residual hemiparesis which continues to improve.

### Discussion

A massive dose of thiopentone was given to this patient after her condition failed to improve following surgical decompression and conventional management. She had been deeply coma-

tose for more than 15 h and the pupils had been unreactive for more than 8 h before barbiturates were given. A large dose was given in order to keep the EEG isoelectric for at least 24 h; however no EEG or CFM control was available at that time and it was considered unacceptable to delay barbiturate therapy further for this reason. The difficulties of neurological assessment during high dose barbiturate therapy and controlled ventilation have been mentioned; such assessment can therefore be of no assistance in titrating the dose of barbiturates or the patient's response to therapy.

The large dose which was given (over 31 g thiopentone during 20 h) may have contributed to the good recovery made by this patient with relatively little residual disability despite her poor initial condition and the long delay before therapy was started. This suggests that the consequences of a long delay might have been partly overcome by using such high doses. The case also indicates the lack of any specific 'toxic' effects of high doses of barbiturates. However, cardiovascular depression can be troublesome and careful maintenance of cardiac output, cerebral perfusion pressure, urine output and peripheral perfusion using cardiotoxic drugs was required.

Such patients are completely immobile with little muscle tone and require meticulous attention; this patient developed a hypostatic pneumonia despite our efforts regarding ventilation and physiotherapy, which further delayed her recovery.

The plasma potassium concentration was persistently low during the first day of barbiturate therapy; the plasma osmolality and sodium were high for a few days (Fig. 1). The reason for these changes is not clear; less than 160 mmol sodium were given as thiopentone.

The large difference between the intracranial pressures by epidural transducers on the two sides before barbiturates were given is striking, as was the apparent ineffectiveness of removing the bone flap on the right in decompressing the left hemisphere, where the pressure not only failed to fall but continued to rise to over 20 mmHg during the next 5 days. The left epidural pressure fell initially when thiopentone was given; the later rise may be related to the development of the left frontal infarct, or to a recurrence of global cerebral oedema associated with tolerance to barbiturates and falling blood

thiopentone levels as well as to the return of muscle tone and straining against the ventilator.

The development of transient aphasia with a persistent hemiplegia on the side of the operation is perhaps remarkable; it is not accounted for by occlusion of the anterior cerebral artery which was known to have occurred during surgery. It may, however, be explained by occlusion or vasospasm associated with thrombosis of the left recurrent artery of Heubner. This vessel, usually arising from the anterior cerebral artery, has branches supplying the anterior limb of the internal capsule as well as parts of the basal ganglia, anterior hypothalamus, uncinata fasciculus and olfactory regions. Its occlusion is known to result in hemiparesis with severe weakness of the arm, mild weakness of the face, tongue and palate and aphasia if the artery is on the dominant side.<sup>8</sup> The origin and anatomy of the artery and its branches are known to be variable; they may arise from the internal carotid bifurcation, middle cerebral artery or anterior communicating artery. They are seldom seen on angiography or during surgery especially without the use of a microscope and are therefore very vulnerable to the effects of manipulation during dissection of an aneurysm.

## Case 2

The patient, a female aged 40 years, had a subarachnoid haemorrhage with sudden onset of headache and vomiting but with no loss of consciousness. On admission to the Neurosurgical Unit the same day there was no neurological deficit or neck stiffness; there were no other relevant findings. She had previously been well except for mild hypertension in the last 2 yr which had been treated only with a low salt diet.

Seldinger angiography revealed a midline aneurysm of the anterior communicating artery and evidence of marked vasospasm in the first part of the right middle cerebral artery, the last part of the right internal carotid artery and in the right anterior cerebral artery. She was prepared for operation 19 days after admission. Pre-operative angiography the same morning again showed marked vasospasm of vessels on the right side and was followed by aphasia and a right hemiparesis which resolved completely within 6 h. Surgery was postponed and performed 16 days later without further angiography.

The patient was premedicated with atropine, pethidine, promethazine and chlorpromazine. Anaesthesia was induced with an infusion containing 3 g thiopentone (50 mg/kg). Suxamethonium was used to facilitate intubation and anaesthesia was continued with pethidine 200 mg, pancuronium and ventilation with 33% O<sub>2</sub>, 67% N<sub>2</sub>O. The 3 g thiopentone infusion was given over 40 min and was completed before cooling was begun. Anaesthetic management was otherwise similar to that described in Case 1. Cerebral activity was recorded preoperatively with a CFM.

A right frontal craniotomy was performed and 120 ml CSF were drained after the dura was opened. The mean arterial pressure did not drop below 75 mmHg (90 mmHg systolic) at any time and cardiotoxic drugs were not required. No hypotensive drugs were given. The serum thiopentone level after the end of the infusion was 55 mg/litre. During dissection of the aneurysm the oesophageal temperature was 28.3°C, the serum thiopentone level was between 18 and 24 mg/litre, the lumbar CSF thiopentone level was about 2 mg/litre and the CFM baseline was 2 microV.

The aneurysm involved the origins of both anterior cerebral arteries as well as two other arteries supplying the hypothalamus and mid-brain so that it would have been impossible to exclude it from the circulation without permanently occluding one or more of these. The aneurysm was therefore wrapped in a piece of temporal muscle and no attempt was made to clip its neck. The patient was rewarmed. During closure an epidural transducer was placed in one of the burr holes; it recorded 3 mmHg immediately postoperatively. The patient was left intubated, transferred to the Intensive Therapy Unit with a temperature of 36°C and was ventilated for 6 h. After this time she was fully awake with no apparent neurological deficit and was extubated; the serum thiopentone level was 7 mg/litre. Recovery was uneventful except for the development of a partial right third nerve palsy and ptosis 2 days postoperatively. These resolved over the following few weeks.

### Discussion

The development of a hemiplegia and aphasia following angiography in this patient suggested that she would be especially vulnerable to the

effects of vasospasm associated with manipulation during surgery. For this reason it was decided to give her a loading dose of 50 mg/kg thiopentone prophylactically since pretreatment might be expected to yield better results than giving barbiturates after the cerebral circulation has already been compromised. In addition, loading a patient at induction avoids the necessity of giving large doses of intravenous barbiturates while the patient is hypothermic, when troublesome cardiovascular depression might be anticipated. The case illustrates the feasibility of giving this dose of thiopentone together with hypothermia, in this case resulting in a serum level of about 20 mg/litre thiopentone at 28.3°C. Experimental work suggests<sup>1</sup> that such a combination may be more effective than the use of either alone in protecting the brain against ischaemic damage.

A loading dose 50 mg/kg seems to be satisfactory as there was no significant cardiovascular depression or delay in postoperative recovery while the CFM baseline was adequately depressed to 2 microV, corresponding to a burst-suppression EEG (Fig. 3, Case 1). Less narcotic is necessary when a loading dose of barbiturate is given.

The development of a transient, partial third nerve palsy and ptosis 2 days postoperatively is perhaps remarkable and raises the question of whether these might have been apparent immediately postoperatively and been more persistent in the absence of barbiturate therapy.

The authors suggest that the procedure used in this case merits further evaluation for routine use in cerebral aneurysm surgery where the precise operative procedure and its consequences and thus the risk to the patient cannot always be assessed preoperatively.

### Acknowledgments

The authors wish to thank the following members of the Department of Neurosurgery for the help they gave at various stages during the preparation of this paper: Dr J. Wilmink, Mr D. Buitter, Mrs J.M. Newton for typing the manuscript and Professor J.W.F. Beks for permission to present his patients.

### References

1. BELOPAVLOVIC M, BUCHTHAL A. Barbiturate therapy

- in cerebral ischaemia. *Anaesthesia* 1980; **35**: 235-245.
2. MARSHALL LF, SMITH RW, SHAPIRO HM. The outcome with aggressive treatment in severe head injuries. The significance of intracranial pressure monitoring. *Journal of Neurosurgery* 1979; **50**: 20-25.
  3. MARSHALL LF, SMITH RW, SHAPIRO HM. Acute and chronic barbiturate administration in the management of head injury. *Journal of Neurosurgery* 1979; **50**: 26-30.
  4. BRUCE DA, GENNARELLI TA, LANGFITT TW. Resuscitation from coma due to head injury. *Critical Care Medicine* 1978; **6**: 254-269.
  5. MARSHALL LF, SHAPIRO HM, RAUSCHER A, KAUFMAN NM. Pentobarbital therapy for intracranial hypertension in metabolic coma. Reye's syndrome. *Critical Care Medicine* 1978; **6**: 1-5.
  6. SHAPIRO HL, WYTE SR, LOESER J. Barbiturate-augmented hypothermia for reduction of persistent intracranial hypertension. *Journal of Neurosurgery* 1974; **40**: 90-100.
  7. BREIVIK H, SAFAR P, SANDS P, FABRITIUS R, LIND B, LUST P, MULLIE A, ORR M, RENCK H, SNYDER JV. Clinical feasibility trials of barbiturate therapy after cardiac arrest. *Critical Care Medicine* 1978; **6**: 228-244.
  8. SHAPIRO HM, GALINDO A, WYTE SR, HARRIS AB. Rapid intraoperative reduction of intracranial pressure with thiopentone. *British Journal of Anaesthesia* 1973; **45**: 1057-1062.
  9. PERLMUTTER D, RHOTON AL. Microsurgical anatomy of the anterior cerebral-anterior communicating-recurrent artery complex. *Journal of Neurosurgery* 1976; **45**: 259-272.