

Cerebral Fat Embolism: A Neuropathological Study of a Microembolic State

477

ELIZABETH KAMENAR, M.D., AND PETER C. BURGER, M.D.

SUMMARY Multiple cerebral petechiae associated with intravascular globules of neutral fat and localized primarily within the white matter are distinctive lesions which secure the pathologic diagnosis of cerebral fat embolism. The abundance of these lesions in an unknown, but presumably small, percentage of cases of fat embolism, along with the even more widespread distribution of embolic fat droplets throughout both white and gray matter, suggest that these lesions and emboli must have a profound effect on neurologic function. Nevertheless, respiratory insufficiency is by far a more common clinical manifestation of the fat embolism syndrome and the neurologic involvement of such patients is often attributed to the secondary effects of generalized hypoxia. The following patient with overt respiratory and neurologic symptoms re-emphasizes the direct primary effect of fat emboli within the central nervous system as a cause of white matter hemorrhages and neurologic deterioration. Explanations for the selectivity of the lesions for the cerebral white matter are explored.

Stroke, Vol 11, No 5, 1980

FOR OVER A CENTURY, fat embolization has been recognized as a potentially serious, but poorly understood, sequela of skeletal trauma. Relative to the frequent subclinical embolization of fat droplets following fractures,^{1, 2} the "fat embolism syndrome" is less common and is unpredictable in the severity with which it affects the major target organs, the lungs and the brain. Because of its greater incidence, the pulmonary, rather than the cerebral, component has received primary attention in clinical and experimental studies which attempt to define the relationship between embolic intravascular fat and clinical disease.³ In contrast to the lung, however, the brain may present more distinctive, if not diagnostic, pathologic lesions in this syndrome. With the aid of an illustrative patient, this discussion reviews cerebral fat embolism from the perspective of the pathologist and surveys our incomplete understanding of its pathogenesis.

Patient Presentation

The patient was a 45-year-old man who sustained in an automobile accident multiple right-sided rib fractures and a comminuted fracture of the right femur. He did not lose consciousness. After initial treatment for shock at an outside hospital, he was transferred to Duke University Medical Center where his blood pressure on admission was 120/80 mm Hg, pulse 120/min, and respiratory rate 28/min. He was dyspneic, but neurologically intact except for anisocoria (right 4 mm, left 2 mm). Arterial blood gases revealed a Po_2 of 51 mm Hg, O_2 saturation of 83%, pH of 7.31, HCO_3 of 14 mEq/l, and a Pco_2 of 28 mm Hg. Bilateral pneumothoraces were noted; he was intubated and chest tubes were placed. Alveolar densities were also seen throughout both lung fields. His right leg was splinted in traction.

Four hours after arrival (12 hours after the accident), he became lethargic and responded to pain

with semipurposeful movements of all extremities. His pupils, which were unchanged in size, reacted slowly to light; the fundi were normal. Deep tendon reflexes were 3+ bilaterally except for the right leg which could not be tested. Toes were upgoing and there was sustained ankle clonus on the left. Skull and cervical spine films were normal; a CAT scan revealed a slight compression of the right lateral ventricle which was attributed to cerebral edema. There was no midline shift. Blood gases were Po_2 100 mm Hg, pH 7.28, Pco_2 34 mm Hg, HCO_3 15 mEq/l, and O_2 saturation 95%.

Because of abdominal tenderness and a peritoneal lavage which returned bright red blood, an exploratory laparotomy was performed, but no lesions were encountered. A chest x-ray in the recovery room showed bilateral fluffy densities. The patient remained obtunded.

Twenty-two hours after the accident, he developed myoclonic jerks. An EEG was diffusely abnormal with greater amplitudes on the left. Mild hypotension responded to vasopressors. His blood gases deteriorated but with the use of a volume respirator with a 60% FIO_2 , the Po_2 rose to 190 mm Hg. The Pco_2 , however, was difficult to control and gradually rose to high of 104 mm Hg. The patient's vital signs and blood gases were stabilized over the 5 hours preceding his death with the Pco_2 in the 50–60 mm Hg range. He then developed bradycardia, asystole, and expired 42 hours after the accident.

Autopsy Findings

Evidence of recent trauma to the face, trunk, and extremities was obvious externally. Multiple posterior rib fractures were present on the right and there was a fracture of the right femoral shaft with soft-tissue swelling and hemorrhage. The 650 gm right lung was crepitant throughout except for a $7.0 \times 3.0 \times 1.5$ cm firm, hemorrhagic area of the right lower lobe consistent with a contusion. From the remaining parenchyma, pink frothy material could be expressed and there were multiple, widely scattered 3–10 mm hemorrhagic foci within all lobes. The 750 gm left lung

From the Department of Pathology, Box 3712, Duke University Medical Center, Durham, NC 27710.

Dr. Kamenar's present address is Department of Neurology, Cleveland Clinic Foundation, Cleveland, OH 44106.

was similar to the right with multiple small hemorrhages and a $4 \times 4 \times 3$ cm hemorrhagic area anteriorly in the upper lobe. Microscopically, both lungs had intra-alveolar edema and blood in the grossly hemorrhagic areas and mild edema or unremarkable parenchyma elsewhere. Oil red O and osmium stains revealed numerous bilateral, widely distributed intravascular globules of fat within arterioles, capillaries, and venules. The emboli were not concentrated in the hemorrhagic areas. The heart was not dilated and there were no septal defects.

The 1,560 gm brain gave no external evidence of asymmetry or herniation. Innumerable petechiae were dispersed over the pial surface of the cerebellum (fig. 1). The cerebrum was externally unremarkable.

Internally, petechiae up to 2–3 mm in diameter diffusely stippled the white matter of the cerebral hemispheres but conspicuously avoided the cerebral cortex and deep nuclei (fig. 2). A few were subependymal. In the cerebellum, in contrast to the cerebrum, petechiae involved both the white matter and gray matter (fig. 3). They were also randomly scattered throughout the brain stem and rapidly decreased in number through the medulla and spinal cord. Where there was intermingling of nuclei and fiber tracts within the brain stem, it was difficult to assign petechiae to either the white matter or gray matter by gross examination (fig. 4).

Microscopically, the petechiae in any site consisted of ball, ring, or perivascular hemorrhages with their long axes usually parallel to the myelinated fibers. Ball hemorrhages, which varied from 2.0 mm to less than 1.0 mm, were solid round-to-oval collections of erythrocytes occasionally associated with one or more vessels. Macrophages and a few polymorphonuclear leukocytes were noted centrally within many of these hemorrhages. The ring hemorrhages, usually a millimeter or less in size, were also infiltrated by inflammatory cells, but, in contrast, contained a central amorphous area of necrosis in which the remnants of a small vessel were sometimes apparent (fig. 5). Perivascular hemorrhages consisted of a sleeve of red cells about a centrally placed vessel. The distinction

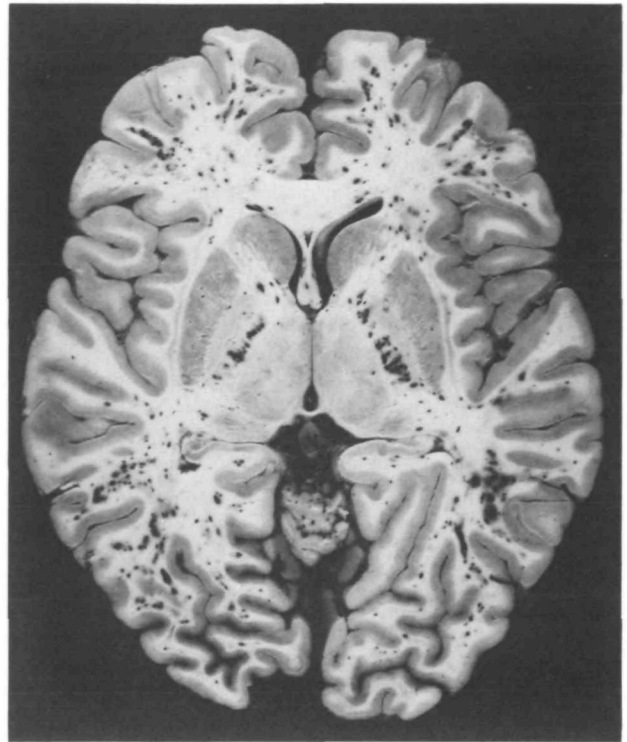


FIGURE 2. Diffuse white matter petechiae with sparing of the gray matter are the classic lesions of cerebral fat embolism. Note this selectivity for white matter in the posterior limb of the internal capsules adjacent to the minimally involved globus pallidus and thalamus.

between these 3 types of hemorrhages or hemorrhagic microinfarcts was sometimes arbitrary, and it is likely that some ball hemorrhages were tangential sections of the ring type.

All 3 types of hemorrhagic lesions were individually scattered throughout the cerebral and cerebellar white matter, cerebellar cortex, and brain stem with a minor tendency to cluster in a few areas. In the cerebellar cortex, the hemorrhages were slightly more variable in shape as they flattened out along anatomical lines of

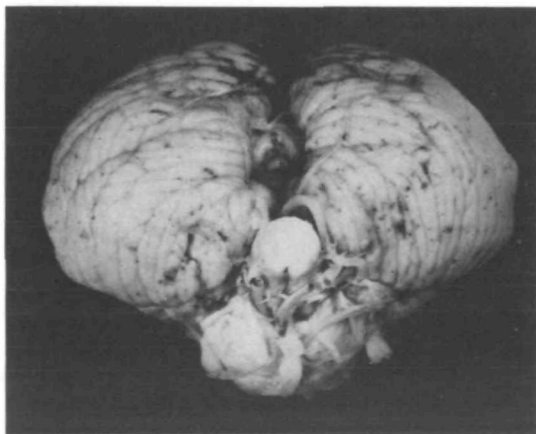

FIGURE 1. Petechiae on the cerebellar surface may be an external manifestation of cerebral fat embolism.

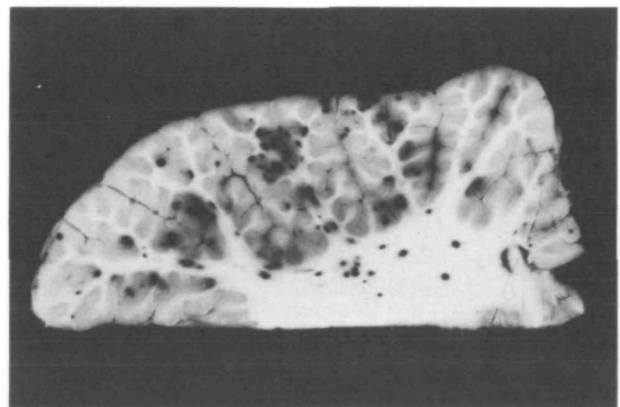


FIGURE 3. In the cerebellum, petechiae may involve both the cortex and white matter. The more superficial lesions are apparent externally in figure 1.

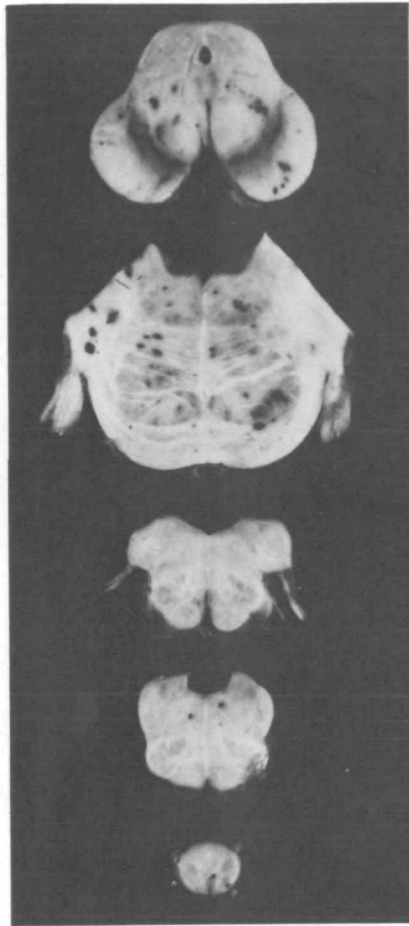

FIGURE 4. *Petechiae in the brainstem and spinal cord decrease in number with progression caudally.*

the molecular, Purkinje, and granular cell layers. They also involved the cerebellar subarachnoid space. Although the hemorrhages in the brain stem often extended into adjacent gray matter, they seemed to be centered within the white matter. The few hemorrhages noted in the spinal cord, cerebral cortex and deep nuclear masses did not include those of ring type.

Much less frequent than the hemorrhages were the anemic lesions which were almost as common in the cerebral gray matter as in the cerebral white matter. Elsewhere, their distribution was similar to that of the hemorrhages. In the white matter, they were irregular, often spongy, areas containing eosinophilic swollen axis cylinders surrounded by ballooned myelin sheaths (fig. 6). These varied from 4 mm to less than 1 mm. A few of the larger areas of coagulative necrosis followed the path of, and surrounded, larger penetrating arteries. In the gray matter, the anemic lesions were small, ill-defined, spongy, pale areas which contained hypereosinophilic, "ischemic" neurons. These anemic microinfarcts were randomly distributed within the cerebral cortex (fig. 7).

Multiple sections of cerebral and cerebellar cortices and of the hippocampi disclosed no laminar necrosis, diffuse Purkinje cell loss, or Sommer sector necrosis suggestive of a systemic hypoxic/ischemic insult.

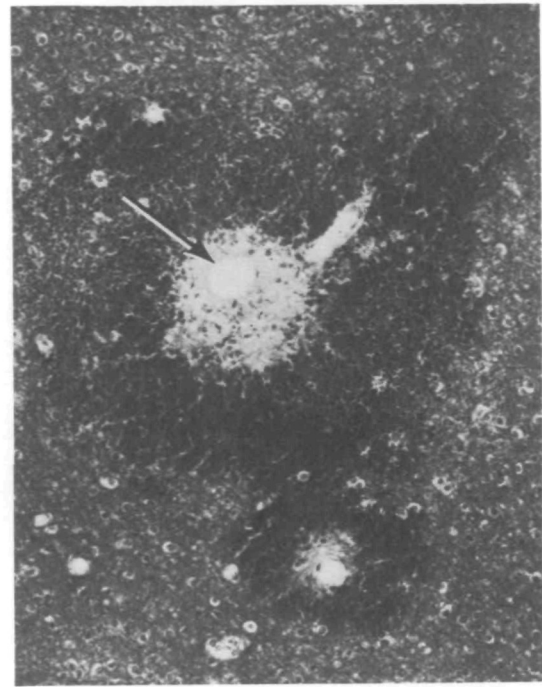


FIGURE 5. *The erythrocytes of ring hemorrhages surround central zones of necrosis. A vessel cut longitudinally enters the center of the larger lesion (top right) which contains a discrete hole (arrow). This space was previously occupied by fat which has been dissolved out in processing. The smaller lesion is similar. (Hematoxylin and eosin/Luxol fast blue, X 130.)*

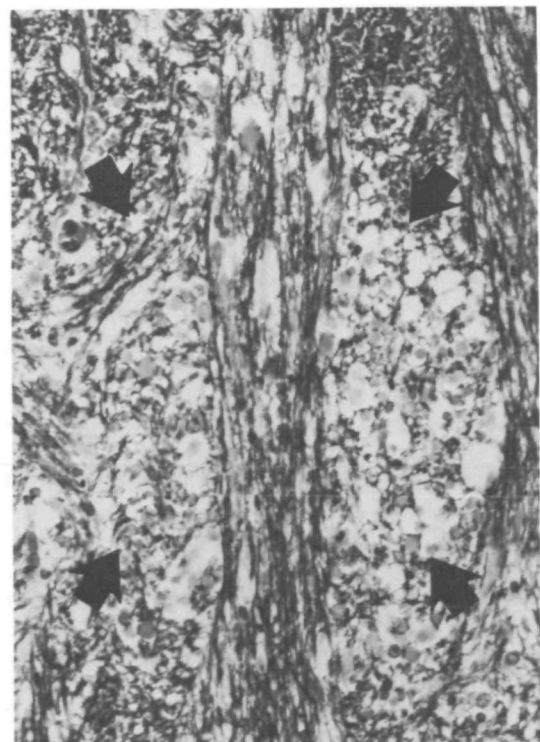

FIGURE 6. *A focal white matter anemic microinfarct (arrows) is illustrated in the compact fiber tracts of the brainstem. The injured axons are glassy, pink, large, round and surrounded by ballooned myelin sheaths. (Hematoxylin and eosin/Luxol fast blue, X 200.)*

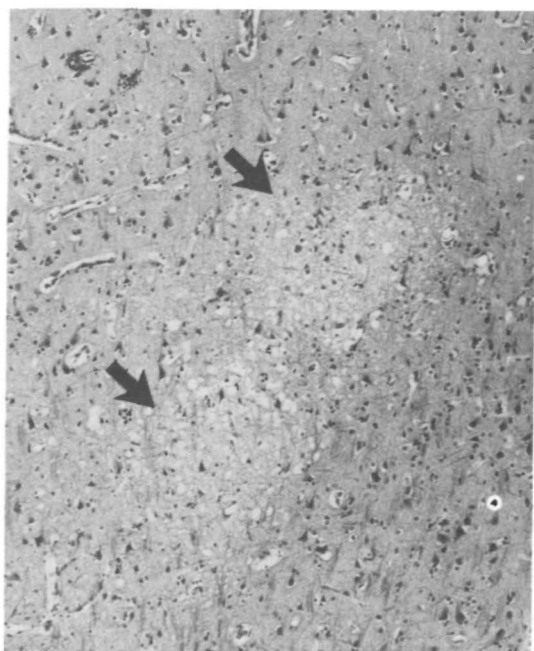


FIGURE 7. The anemic microinfarcts of the cortical gray matter (arrows) of fat embolism are characterized by the focal sponginess of the neuropil. Hyper eosinophilic neurons may be found in these lesions. (Hematoxylin and eosin/Luxol fast blue, $\times 80$.)

In all paraffin-embedded sections, the presence of embolic fat within lesions or vessels was inferred from the appearance of empty circular or oval spaces which displaced and compressed the surrounding cells and tissue (fig. 5). Oil red O and osmium stains confirmed the presence of discrete fat globules within the hemorrhagic lesions (fig. 8) as well as in small vessels throughout the brain (fig. 9). There was no consistent relationship between fat globules and the anemic microinfarcts, although for some, globules were concentrated in the capillaries at the perimeter. The irregular distribution of fat droplets within a given anatomic region made comparisons somewhat difficult, but they were clearly more numerous in the cerebral cortex than in the underlying deep white matter by a ratio of almost 4:1. This ratio was determined from the total number of fat emboli counted in 20 separate 1 mm² areas at 100 \times magnification in both the cortical gray and underlying white matter from each lobe of both cerebral hemispheres (table). In the cerebellum, they were present in numbers roughly proportional to the capillary density and were, therefore, most plentiful in the Purkinje and granular cell layers. In any cerebellar layer, most petechiae contained globules of fat. Some of the petechiae in the brain stem were also associated with local fat emboli.

Fat emboli within the microvasculature were best appreciated in a flat retinal preparation stained with oil red O where the emboli in arterioles sat as globules or long cylinders branching and filling successively smaller vessels (fig. 10). Fat droplets were abundant in the renal glomeruli, but were also seen in the myocar-

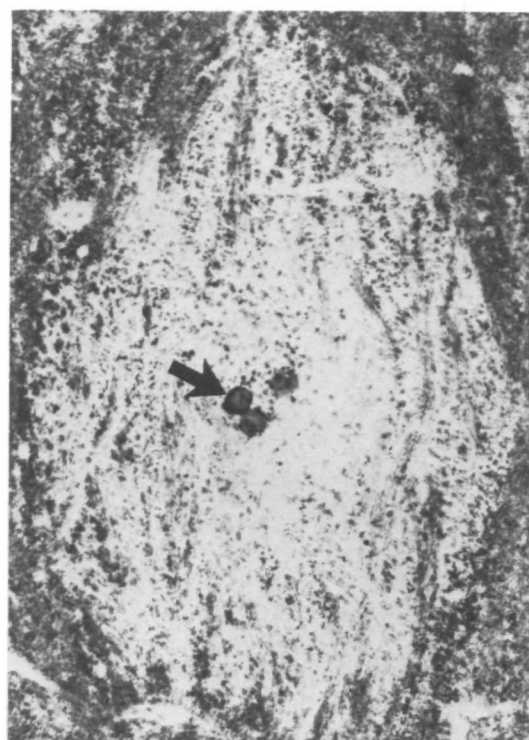


FIGURE 8. If serial sections are performed, central fat globules (arrow) may be found within many white matter hemorrhages. (Frozen section, oil red O/hematoxylin, $\times 170$.)

dium, liver, pancreas, and gastric mucosa. In contrast to the brain, the emboli in these viscera or the retina were not associated with structural alterations of the vessels or parenchyma.

Discussion

Since the clinical diagnosis of cerebral fat embolism must usually be made in the presence of hypoxemia, hypotension, and/or possible cranial trauma, it is rarely made with certainty and should be considered only after other causes of post-traumatic neurologic deficit are remedied or excluded. The diagnosis is

TABLE Number of Cerebral Fat Emboli/20 mm²

	Cortex	White Matter
Right Frontal	109	26
Left Frontal	126	44
Right Parietal	122	31
Left Parietal	81	18
Right Occipital	125	15
Left Occipital	78	25
Right Temporal	19	9
Left Temporal	38	16
Total	698	184

Cortex
White Matter = 3.8

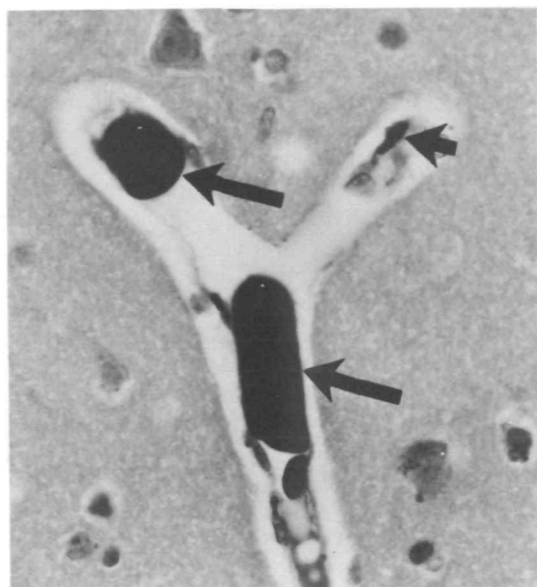


FIGURE 9. Fat globules within the lumen of small vessels (long arrows) are the hallmarks of fat embolism. Lipid accumulation within cerebral endothelial cells on the other hand (short arrow) is a common finding in normal brains and should not be interpreted as fat emboli. (Osmium, $\times 480$.)

nevertheless suspected in the classic case of the "fat embolism syndrome" in which long bone fracture and a 12- to 48-hour symptom-free interval are followed by respiratory distress, fever, tachycardia, a characteristic petechial rash, and neurologic dysfunction progressing to coma, and perhaps to death. Some cases may deviate from the classic evolution by the absence or abbreviation of the latent interval, or by a marked predominance of respiratory or, less commonly, neurologic symptomatology. The latter may consist of impairment of consciousness, seizures, pyramidal signs, decerebrate rigidity, and focal neurologic signs.⁴⁻⁷ Although there is no single pathognomonic clinical finding, systemic fat embolism may be best demonstrated by ophthalmoscopy⁸ or skin or renal biopsy.^{1, 8} Detection of fat globules in urine,^{5, 9-11} sputum,^{6, 9, 11, 12} cerebrospinal fluid¹¹ or blood^{10, 11} is an unreliable diagnostic aid.

Considerable support for the diagnosis of clinically significant cerebral fat embolism is found at autopsy if gross examination of the brain reveals multiple petechiae in the white matter. Characteristically, these minute hemorrhages are most abundant in the centrum semiovale, digitate white matter, internal capsule, and cerebellar white matter, but may also be noted in the brain stem and spinal cord. Generally, the gray matter is notably spared or only minimally involved but, occasionally, it may be more conspicuously affected.^{4, 13-16} This is particularly true of the cerebellar cortex as seen in the above case. White matter petechiae, however, are not definitive evidence of cerebral fat embolism as they may occur in other conditions including hypoxic-ischemic leukoenceph-

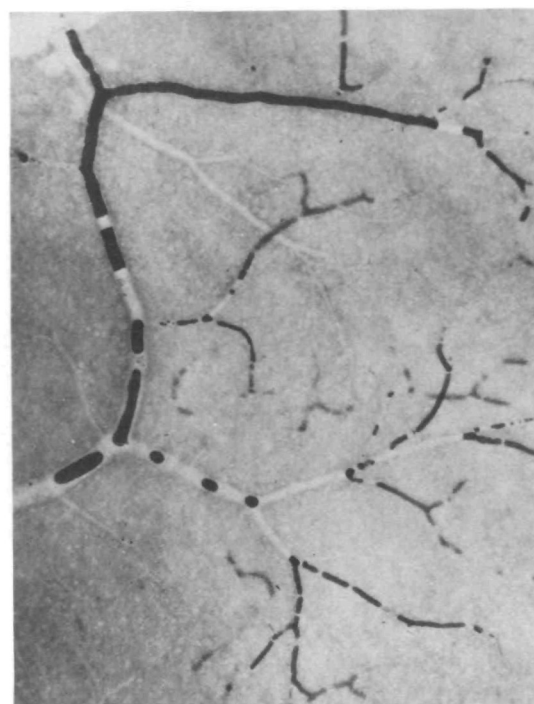


FIGURE 10. The length and deformable nature of fat emboli within the microvasculature is well appreciated in a whole mount preparation of the retina stained with oil red O. No apparent pathologic effect on the retina was noted during life or at post-mortem examination in this case. (Oil red O, $\times 100$.)

alopathy,^{17, 18} acute hemorrhagic leukoencephalitis,¹⁹ white matter watershed infarcts,²⁰ some cases of head trauma,^{4, 21} malaria,²² air embolism,^{23, 24} and intoxication with organic arsenicals,^{25, 26} carbon monoxide,²⁷ and morphine.²⁸ The firm diagnosis requires confirmation by light microscopy.

As illustrated above, the classic histologic lesions of cerebral fat embolism are ball, ring, and perivascular hemorrhages which are usually apparent to the naked eye as petechiae. The less obvious and usually less frequent anemic lesions become conspicuous on microscopic examination, especially with the application of a myelin stain. Occasionally they may predominate numerically.^{4, 29-31} With time, the hemorrhages also may become less obvious grossly as they undergo resolution. Microscopically, the latter may have a cellular reaction within 2 days consisting mostly of mononuclear cells. This is followed later by the appearance of gitter cells, reactive astrocytes, and hemosiderin.⁴ Based on long-term survivals (3 months³² and 7 years³³) following presumed cerebral fat embolism, more advanced lesions may be sufficiently contractile in aggregate to produce gross white matter atrophy. Although any of these histologic findings, especially ball and ring hemorrhages, support the possibility of cerebral fat embolism, they are nonspecific and an absolute diagnosis rests on the demonstration of intravascular fat.

The presence of this substance may be inferred from

paraffin-embedded sections by empty round spaces which displace and compress the surrounding cells (fig. 5), but fat stains are needed for confirmation. With oil red O or osmium stains, globules can be visualized within arterioles or capillary-sized vessels throughout the brain and spinal cord. These globules are often located in the center of the ring and ball hemorrhages, but are usually more plentiful within vessels of the gray matter where lesions are less common. The significance of diffuse intravascular fat in the absence of associated hemorrhages or microinfarcts is unclear, although some studies suggest that such involvement could produce neurologic deficit or death.³⁴⁻³⁶ Timing is important in the identification of the intracerebral fat for, in contrast to the lung, hours must usually elapse following trauma before fat is detected in the cerebral vessels. In addition, embolic cerebral fat may largely disappear by the end of the subsequent week.⁴ The presence of the characteristic CNS petechiae without demonstrable CNS fat emboli should prompt a search for fat emboli in the lung and especially other systemic organs such as the kidney, posterior pituitary, or a flat preparation of the retina.

With the appropriate clinical setting and distinctive gross and microscopic features as described above, cerebral fat embolism is seen by the pathologist as a well-defined clinicopathologic state. There is very little else about fat embolism, either clinically or pathologically, that can be considered as "well-defined." Since the "fat embolism syndrome" more commonly manifests itself as a "respiratory distress syndrome of shock and trauma,"^{37, 38} the clinical significance of cerebral fat embolism tends to be minimized. Some attribute any neurologic deficit and even the cerebral petechiae to secondary effects of generalized hypoxia resulting from the pulmonary fat embolization.^{2, 37, 39-43}

The pathogenesis of the cerebral lesions associated with the fat embolism syndrome has not been adequately explained; the source of the emboli themselves has even been a matter of debate. Most believe that these globules originate at the site of the fracture and are conveyed by the venous circulation to the lungs where, by passage through small pulmonary vessels, some gain entrance to the systemic circulation.^{44, 45} An alternative theory suggests an origin from the coalescence of serum lipids.

Whatever the genesis of fat emboli, the ischemic character of many cerebral lesions suggests that the latter are direct expressions of small vessel occlusion by the fat droplets. The association of the droplets with the lesions has been a consistent observation in most reported cases,^{4, 7, 31, 46, 47} and unless the lesions pre-exist and trap the circulating droplets, a cause and effect relationship seems logical. This hypothesis would receive support if the character and topography of the lesions of cerebral fat embolism were duplicated by some other human microembolic state, ideally one in which concurrent pulmonary emboli and hypoxia could be excluded. Unfortunately, in many cases the lesions associated with these other emboli are incompletely documented or differ in some critical detail

from those of fat embolism. Thus, the recorded lesions associated with lipid contrast material^{48, 49} and silicone^{50, 51} are either too few, too anemic, or too indiscriminate in their gray/white involvement to be considered analogues of cerebral fat embolism. Cerebral air embolism varies in the descriptions of its pathology as well as in the apparent validity of the diagnosis.^{11, 24, 51-53} However, cerebral fat emboli may occur following cardiopulmonary bypass and produce white matter petechiae as seen in post-traumatic cases.⁵⁴ Silicone emboli can also occur in this setting and, in our experience, can produce multiple anemic and hemorrhagic lesions in the white matter. Cerebral involvement with malaria, although not embolic, is a diffuse micro-occlusive state with ring and ball hemorrhages preferentially localized to the white matter similar to that of cerebral fat embolism.^{22, 55} Thus, although there is need for more documentation, there is some evidence that other deformable microemboli may produce white matter petechiae in some cases.

If the cerebral lesions of fat embolism are expressions of ischemia, the preferential localization of the petechiae to the cerebral white matter remains a paradox since it is here that emboli are usually less frequent. Explanations have focused on the gray matter's rich vascularity which could have sufficient anastomotic potential to protect itself against the ischemic effects of microemboli,⁴ although such a protection may have an upper limit.⁵⁶ Although this consideration of the anatomy of the vascular bed would offer the simplest explanation for the white matter predominance of the petechiae, it has also been suggested that the white matter lesions are produced indirectly by cortical emboli through venous sludging and white matter edema.⁵⁷

Experimental studies of fat embolization are numerous, but only a few have investigated the pathogenesis of the cerebral lesions. The latter have included injections of a variety of oily substances given by the carotid, intravenous, or intraperitoneal routes. Lipids used have included mayonnaise,⁵⁸ olive oil,^{59, 60} animal fat,^{61, 62} Wesson oil,^{63, 64} and cottonseed oil.⁶⁵ Other experiments relevant to cerebral fat embolism are embolization of silicone,⁶⁶⁻⁶⁸ air,⁶⁹ and non-deformable microspheres of plastic⁶⁷ and paraffin.⁷⁰ As a summary of these experiments, it can be said that microembolization to the brains of small laboratory animals may produce focal lesions which are both small and large, anemic and hemorrhagic, and located in both gray and white matter. The types of hemorrhages have not always been well-characterized although ring hemorrhages are seemingly rare. The small anemic type of lesions in both gray and white matter are most common. Thus, based on a limited body of evidence, experimental microembolization produces, in some instances, small focal lesions, sometimes with a hemorrhagic character, but not the white matter predominance of human cerebral fat embolism.

The embolic/ischemic hypothesis of cerebral fat embolism has been modified by suggestions that there

is a synergism between cerebral fat emboli and some other local or systemic influence. Among the latter are increased venous pressure in the superior vena cava secondary to the pulmonary fat emboli,^{49, 71, 72} coagulopathy,^{73, 74} hypotension,⁷² hypoxia,^{2, 3, 75} vasoconstriction,⁷² and toxic metabolites of lipids.⁷⁶ These secondary factors have not been rigorously studied in the context of either human or experimental cerebral fat embolism, although some have been the subject of much interest with respect to the lung.

The role of free fatty acids has received particular attention with regard to pulmonary fat embolism⁷⁷ and warrants consideration in the pathogenesis of the cerebral lesions. Briefly, it suggests that hydrolysis of embolic neutral fat by tissue or circulating lipases releases free fatty acids which exert a toxic effect on the alveolar-capillary membrane.^{78, 79} The time required for the accumulation of these acids has been employed to explain the classic latent interval between the patient's injury and the onset of respiratory distress, while the hemorrhagic character of the pulmonary disease is attributed to the aforementioned toxic effect of the free fatty acids on the pulmonary vasculature. The hemorrhagic pulmonary lesions produced by intravenous administration of free fatty acids, and the observation that similar doses of neutral fat have considerably less effect, are proffered as supportive experimental evidence.^{78, 80, 81} It must be recognized, however, that hemorrhagic pulmonary lesions can also be produced by mineral oil which is metabolically inert.⁸² Furthermore, the lungs of patients with pulmonary fat embolism have no consistent or well-defined changes that distinguish it from other etiologies that are common in the post-traumatic setting.^{1, 4, 34, 46, 83} In the present patient, for example, there was extensive intravascular fat, but relatively minimal intra-alveolar edema and hemorrhage. It seems, therefore, that an endpoint of hemorrhagic pulmonary edema may have been utilized too liberally as an experimental duplicate of the human pathology. In the brain, the fatty acid hypothesis should be accepted with even more reservation since hemorrhagic lesions are rare in the cortex where there are many emboli and common in the white matter where emboli are less numerous. Also, as noted above, silicone embolism may, in some instances, produce similar hemorrhagic white matter lesions.

Since cerebral fat embolism is usually associated with, and often overshadowed by, coexistent respiratory insufficiency and other complications of trauma such as shock, investigation of the pathogenesis of the lesions of cerebral fat embolism should consider both the local effects of embolic fat as well as the influences on the brain of hypoxia and hypotension. Although neither this case nor most other cases of cerebral fat embolism exhibit the classic features of hypoxia/hypotension such as necrosis in the basal ganglia, Sommer's sector, Purkinje cell layer, or specific cortical laminae, there are rare hypoxic/ischemic states which are characterized pathologically by white matter hemorrhagic infarcts which have similarities to those of cerebral fat em-

bolism.^{17, 18} The absence of embolic fat is critical in differentiating these conditions from cerebral fat embolism. These disorders do, however, suggest the need to consider a synergism between hypoxia/hypotension and embolic fat droplets to produce the characteristic topography of cerebral fat embolism, although a simple mechanical occlusive effect of fat droplets may be sufficient explanation.

References

1. Sevt S: Reactions to Injuries and Burns and their Clinical Importance. Philadelphia, JB Lippincott Co, 1974, pp 188-217
2. Szabó G: The syndrome of fat embolism and its origin. *J Clin Pathol*, 23, Suppl (Roy Coll Pathol) 4: 123, 1970
3. Weisz GM: Fat embolism. *Curr Problems Surg* 11: 1-54, 1974
4. Sevt S: Fat Embolism. London, Butterworth and Co Ltd, 1962, pp 1-233
5. Peltier LF, Collins JA, Evarts CM, Sevt S: Fat embolism. *Arch Surg* 109: 12, 1974
6. Thomas JE, Ramaswami A: Systemic fat embolism. *Arch Neurol* 26: 517, 1972
7. Silverstein A: Significance of cerebral fat embolism. *Neurology* 2: 292, 1952
8. Adams CBT: The retinal manifestations of fat embolism. *Injury* 2: 221, 1971
9. Moylan JA, Evenson MA: Diagnosis and treatment of fat embolism. *Ann Rev Med* 28: 85, 1977
10. Fuchsig P, Brücke P, Blümel G, Gottlob R: A new clinical and experimental concept on fat embolism. *N Eng J Med* 276: 1192, 1967
11. Tedeschi LG, Hechtman HB: Post-traumatic embolism. *In* Tedeschi CG, Eckert WG, Tedeschi LG (eds) *Forensic Medicine*. Philadelphia, WB Saunders Co, 1977, Vol. 1, pp 406-422
12. Vance BM: The significance of fat embolism. *Arch Surg*, 23: 426, 1931
13. Russell D: Discussion on fat embolism and the brain. *Proc Roy Soc Med* 34: 645, 1941
14. Silverstein A, Konzelman F: Cerebral fat embolism. *Confinia Neurol* 3: 129, 1940
15. Gauss H: Studies in cerebral fat embolism. *Arch Int Med* 18: 76, 1916
16. Cammermeyer J: Cerebral changes in an acute case of fat embolism. *Acta Psych et Neurol* 12: 333, 1937
17. Burger PC, Vogel FS: Hemorrhagic white matter infarction in three critically ill patients. *Human Pathol* 8: 121, 1977
18. Ginsberg MD, Hedley-Whyte T, Richardson EP: Hypoxic-ischemic leukoencephalopathy in man. *Arch Neurol* 33: 5, 1976
19. Oppenheimer DR: Demyelinating Diseases. *In* Blackwood W, Corsellis JAN (eds). *Greenfield's Neuropathology*. Chicago, Year Book Medical Publishers, Inc, 1976, pp 490-495
20. Lindenberg R: Systemic oxygen deficiencies. *In* Minckler J (ed) *Pathology of the Nervous System*. New York, McGraw-Hill Book Co, 1971, Vol 2, pp 1583-1617
21. Courville CB: Pathology of the Central Nervous System. Mountain View: Pacific Press Publishing Assoc, 1945, pp 302-304
22. Escobar A, Nieto D: Parasitic diseases. *In* Minckler J (ed) *Pathology of the Nervous System*. New York, McGraw-Hill Book Co, 1972, Vol 3, pp 2503-2521
23. Courville CB: Pathology of the Central Nervous System. Mountain View, Pacific Press Publishing Assoc, 1945, pp 127-128
24. Englund G: Neuropathology of cardiorespiratory diseases. *In* Minckler J (ed): *Pathology of the Nervous System*. New York, McGraw-Hill Book Co, 1968, Vol 1, pp 997-1005
25. Smith WT: Intoxications, poisons and related metabolic disorders. *In* Blackwood W, Corsellis JAN (eds): *Greenfield's Neuropathology*. Chicago, Year Book Medical Publishers, Inc, 1976, pp 152-153
26. Courville CB: *Forensic Neuropathology*. Mundelein, Callaghan

- and Co, 1964, pp 194-196
27. Brierley JB: Cerebral hypoxia. In Blackwood W, Corsellis JAN (eds): *Greenfield's Neuropathology*. Chicago, Year Book Medical Publishers, Inc, 1976, pp 68-71
 28. Courville CB: *Forensic Neuropathology*. Mundelein, Callaghan and Co, 1964, pp 186-187
 29. Graham DI: Discussion: fat embolism. *J Clin Pathol*, 23, Suppl (Roy Coll Pathol) 4: 149, 1970
 30. Strich SJ: Cerebral Trauma. In Blackwood W, Corsellis JAN (eds): *Greenfield's Neuropathology*. Chicago, Year Book Medical Publishers, Inc, 1976, pp 348-351
 31. Winkelman NW: Cerebral fat embolism. *Arch Neurol Psychiatry* 47: 57, 1942
 32. von Hochstetter AR, Friede RL: Residual lesions of cerebral fat embolism. *J Neurol* 216: 227, 1977
 33. McTaggart DM, Neuburger KT: Cerebral fat embolism: Pathologic changes in the brain after survival of 7 years. *Acta Neuropathol* 15: 183, 1970
 34. Emson HE: Fat embolism studied in 100 patients dying after injury. *J Clin Pathol* 11: 28, 1958
 35. Robinson EF, Soloway HB: Experimental cerebral fat embolism. *Arch Neurol*, 24: 419, 1971
 36. Shaffer JW, Sealy WC, Seaber AV, Hagen PO, Goldner JL: Effects and distribution of acute fat embolism in spontaneously breathing dogs using radioactive carbon triolein. *Surg Gynecol Obstet* 141: 387, 1975
 37. Blaisdell FW, Lewis FR: *Respiratory Distress Syndrome of Shock and Trauma: Post-traumatic Respiratory Failure*. Philadelphia, WB Saunders Co, 1977, pp 23-27
 38. Burgher LW, Dines DE, Linscheid RL, Didier EP: Fat embolism and the adult respiratory distress syndrome. *Mayo Clin Proc* 49: 107, 1974
 39. Weisz GW, Steiner E: The cause of death in fat embolism. *Chest* 59: 511, 1971
 40. Peltier LF: Fat embolism: A pulmonary disease. *Surgery* 62: 756, 1967
 41. Sproule BJ, Brady JL, Gilbert JAL: Studies on the syndrome of fat embolization. *Can Med Assoc J* 90: 1243, 1964
 42. Wertzberger JJ, Peltier LF: Fat embolism: the importance of arterial hypoxia. *Surgery* 63: 626, 1968
 43. Rokkanen P, Lahdensuu M, Kataja J, Julkunen H: The syndrome of fat embolism: analysis of thirty consecutive cases compared to trauma patients with similar injuries. *J Trauma* 10: 299, 1970
 44. Watson AJ: Genesis of fat emboli. *J Clin Pathol* 23, Suppl (Roy Coll Pathol) 4: 132, 1970
 45. Hausberger FX: Effects of lipemia and trauma on experimental fat embolism. *Am J Pathol* 84: 515, 1976
 46. Scully RE: Fat embolism in Korean battle casualties. *Am J Pathol* 32: 379, 1956
 47. Scheinker IM: Formation of demyelinated plaques associated with cerebral fat embolism in man. *Arch Neurol Psychiatry* 49: 754, 1943
 48. Nelson B, Rush EA, Takasugi M, Wittenberg J: Lipid embolism to the brain after lymphography. *N Eng J Med* 273: 1132, 1965
 49. Andersen OF, Fagelberg MG, Rosencrantz NM, Weinfeld VA, Westin JE: Postlymphographic cerebral lipid embolization in the vena cava superior syndrome. *Cancer* 39: 79, 1977
 50. Lindberg DAB, Lucas FV, Sheagren J, Malm JR: Silicone embolization during clinical and experimental heart surgery employing a bubble oxygenator. *Am J Pathol* 39: 129, 1961
 51. Brierley JB: Neuropathological findings in patients dying after open-heart surgery. *Thorax* 18: 291, 1963
 52. Yates PO: Vascular disease of the central nervous system. In Blackwood W, Corsellis JAN (eds): *Greenfield's Neuropathology*. Chicago, Year Book Medical Publishers, Inc, 1976, pp 107-108
 53. Ghatak NR: Pathology of cerebral embolization caused by non-thrombotic agents. *Human Pathol* 6: 599, 1975
 54. Hodge AJ, Dymock RB, Sutherland HD: A case of fatal fat embolism syndrome following cardiopulmonary bypass. *J Thorac Cardiovasc Surg* 72: 202, 1976
 55. Adams JH: Parasitic and fungal infections of the nervous system. In Blackwood W, Corsellis JAN (eds): *Greenfield's Neuropathology*. Chicago, Year Book Medical Publishers, Inc, 1976, p 272
 56. Steegman AT, de la Fuente J: Experimental cerebral embolism. *J Neuropathol Exp Neurol*, 18: 537, 1959
 57. Zülch KJ, Tzonos T: Transudation phenomena at the deep veins after blockage of arterioles and capillaries by micro-emboli. *Bibl Anat* 7: 279, 1964
 58. Hurst EW, Cooke BT: Capillary fat embolism in the brains of sheep, pigs and monkeys, with special reference to demyelination and other lesions in the white matter. *Austral J Exp Biol Med* 21: 141, 1943
 59. Warthin AS: Traumatic lipaemia and fatty embolism. *Int Clinics* 4: 171, 1913
 60. Meriwether LS, Wilson DC: Cerebral fat embolism. *Arch Neurol Psychiatry* 31: 338, 1934
 61. Saldeen T: The importance of intravascular coagulation and inhibition of the fibrinolytic system in experimental fat embolism. *J Trauma* 10: 287, 1970
 62. Harman JW, Ragaz FJ: The pathogenesis of experimental fat embolism. *Am J Pathol* 26: 551, 1950
 63. Cammermeyer J: Cerebral fat embolism with focal siderosis and pericapillary hemorrhages after intraperitoneal injection of oil in cats terminally fixed by perfusion. *Exp Neurol* 55: 694, 1977
 64. Cammermeyer J, Swank RL: Acute cerebral changes in experimental canine fat embolism. *Exp Neurol* 1: 214, 1959
 65. Graham GS: Fat embolism: report of a case and of experiments on animals. *J Med Res* 16: 459, 1907
 66. Penry JK, Cordell AR, Johnston FR, Netsky MG: Experimental cerebral embolism with Antifoam A. *J Thorac Surg* 37: 342, 1959
 67. Cassie AB, Riddell AG, Yates PO: Hazard of antifoam emboli from a bubble oxygenator. *Thorax* 15: 22, 1960
 68. Smith WT: Cerebral lesions due to emboli of silicone antifoam in dogs subjected to cardiopulmonary bypass. *J Path Bact* 80: 9, 1960
 69. De La Torre E, Meredith J, Netsky MG: Cerebral air embolism in the dog. *Arch Neurol* 6: 67, 1962
 70. Swank RL, Hain RF: The effect of different sized emboli on the vascular system and parenchyma of the brain. *J Neuropathol Exp Neurol* 11: 280, 1952
 71. Cammermeyer J: Agonal nature of the cerebral ring hemorrhages. *Arch Neurol Psychiat* 70: 54, 1953
 72. Groszkloss HH: Fat embolism. *Yale J Biol Med* 8: 59, 1935
 73. Serck-Hanssen A: Post traumatic fat embolism. *Acta Pathol Microbiol Scand* 65: 31, 1965
 74. Stehbins WE: *Pathology of the Cerebral Blood Vessels*. St. Louis, CV Mosby Co, 1972, pp 183-187
 75. McNamara JT, Molot M, Dunn R, Strempel J: Clinical fat embolism in combat casualties. *Ann Surg* 176: 54, 1972
 76. Arbus L, Fabre J, Bechae G, Lazorthes Y: Clinical, ophthalmoscopic and biologic findings in systemic fat embolism. *Acta Neurochir* 29: 89, 1973
 77. Peltier LF: Fat embolism — a current concept. *Clin Orthop* 66: 241, 1962
 78. Peltier LF: Fat embolism. III. The toxic properties of neutral fat and free fatty acids. *Surgery* 40: 665, 1956
 79. Derks CM, Jacobovitz-Derks D: Embolic pneumopathy induced by oleic acid. *Am J Pathol* 87: 143, 1977
 80. Harris RI, Perrett TS, MacLachlin A: Fat embolism. *Ann Surg* 110: 1095, 1939
 81. Parker FB, Wax SD, Kusajima K, Webb WR: Hemodynamic and pathologic findings in experimental fat embolism. *Arch Surg* 108: 70, 1974
 82. Szabó G, Magyar Z, Réffy A: The role of free fatty acids in pulmonary fat embolism. *Injury* 8: 278, 1977
 83. Pietra GG: The lung in shock. *Human Pathol* 5: 121, 1974