

Colour anomia restricted to the left visual hemifield after splenial disconnexion

J ZIHL AND D VON CRAMON

From the Max-Planck-Institute for Psychiatry, Munich

SUMMARY In a patient with damage to the right occipital lobe and to the splenium of the corpus callosum, an incomplete colour anomia in the left upper quadrants and a colour anomia was found for the complete left visual hemifield beyond 2° eccentricity. The patient had no difficulty in recognising coloured targets when presented in the periphery of the left visual half-field and in the foveal region, but could not name them correctly. The results suggest that the lesion of the splenium of the corpus callosum disconnects the right visual cortex from the language areas of the left hemisphere, and the specific disturbance of colour naming is the consequence.

Colour anomia may be a symptom of amnesic aphasia (anomia), a primary aphasic disorder arising from damage to the cortical structures directly subserving language function.¹ A second variety of colour anomia is very often accompanied by a right sided hemianopia and a dyslexia. The latter disturbance of colour naming has been attributed to an anatomical disconnexion between the visual cortex and the cerebral structures subserving language function. This kind of colour anomia is secondary to this disconnexion while language function remains intact.^{2,3} In these cited cases colour anomia was present in the remaining intact visual field. The loss of one or both upper quadrants is often accompanied by an inability to recognise colours.⁴ No disturbance of naming colours, however, was observed for a particular part of the visual field, for example, for one hemifield. Here we report a case with a lesion including the right occipito-temporal region and damage to the splenium of the corpus callosum. As a consequence colour perception was partially lost in the left upper quadrants and a disturbance of colour naming for the left hemifield beyond 2° eccentricity was found.

CASE HISTORY

A 41 year old Caucasian suffered from frequent acute sinusitis with secondary bronchial infections

Address for reprint requests: Dr J Zihl, Max-Planck-Institut für Psychiatrie Kraepelinstrasse 10 D-8000 München 40, W. Germany.

Accepted: 20 March 1980

since her childhood. Menorrhagia and metrorrhagia as well as many "bruises" were observed during the last four years. In June 1979 she suffered again from acute sinusitis. A few days later a left-sided hemiplegia with ptosis on the right side developed within hours, suggesting a right-sided Weber syndrome. The patient was admitted to another hospital and became drowsy and eventually comatose. She was said to have remained unconscious for about two weeks, but no detailed information about this period is available. The CT-scan showed haemorrhage in the medial temporo-occipital region of the right hemisphere penetrating into the inferior horn of the lateral ventricle and into the superior, ambient and interpeduncular cisterns. The right peduncle had been slightly compressed by a space-occupying blood clot.

Upon admission examination showed a pale patient with petechiae and generalised bruising. The spleen was slightly enlarged. The main laboratory findings were a hypochromatic anaemia, a thrombocytopenia ($<3000/\text{mm}^3$) with giant platelets, a prolonged bleeding time, a reduced maximal thrombus-elasticity, a pathological prothrombin-consumption-test and an increased number of megakaryocytes in the sternal marrow.

On the basis of these findings idiopathic thrombocytopenic purpura (chronic-continuous type) was diagnosed. The patient was given steroids in high dosage, and the number of thrombocytes increased to normal values.

The patient was transferred to our department in November 1979. By that time the neurological signs had receded except for a latent paresis of the left arm. The patient was now complaining of intermittent blurred vision.

The CT-scan was repeated in November 1979 (fig 1). There was an enlargement of the collateral trigone and the inferior horn of the right lateral ventricle (1A, B, C). The superior cistern was widened at least on its right side. A well marked low density zone was present mainly in the white matter of the medial temporo-occipital gyri of the right hemisphere. The lesion extended cranially into the precuneus (1D) and rostrally into the right half of the splenium of the corpus callosum (1C). Parts of the right hippocampal gyrus and the cingulate gyrus at its isthmus were probably also affected (1B,C).

The patient was right-handed, alert and orientated in person, place and time. She did not show any difficulty in verbal expression and comprehension or in naming objects. She had no alexia

or agraphia. Visual acuity was normal in both eyes.

Methods

Visual perimetry Visual fields were mapped with the Tübinger perimeter,^{5,6} using a target of 116 min arc diameter and maximum intensity (320 cd/m²) for 90° dynamic perimetry. In addition, static perimetry was performed to determine the profile of the gradient of light sensitivity along the horizontal axis and along the 45° axis (right upper quadrant) and the 135° axis (left upper quadrant) respectively. Visual fields were also mapped with coloured targets of 116 min arc diameter and maximum intensity (320 cd/m²). The spectra values of the coloured targets were 480 nm for "blue," 525 nm for "green" and 656 nm for "red". Colour fields were also determined using the Tübinger perimeter. The patient's task was to press a button whenever she could identify the coloured target.

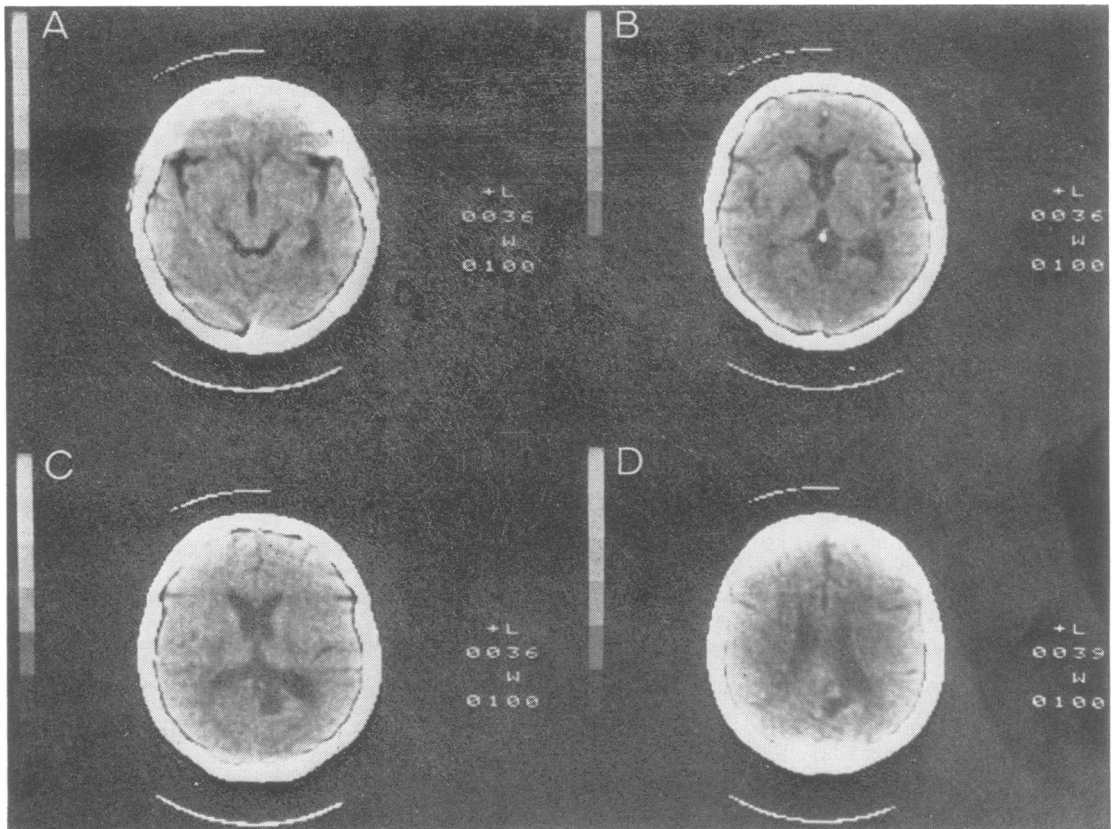


Fig 1 Results of CT scans obtained at four different levels. For details see text.

In addition critical flicker fusion (CFF) was determined by measuring CFF-fields for 15, 20 and 25 Hz (target: 116 min arc diameter; 32 cd/m²). The flickering target was moved with a velocity of about 1°/sec from the periphery towards the centre of the visual field. The patient was asked to push a button whenever she could detect the target flickering.

Colour perception and naming The tests on colour perception and naming within the visual field were performed with the Tübinger perimeter. Targets of different wavelength (blue: 480 nm; green: 525 nm; yellow: 578 nm; red: 656 nm) were presented at different eccentricities along the horizontal axis and along the 45° meridian in the right half-field, and the 135° and 225° meridians in the left half-field. Target size was always 116 min arc diameter, intensity was 320 cd/m²; stimulus duration was either 100 ms or unlimited. Fixation was controlled with an infra-red camera. The patient's task was to compare the colour of a given target presented beyond 2° eccentricity with the colour of several foveally presented targets, and to indicate, whether the colour was the same or different. For colour naming, targets were presented at a given position in the left or right visual hemifield, or foveally. The patient was instructed to name the colour of the target.

In addition to the colour tests with the perimeter, the Farnsworth-Munsell 100-hue test was used.⁷ Furthermore, a slide with 60 different coloured written colour names (for example, "blue" written in red letters) was presented and the patient was asked to name the colour of the words and—in a second session—to read the words.

Object naming in the visual field In order to test object recognition and the naming of objects, symbols (circle, triangle etc) and figures of objects (a house, an apple etc) were presented tachistoscopically (exposure duration: 100 ms) in the left and right visual hemifield. The patient's task was to identify the presented figures by naming them.

Reading in the left and right hemifield Letters and words of appropriate size (for visual acuity beyond 2° eccentricity) were presented tachistoscopically (exposure duration: 100 ms) in the left and right hemifield. The patient's task was to name the letters and to read the words.

Results

Perimetric data Fig 1A shows the binocular visual field for white light and the colour visual

fields for blue, green and red test targets. There was an incomplete colour anomia in the left upper quadrants indicating a partial loss of colour perception in this region of the visual field. Contrast sensitivity, however, was not diminished in the left hemifield, neither for the horizontal axis nor for the diagonal meridian (135° meridian as compared to the 45° meridian in the right hemifield; cf fig 1B). Furthermore, no restriction was found for the CFF-fields in the left as compared with the right hemifield.

Colour perception and colour naming The results for colour comparison in the left hemifield are shown in table 1. No deficit in colour comparison was found along the horizontal meridian and for the upper and lower quadrants except for a small decrease in correct responses for green at 20° eccentricity along the 225°-meridian (lower quadrant) and along the 135°-meridian (upper quadrant).

Table 1 *Colour comparison (fovea—left hemifield) Correct responses in percent (n=30) 100 ms stimulus duration*

Colour	Lower quadrant			Upper quadrant		
	10°	15°	20°	5°	10°	15°
Red	100	100	100	100	100	100
Blue	100	100	100	100	100	100
Green	100	100	86.7	100	100	93.3
Yellow	100	100	100	100	100	100

Colour naming was found to be correct for the fovea and for the right hemifield.

In contrast to these observations, colour naming was clearly affected in the left hemifield. In the upper quadrant, the test was performed only up to 10° eccentricity, because the border of the colour field for "red" was at 12° eccentricity. When coloured targets were presented along the horizontal meridian, a gradual decrease of correct responses was obtained. "Green" was first affected (at 3° eccentricity), followed by "red" and "yellow." At 20° eccentricity, the percentage of correct responses dropped markedly also for "red" and "yellow." "Blue" was in all cases of incorrect response the substituted colour name. Blue targets were always called "blue" (cf table 2). Similar results were obtained for different positions along the 135°-meridian and 225°-meridian (upper and lower quadrants) in the left hemifield. A comparable decrease in the percentage of correct responses was found; the order of the decrease was quite the same (green, red and yellow; tables 3 and 4). There was no clear difference between the two quadrants. Also in these tests, "blue" was always named correctly; the other coloured targets

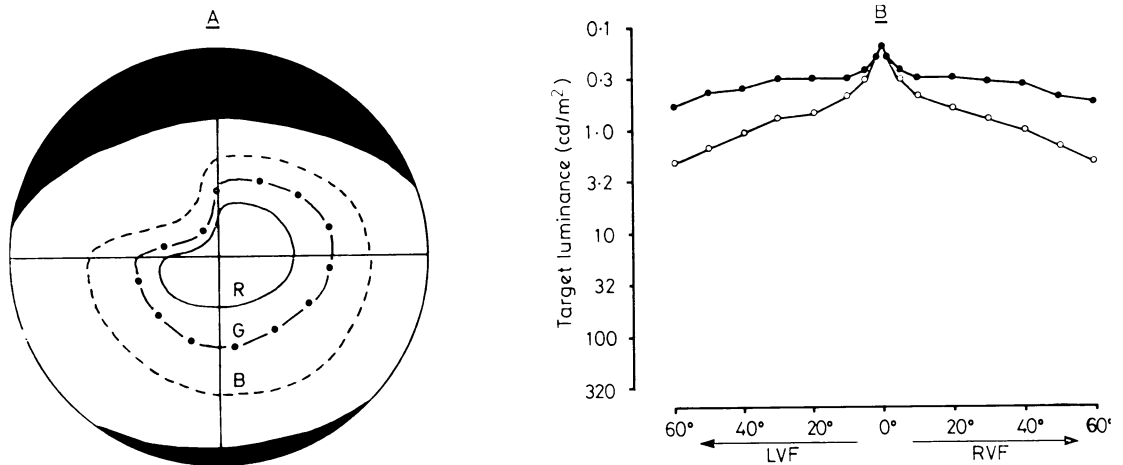


Fig 2 Binocular visual field (up to 60° eccentricity) for white light and coloured targets (A) and profile of light sensitivity along the horizontal axis and the diagonal meridians in the upper quadrants (B). The visual field for colours (A) is restricted in the left upper quadrant (R: red target, G: green target; B: blue target). No difference was found for light sensitivity between the left and right hemifield along the horizontal axis (filled circles) and the 45°-meridian (RVF) and 135°-meridian (LVF), respectively.

Table 2 Colour naming along the left horizontal meridian Correct responses in percent (n=30) A: 100 ms stimulus duration B: unlimited duration

Colour	Eccentricity						
		2	3	5	10	15	20
Red	A	100	100	100	73.3	56.7	10.0
	B	100	100	100	73.3	60.0	13.3
Blue	A	100	100	100	100	100	100
	B	100	100	100	100	100	100
Green	A	100	66.7	23.3	6.7	6.7	0.00
	B	100	73.3	33.3	10.0	6.7	0.00
Yellow	A	100	100	100	73.3	60.0	16.7
	B	100	100	100	70.0	63.3	20.0

Table 3 Colour naming in the left lower quadrant Correct responses in percent (n=30) A: 100 ms stimulus duration B: unlimited duration

Colour	Eccentricity					
		2	3	5	10	20
Red	A	100	90.0	40.0	23.3	0.00
	B	100	93.3	50.0	26.7	0.00
Blue	A	100	100	100	100	100
	B	100	100	100	100	100
Green	A	100	53.3	10.0	6.7	0.00
	B	100	60.0	10.0	13.3	0.00
Yellow	A	100	100	100	80.0	60.0
	B	100	100	100	76.7	73.3

(green, red and yellow) were mostly called as "blue," when they were named incorrectly. The patient was not aware of the consistent misnaming.

The performance on the Farnsworth-Munsell 100-hue test was diminished in all parts of the spectrum except for blue (fig 2). The patient had

Table 4 Colour naming in the left upper quadrant Correct responses in percent (n=30) A: 100 ms stimulus duration B: unlimited duration

Colour	Eccentricity				
		2	3	5	10
Red	A	100	90.0	40.0	23.3
	B	100	86.7	43.3	26.7
Blue	A	100	100	100	100
	B	100	100	100	100
Green	A	100	53.3	10.0	6.7
	B	100	60.0	10.0	13.3
Yellow	A	100	100	100	80.0
	B	100	100	100	76.7

no problems to assign the correct name to the colours in which words are written (for example, "blue" when the term "red" was written in blue letters), or to read the word for a colour written in another colour (for example, "green" when written in yellow or blue letters).

Object naming All presented figures (circle, triangle, square; house, apple, dog; faces) were identified and named correctly by the patient irrespective to whether they were presented in the left or right hemifield.

Letter and word recognition The patient had no difficulty in recognising letters and words presented in either half-field.

Discussion

The main findings described in this report are (1) a partial loss of colour vision in the left upper

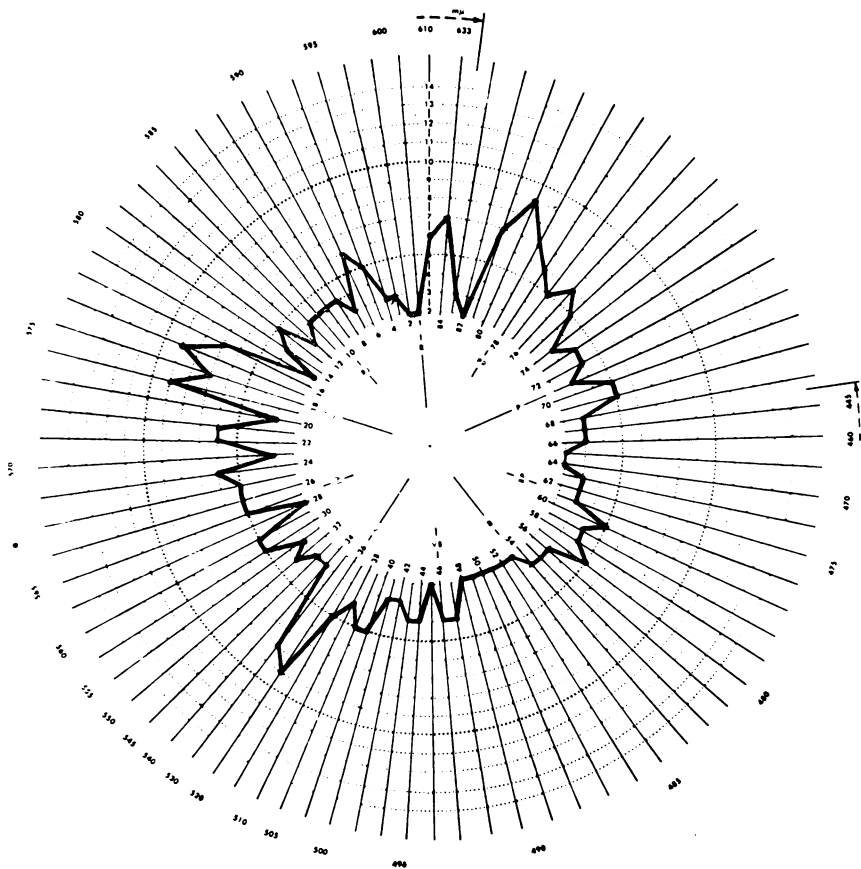


Fig 3 Farnsworth-Munsell 100-hue test (binocular condition). The extent of radial displacement indicates the degree of disturbed hue discrimination in that part of the spectrum. Note the good performance in the blue part of the spectrum.

quadrant and a reduced performance on the Farnsworth-Munsell 100-hue test except for the blue part of the spectrum, and (2) a colour anomia in the left hemifield beyond 2° eccentricity (where colour vision was preserved). This colour anomia was not accompanied by an alexia or agnosia for visual objects.

The partial loss of colour vision in the Farnsworth-Munsell test is in agreement with the findings in patients with unilateral brain damage reported by other authors, see for example references^{8,9}. The good performance for the blue part of the spectrum in the Farnsworth-Munsell test may be related to the observation that the colour visual field for blue in the upper left quadrant is reduced by a lesser extent than the colour fields for green and red targets. The extent of shrinkage

in the colour visual fields in the upper left quadrants may indicate a lesion involving the connexions from the striate cortex to prestriate cortical areas, and to the inferior occipitotemporal regions. Zeki^{10,11} has shown that cells in Area V4 of the prestriate cortex of the rhesus monkey are specifically colour-coded. Even though it is not possible to correlate the damaged region revealed by computed tomography in our patient, with the colour-coded areas found by Zeki, one might speculate about a functional connection of the lesioned area in our patient with Area V4 as defined by Zeki. It seems, however, that total loss of colour vision only occurs after bilateral lesions in the infero-temporal region in both man⁴ and monkey (Fries and Zeki, in preparation). In man, total loss of colour vision was found to be

accompanied by visual field defects, and there is a strikingly high incidence of bilateral defects affecting the upper quadrants (for a review, see reference 4). The observation that a partial visual field shrinkage in the upper left quadrants was only found for coloured targets suggests a dissociation of colour vision from other visual functions (for example, light sensitivity, critical flicker fusion) and supports the idea of a localised representation of colour vision in the visual cortex of man.

The colour anomia found in the left hemifield can be considered as a disturbance due to splenial damage.^{12,13} One may assume that the lesion of the splenium of the corpus callosum disconnects the areas involved in processing colours of the right visual cortex from the language areas of the left hemisphere. Colour anomia has not to be accompanied by an alexia, or an agnosia for visual objects, as our case indicates. This may be taken as evidence that a splenial disconnection syndrome can be restricted to only one visual function (see also reference 14).

It has been shown that the peristriate regions important for colour coding have their own callosal connections.^{11,15,16} If we suppose that fibres carrying colour information from the right prestriate cortex to the left hemisphere via the splenium of the corpus callosum are damaged, the isolated disturbance of naming colours in only the left hemifield would be the consequence of this splenial disconnection. Colour anomia, therefore, should be considered as a single unitary disturbance. It is not clear, however, why this anomia did not occur in the complete left hemifield, but only beyond 2° eccentricity. Probably either the foveal region is represented bilaterally^{17,18} or there is an overlap in the cortical representation of the visual field across the vertical axis.^{19,20} It remains also unclear why performance in colour naming is better along the left horizontal meridian as compared with the upper and lower quadrants, as density of colour-coded cells or colour carrying fibres in relation to visual field regions (for example, the horizontal meridian) has not been clarified.

In conclusion the results presented here support the notion of splenial disconnection of colour naming from colour perception. The observations were obtained by testing the two visual half-fields for different visual and visual-verbal tasks. Under normal (that is, foveal) test conditions the presented disconnection phenomenon would not have been observed.

This work was supported by Deutsche Forschungsgemeinschaft.

References

- 1 Kinsbourne M, Warrington EK. Observations on colour agnosia. *J Neurol Neurosurg Psychiatry* 1964; **27**:296-9.
- 2 Geschwind N, Fusillo M. Color naming defects in association with alexia. *Arch Neurol* 1966; **15**: 137-46.
- 3 Oxbury JM, Oxbury SM, Humphrey NK. Varieties of colour anomia. *Brain* 1969; **92**:847-60.
- 4 Meadows JC. Disturbed perception of colours associated with localized cerebral lesions. *Brain* 1974; **97**:615-32.
- 5 Sloan LL. The Tübinger perimeter of Aulhorn and Harms. *Arch Ophthalmol* 1971; **86**:612-22.
- 6 Aulhorn E, Harms H. Visual perimetry. In: Jameson D, Hurvich LM, eds *Handbook of Sensory Physiology* VII/4. Berlin: Springer Verlag 1972; 102-45.
- 7 Farnsworth D. The Farnsworth-Munsell 100-hue and dichotomous tests for colour vision. *J Opt Soc Am* 1943; **33**:568-78.
- 8 Scotti G, Spinnler H. Colour imperception in unilateral hemisphere-damaged patients. *J Neurol Neurosurg Psychiatry* 1970; **33**:22-8.
- 9 Capitani E, Scotti G, Spinnler H. Colour imperception in patients with focal excisions of the cerebral hemispheres. *Neuropsychologia* 1978; **16**: 491-6.
- 10 Zeki SM. Colour coding in rhesus monkey prestriate cortex. *Brain Res* 1973; **53**:422-7.
- 11 Zeki SM. Colour coding in the superior temporal sulcus of rhesus monkey visual cortex. *Proc R Soc Lond, B* 1977; **197**:195-223.
- 12 Geschwind N. Disconnection syndromes in animals and man. Part I *Brain* 1965a; **88**:237-94.
- 13 Geschwind N. Disconnection syndromes in animals and man. Part II *Brain* 1965b; **88**:585-644.
- 14 Vincent FM, Sadowsky CH, Saunders RL, Greeves AG. Alexia without agraphia, hemianopia, or color-naming defect: A disconnection syndrome. *Neurology* 1977; **27**:689-91.
- 15 Zeki SM. Interhemispheric connections of prestriate cortex in monkey. *Brain Res* 1970; **19**:63-75.
- 16 Rockland KS, Pandya DN. Laminar origins and terminations of cortical connections of the occipital lobe in the rhesus monkey. *Brain Res* 1979; **179**:3-20.
- 17 Bunt AH, Minckler DS, Johanson GW. Demonstration of bilateral projection of the central retina of the monkey with horseradish peroxidase neuronography. *J Comp Neurol* 1977; **171**:619-30.
- 18 Huber A. Homonymous hemianopia after occipital lobectomy. *A J Ophthalmol* 1962; **54**:623-9.
- 19 Cragg BG. The topography of the afferent projections in circumstriate visual cortex of the monkey studied by the Nauta method. *Vision Res* 1969; **9**:733-47.
- 20 Zeki SM. Representation of central visual fields in prestriate cortex of monkey. *Brain Res* 1969; **14**:271-91.