

# Giant arteriovenous fistula of the vein of Galen in early infancy treated successfully with surgery

## Case report

JOSE ANDRES ALVAREZ-GARIJO, M.D., MANUEL VILA MENGUAL, M.D.,  
DARIO TABOADA GOMILA, M.D., AND ADELA ALONSO MARTIN, M.D.

*Pediatric Neurosurgery and Pediatric Neuroradiology Units, Clinica Infantil de la Seguridad Social "La Fe," Valencia, Spain*

✓ A giant arteriovenous fistula in a newborn infant was treated by surgical occlusion of the feeding vessels at 20 days of life. Congestive heart failure responded favorably to operative treatment. Because of persistent hydrocephalus, a shunt was inserted at 2 months of age. At 9 months of age, the child remained without signs of cardiac failure. Cerebral damage was manifested by a mild left hemiparesis. Successful surgical treatment of this unusual lesion in a neonate is exceptional.

**KEY WORDS** • vein of Galen • arteriovenous malformation • congestive heart failure • hydrocephalus • intraventricular hemorrhage • neonatal surgical treatment

**S**YMPOMATIC arteriovenous malformations (AVM's) of the vein of Galen have been reported in early infancy, associated with progressive and generally fatal cardiac failure. Successful surgical treatment of this lesion is unusual. We present a case of giant arteriovenous fistula in a newborn that was successfully treated by surgical occlusion of the feeding vessels at 20 days of age.

### Case Report

This baby boy was seen at 3 days of age. He showed signs of cardiac failure with tachypnea and hepatomegaly.

*Examination.* Heart auscultation revealed systolic murmur at the intercostal spaces of the left third and fourth ribs. Chest x-ray films revealed marked cardiomegaly (Fig. 1), and an electrocardiogram showed right atrial and ventricular hypertrophy. His neurological status was nearly normal. The head circumference was below the 90th percentile.

The symptoms progressed with engorgement of the neck veins, cyanosis, and a continuous cranial bruit. The clinical condition did not improve after administration of digitalis. Cerebral angiography per-

formed at 20 days showed a giant fistula of the vein of Galen, 5 cm in diameter. Filling was predominantly from an enlarged vertebrobasilar system, through the right cerebral posterior artery and, to a lesser degree, by the right pericallosal and callosomarginal arteries

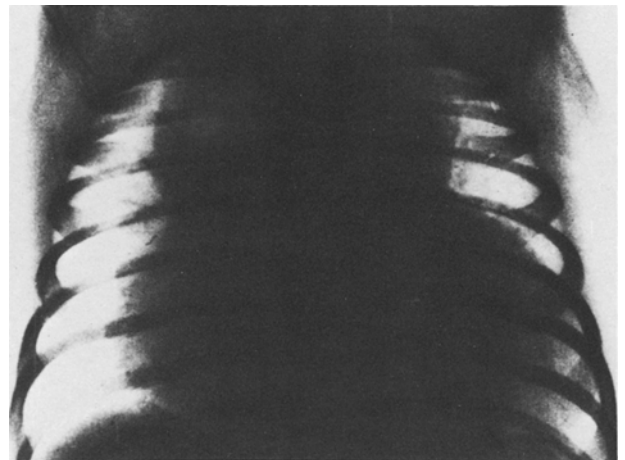


FIG. 1. Preoperative chest x-ray film showing marked cardiomegaly.

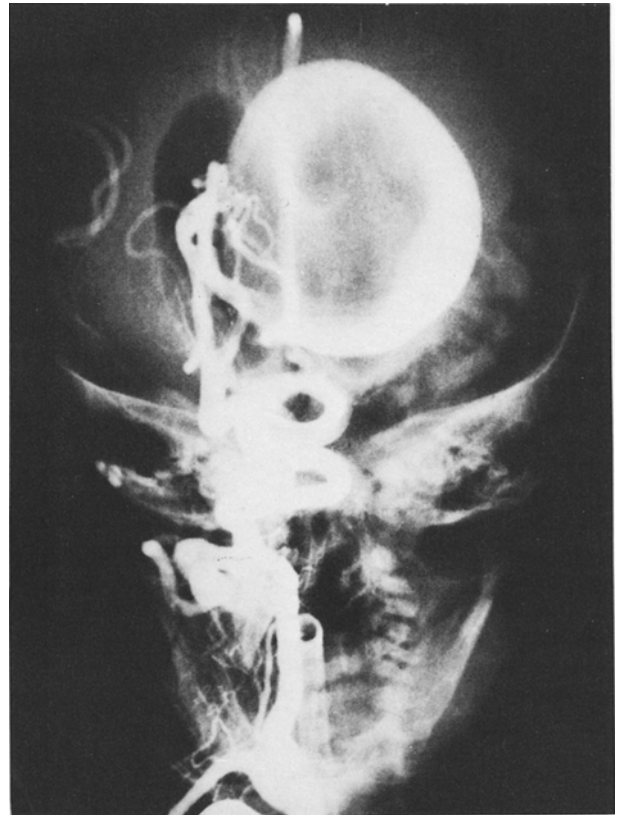



FIG. 2. Preoperative right brachial cerebral angiography. *Left:* Lateral view, arterial phase, showing a large sac occupying the region of the vein of Galen. *Right:* Anteroposterior view showing the arterial supply from the right posterior cerebral artery and a marked enlargement of the vertebrobasilar system.

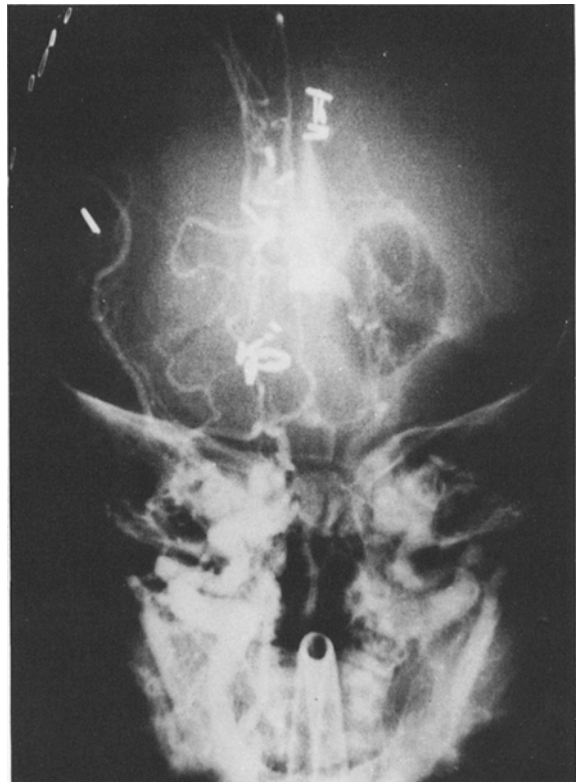
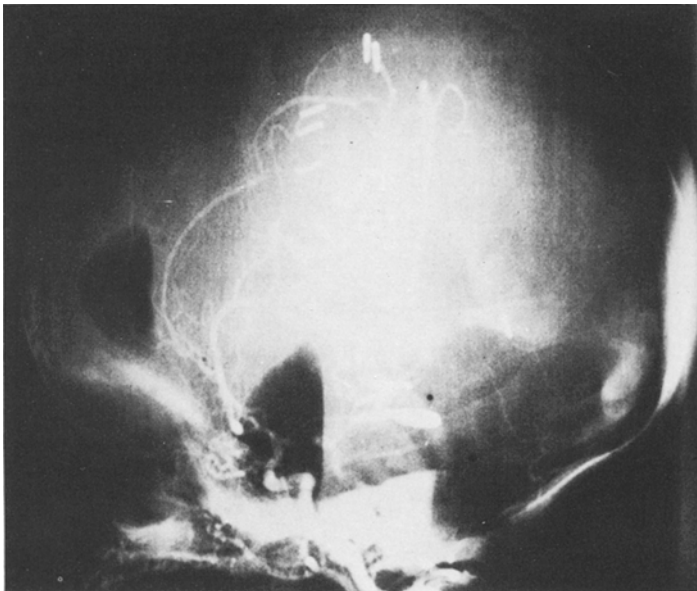


FIG. 3. Postoperative brachial cerebral angiography. *Left:* Lateral view showing obliteration of the largest feeding vessel. *Right:* Anteroposterior view demonstrating the normal appearance of the deep venous system with early filling.

## Giant AVM of vein of Galen

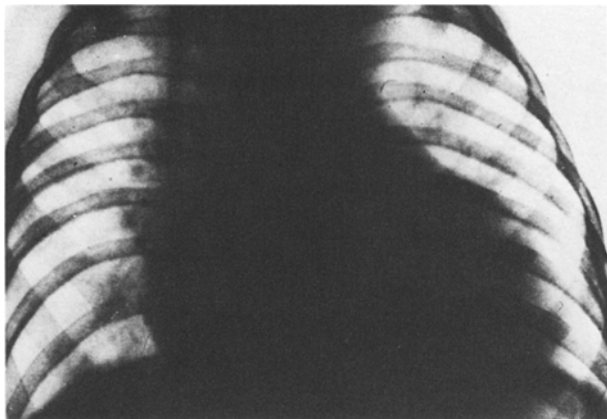


FIG. 4. Postoperative chest x-ray film showing reduction of cardiomegaly.

(Fig. 2). Air ventriculography showed hydrocephalus with aqueductal obstruction.

**Operation.** The patient experienced severe, nearly irreversible, cardiac failure, and underwent immediate surgery. A large right parietotemporal craniectomy was performed, crossing the midsagittal line. The main feeding vessel was approached subtemporally and was clipped under the surgical microscope. The other feeding vessels were occluded with conventional silver clips, the anterior cerebral artery group being approached along the interhemispheric fissure. The operative procedure was carried out under general anesthesia using a volumetric respirator.

The procedures usual in high-risk pediatric neurosurgery were performed, including monitoring the central venous pressure, systemic arterial pressure, heart rate, temperature, blood electrolytes, blood gases, and actual blood and fluid loss, and electrocardiography.

Precautions against acute cardiac failure caused by the sudden increase of peripheral resistance following arteriovenous fistula obliteration included reduction of blood volume during the exposure without replacement of monitored loss. Thus, at the moment the main feeding vessel was occluded, the mean systemic arterial pressure was 75% of initial pressure, with a systolic systemic arterial pressure below 50 mm Hg.

**Postoperative Course.** The patient's cardiac condition improved after operation, but his postoperative course was complicated. Focal seizures started during the first few hours, requiring treatment with phenobarbital and intravenous diazepam until the 15th day. Intraventricular hemorrhage was treated by external ventriculostomy, with a Rickham reservoir maintained for 7 days.

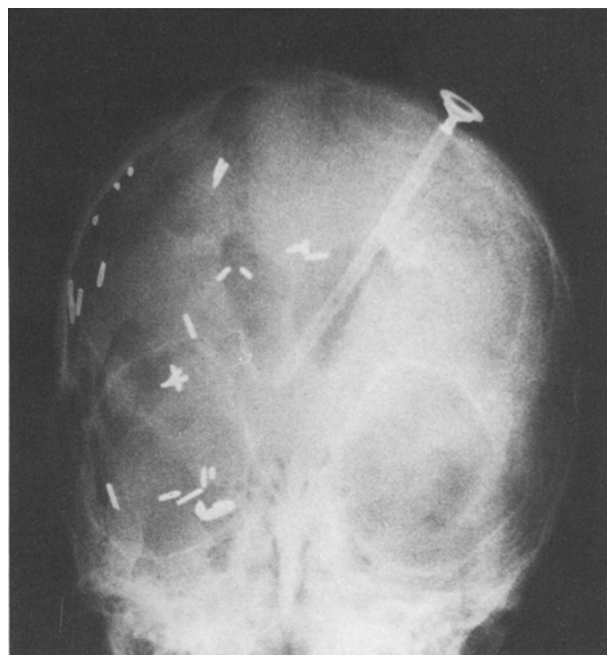

FIG. 5. Ventriculography with air introduced through the ventriculostomy reservoir at 9 months of age showing a slightly dilated ventricular system.

Postoperative angiography showed lack of filling of the malformation (Fig. 3). The patient's general, cardiac, and neurological status improved, and he was discharged 30 days after operation, although there was a mild atrial and ventricular dilation (Fig. 4).

Two months later, air ventriculography showed persistent hydrocephalus, and a low-pressure ventriculoperitoneal shunt was inserted. At 7 months, the child showed signs and symptoms of shunt malfunction. Ventriculography demonstrated dilation, and he underwent shunt revision. At 9 months of age, the patient showed electroencephalographic evidence of mild left hemiparesis and focal alterations in the right parieto-occipital region. Control air ventriculography through the ventriculostomy reservoir demonstrated a slightly dilated ventricular system. No signs of heart failure were found (Fig. 5). The patient is receiving anticonvulsant treatment.

### Discussion

Giant AVM's of the vein of Galen carry a high mortality rate.<sup>1,4,6</sup> In 1976, Watson, *et al.*,<sup>9</sup> reviewed 40 such cases with symptomatology starting before 3 months of age; 14 of their patients were treated surgically, and four survived. In only one of these was operation in early infancy explicitly mentioned.<sup>9</sup> Ventureyra, *et al.*,<sup>8</sup> reported no survivors among four neonates operated on in their series.

Our case must be included in the "varix" group of the widely accepted McCormick classification,<sup>7</sup> consisting of patients without associated angioma and with low resistance to blood flow and rapid cardiac failure. Although the arteriovenous fistula remains compensated by placental low pressures *in utero*, marked hemodynamic failure occurs at birth, when the neonatal shunt becomes independent of the mother's pulmonary circulation.<sup>3</sup> Two decisive factors determine the degree of cardiac failure: 1) total diameter of the fistulous connections, and 2) outflow diameter. Both factors are modified by whether or not interposed angiomas are present.<sup>2</sup>

Brain damage may be induced by four mechanisms: 1) cerebral blood flow steal, 2) cerebral ischemia, 3) hemorrhagic infarct, and 4) mass effect of the malformation.<sup>5</sup> The last factor has little importance because of the expansile nature of the infantile cranial vault. Early surgical treatment appears to be the only effective procedure to treat cardiac failure and prevent cerebral damage, especially since in the neonatal period the surgical approach is relatively easy, particularly in hydrocephalic patients.

#### References

1. Amacher AL, Shillito J Jr: The syndromes and surgical treatment of aneurysms of the great vein of Galen. **J Neurosurg** 39:89-98, 1973
2. Bartal AD: Classification of aneurysms of the great vein of Galen. **J Neurosurg** 42:617-618, 1975 (Letter)
3. Cronqvist S, Granholm L, Lundström N-R: Hydrocephalus and congestive heart failure caused by intracranial arteriovenous malformations in infants. **J Neurosurg** 36:249-254, 1972
4. French LA, Chou SN: Conventional methods of treating intracranial arteriovenous malformations. **Prog Neurol Surg** 3:274-319, 1969
5. Gomez MR, Whitten CF, Nolke A: Aneurysmal malformation of the great vein of Galen causing heart failure in early infancy. Report of five cases. **Pediatrics** 31:400-411, 1963
6. Long DM, Seljeskog EL, Chou SN, et al: Giant arteriovenous malformations of infancy and childhood. **J Neurosurg** 40:304-312, 1974
7. McCormick WF: The pathology of vascular ("arteriovenous") malformations. **J Neurosurg** 24:807-816, 1966
8. Ventureyra ECG, Ivan LP, Nabavi N: Deep seated giant arteriovenous malformations in infancy. **Surg Neurol** 10:365-370, 1978
9. Watson DG, Smith RR, Brann AW Jr: Arteriovenous malformation of the vein of Galen. Treatment in a neonate. **Am J Dis Child** 130:520-525, 1976

---

*Address reprint requests to:* Jose A. Alvarez-Garijo, M.D., Neurocirugia Infantil, Instituto Nacional de Prevision, Ciudad Sanitaria de la S. S. "La Fe," Valencia-9, Spain.