

Paraprotein-induced hyperviscosity

Michael D. Pavy, Patrick L. Murphy & Gabriel Virella

To cite this article: Michael D. Pavy, Patrick L. Murphy & Gabriel Virella (1980)
 Paraprotein-induced hyperviscosity, *Postgraduate Medicine*, 68:3, 109-112, DOI:
[10.1080/00325481.1980.11715533](https://doi.org/10.1080/00325481.1980.11715533)

To link to this article: <http://dx.doi.org/10.1080/00325481.1980.11715533>



Published online: 07 Jul 2016.



Submit your article to this journal [↗](#)



View related articles [↗](#)




Citing articles: 7 View citing articles [↗](#)

Paraprotein-induced hyperviscosity

A reversible cause of stroke

Michael D. Pavy, MD, Patrick L. Murphy, MD, Gabriel Virella, MD, PhD



CASE REPORT

POSTGRADUATE MEDICINE invites submission of brief case reports, especially those related to ambulatory medical care. Illustrations and references should be included only when essential.

A 60-year-old man was admitted for evaluation of right hemiparesis. For several weeks he had experienced general malaise and weakness; these symptoms had progressed to the point where he had become bedridden just before admission.

On admission the patient was stuporous. Blood pressure was 120/65 mm Hg, temperature 39 C (102 F), and pulse rate 120 beats/min.

Physical examination was unremarkable except for right hemiparesis and right central palsy of the seventh cranial nerve. Results of laboratory studies showed a hemoglobin

level of 7.4 gm/dl; WBC count of 20,000/cu mm, with 54% polymorphonuclear leukocytes, 25% lymphocytes, 14% plasmablasts (figure 1), and 6% bands; and serum calcium level of 11.6 mg/dl.

Cellulose acetate serum electrophoresis disclosed a gamma globulin level of 8.75 gm/dl. Immunoelectrophoretic studies showed the monoclonal spike present in the serum to be IgG₂-κ. This paraprotein had the characteristics of a pyroglobulin (ie, polymerization at 56 C [132.8 F]). Levels of other major immunoglobulins were depressed, with an IgA

continued

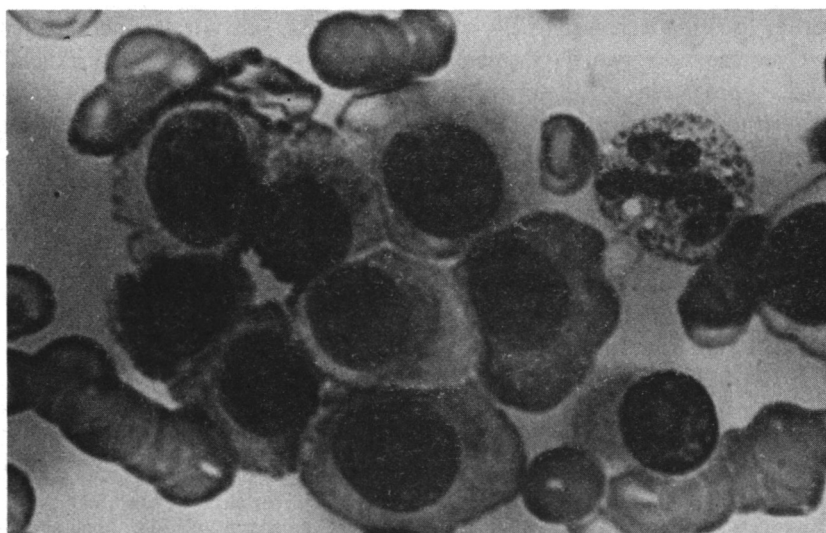


Figure 1. Peripheral smear showing plasmablast and rouleau formations typical of the hyperviscosity syndrome. (Wright-Giemsa $\times 1,000$)

level of 15 mg/dl and an IgM level of 50 mg/dl. Serum viscosity was 4.3 relative to water (normal 1.2 to 1.4), determined using the Hess-Martinet capillary viscometer.

A chest x-ray film showed pneumonia in the left upper lobe. Sputum cultures grew *Klebsiella pneumoniae* and *Proteus mirabilis*. Computed tomographic scanning of the head showed mild atrophy of the cerebral cortex without focal abnormalities.

Treatment with methylprednisolone and gentamicin was started. On the second hospital day the patient was still stuporous. Six units of whole blood were drawn and replaced with packed red cells and normal plasma. The patient became somewhat more alert, the right hemiparesis partially resolved, and serum viscosity decreased to 2.4.

Over the next two days, mental status progressively deteriorated, and serum viscosity rose to 2.9. The patient underwent direct plasmapheresis via a centrifugal blood separation device (Aminco Cell Separator) for four hours. This resulted in complete resolution of hemiparesis, return of mental status to normal, a fall in serum viscosity to 1.7, and a decrease in gamma globulin to 3.75 gm/dl.

Over the next several days the patient showed progressive deterioration in mental status, recurrence of right hemiparesis, and a rise in serum viscosity to 3.0. *Proteus* pneu-

monia developed in the right lower lobe and he died.

Autopsy disclosed plasma cell leukemia involving the bone marrow, lungs, spleen, pancreas, and kidneys. Examination of the brain showed encephalomalacia with multiple small lacunar infarcts.

Discussion

Whole blood viscosity is dependent upon the concentration of and interaction between serum proteins and the formed elements of the blood. This interaction is most significant at the microvascular level, where flow rates of blood are low and intermittent. This fact makes in vitro viscosity measurements difficult to correlate with clinical symptoms.¹ The level of serum viscosity at which symptoms are seen varies with the individual, but within each patient there is a "symptomatic threshold" above which a major end-organ system will consistently demonstrate clinical abnormalities.² The case reported here followed this general

rule, and the patient manifested neurologic deterioration at a serum viscosity of 2.9.

The neurologic manifestations of the hyperviscosity syndrome vary from headache to coma³ but are generally not focal in character. Headache, dizziness, and true vertigo typically occur, and occasionally generalized seizures are present.⁴ The hemiparesis in the case described was likely due to paraprotein-induced blood-flow sludging, since it correlated clinically with changes in serum viscosity. In a previous report,³ patients with neurologic presentations of hyperviscosity frequently had other characteristics of this syndrome, such as bleeding diathesis, funduscopic changes, and expanded plasma volume.⁴ The case of our patient is unique in that other clinical findings of hyperviscosity were lacking and thus plasmapheresis was delayed.

The common concept that hyperviscosity is seen predominantly in association with IgM gammopathies needs to be revised, since the occurrence of hyperviscosity in association with IgG⁵ or IgA⁶ gammopathies is far from infrequent. In the period from 1975 to 1979, we at the Medical University of South Carolina saw 13 patients showing dysproteinemia with serum viscosities in excess of 3.0 (relative to distilled water). Of these 13, seven had IgG monoclonal gammopathy, three IgA gammopathy, two polyclonal hyper-

continued

Michael D. Pavy
Patrick L. Murphy
Gabriel Virella

Dr Pavy was formerly clinical instructor, Medical University of South Carolina College of Medicine, Charleston, and is now clinical assistant, department of oncology, the Johns Hopkins Oncology Center, Baltimore. Dr Murphy is a medical resident, department of medicine, and Dr Virella an associate professor, department of basic and clinical immunology and microbiology, Medical University of South Carolina College of Medicine.

gammaglobulinemia, and one IgM monoclonal gammopathy. The highest viscosity recorded (5.0) was in a patient with IgA gammopathy. Moreover, in six patients with symptomatic hyperviscosity who we studied in detail, gammopathies were equally distributed among the three major immunoglobulin classes (two classified as IgG, two as IgA, and two as IgM).

Another misconception raised in early reports was that of the predominance of IgG₁ and IgG₂ paraproteins in those cases of hyperviscosity associated with IgG multiple myeloma.^{6,7} Actually, in a series of 22 cases of hyperviscosity associated with IgG gammopathy studied by one of us (G. V.),⁸ the distribution among subclasses was similar to that usually found on a random basis; in the present case the paraprotein was of the IgG₂ subclass, and the hyperviscosity was probably due to a combination of factors, such as extremely high serum concentration and abnormal configuration (as suggested by the tendency toward polymerization at 56 C).

Conclusion

Although the occurrence of the hyperviscosity syndrome with IgG plasma cell leukemia is unusual, it should be considered in the evaluation of patients with focal neurologic deficit with or without a known malignant paraproteinemia. If serum

viscosity is elevated, then emergent plasmapheresis should be considered, as it may reverse the neurologic deficit.

Address reprint requests to Michael D. Pavy, MD, Department of Oncology, The Johns Hopkins Oncology Center, 601 N Broadway, Baltimore, MD 21205.

References

1. McGrath MA, Penny R. Paraproteinemia: blood hyperviscosity and clinical manifestations. *J Clin Invest* 1976;58:1155-62
2. Fahey JL, Barth WF, Solomon A. Serum hyperviscosity syndrome. *JAMA* 1965; 192:464-7
3. Azzena D, Costa U, Chingliotti G, et al. Se-

rum hyperviscosity in multiple myeloma and its clinical and neuropsychiatric implications. *Confin Neurol* 1968;30:65-76

4. Bloch KJ, Maki DG. Hyperviscosity syndromes associated with immunoglobulin abnormalities. *Semin Hematol* 1973;10:113-24

5. Pruzanski W, Watt JG. Serum viscosity and hyperviscosity syndrome in IgG multiple myeloma: report on 10 patients and a review of the literature. *Ann Intern Med* 1972; 77:853-60

6. Virella G, Fudenberg HH. Polymerized IgA and serum hyperviscosity syndrome in human and animal multiple myeloma. *La Ricerca Clin Lab* 1976;6(Suppl 3):125

7. Capra JD, Kunkel HG. Aggregation of gamma-G3 proteins: relevance to the hyperviscosity syndrome. *J Clin Invest* 1970; 49:610-21

8. Virella G. Heavy chain subclasses of human immunoglobulin G. (Doctoral thesis.) Lisbon: Gulbenkian Foundation, 1973

Dr Tom Swifties . . .

"Too bad you don't have any flowers in your hospital room," said Dr Tom, lackadaisically.

*Alan E. Lindsay, MD
Salt Lake City*

"You will have to stop eating processed cheese," said Dr Tom kraftily.

I. Jack Markens, MD, Toronto

"This bite could lead to rabies," said Dr Tom, doggedly.

*Donald K. Haynes, MD
Homer, LA*

Look for other medical Swifties throughout this and future issues. Why not send in your own?

Address: Editorial Department, POSTGRADUATE MEDICINE, 4530 W 77th St, Minneapolis, MN 55435