

Cerebrovascular Diseases in the First Three Years of Life

Werner Isler, MD

Congenital and acquired cerebrovascular diseases in the very young age group are reviewed and discussed. Whilst saccular aneurysms are rare arteriovenous malformations and cavernous hemangiomas represent the most frequent types of all congenital anomalies. The aneurysm of the great vein of Galen manifests in the newborn period and mostly is mistaken for congenital heart disease. If the infant survives this angioma causes hydrocephalus.

A particular type of phakomatosis combines intracerebral pure venous malformation with homolateral port-wine nevus on the front, often causing epileptic seizures.

Spontaneous intracerebral hemorrhage occurs in children with small cavernous hemangiomas.

Acquired arterial lesions may develop during fetal life by embolism, causing porencephaly or unilateral brain atrophy.

The "Moyamoya" syndrome represents a frequent multi-arterial lesion causing characteristic ischemic episodes. Etiology is still obscure. We do not even know if the disease is acquired or congenital.

Isler W: Cerebrovascular diseases in the first three years of life. Brain Dev 1980;2:95-105

Pediatricians working in private practice hardly ever see cerebrovascular accidents in young children except for head injuries. In large pediatric units, however, admissions of children with such diseases are by no means infrequent. Cerebrovascular diseases in children may be divided into two categories: congenital anomalies and acquired lesions.

To begin with: *saccular aneurysms* are congenital malformations that are rare in infants and toddlers. Thirty-five cases have been published to date [1, 2]. As a rule, the onset of the disease is dramatic and without warning as a result of massive bleeding into the subarachnoid

space often associated with intracerebral hemorrhage. Saccular aneurysms are situated at the branching sites of the circle of Willis, most frequently at other arteries including the verte-bro-basilar system, rarely in distal segments of the cerebrovascular system. Many authors emphasize the importance of early surgery even in infants. Out of 35 patients with saccular aneurysms 13 underwent surgery whereby the aneurysm was either clipped or excised. The youngest child in this group was 5 months only. Ten patients recovered completely. In the second group there were 22 patients, none of which underwent surgery. Twenty of them died either of the sequelae of the first hemorrhage or of a recurrent one.

I followed up one patient, a girl, who was delivered by forceps. She spent the first few hours of life in an incubator, but showed no further perinatal problems. Her development proved satisfactory to the age of 6 months. At this stage she suddenly presented vomiting, then loss of consciousness for a few hours. This was followed by complete recovery. Two weeks

From the Department of Neurology, Children's Hospital, University of Zürich, Zürich.

Received for publication: January 18, 1980.

Key words: Cerebrovascular diseases, malformations, prenatally and postnatally acquired arterial lesions.

Correspondence address: Dr. Werner Isler, Department of Neurology, Children's Hospital, University of Zürich, Steinwiesstrasse 75, 8032 Zürich, Switzerland.

later she had a second attack, this time resulting in complete hemiplegia. Since blood could be traced in cerebrospinal fluid, angiography was performed. It demonstrated a fairly large saccular aneurysm situated at a distal branch of the middle cerebral artery. On CT-scan a large intracerebral hemorrhage was found. To our surprise the infant showed partial recovery over the next weeks. There was mild residual hemiparesis and up to this day mental development is normal. For the latter reason her parents so far refused to have her operated on in spite to our recommendation.

This case deserves further consideration in terms of etiologic factors responsible for saccular aneurysms. Apart from congenital malformations saccular aneurysms may be of infectious origin, these are the so-called *mycotic aneurysms*. They result in patients who suffer from e.g. subacute bacterial endocarditis. In very young children they practically never occur in the area supplied by intracranial arteries. We observed a mycotic aneurysm in one patient where it was situated at the extracranial portion of the internal carotid artery. This girl, at the age of 2, suffered from purulent adenopathy the site of which was close to the internal carotid artery. On angiography carried out 1 year later, an aneurysm showed up at precisely the same site [3].

The *traumatic dissecting aneurysm* is another type of acquired arterial lesion. I have published such a case in my monograph on "Acute hemiplegias and hemisyndromes in childhood" [3].

How do congenital malformations differ from acquired ones? Above all in topographic order. Saccular aneurysms are normally situated at the branching sites of the circle of Willis whilst aneurysms secondary to infection or trauma are normally situated elsewhere. In the case I just presented both delivery by forceps and distal site of the disease are suggestive of traumatic rather than congenital origin.

Angiomatous malformations are more frequent in young children than saccular aneurysms. As you know, their classification is based on anatomic-pathological and radiological criteria.

Arteriovenous malformations are tangles of vessels, often enlarged and tortuous, that feed and drain blood, the capillary bed is missing. Angiomas never produce compression of brain tissue except when hemorrhage incurs. Intra-

cranial pressure is seldom increased.

The *aneurysm of the great vein of Galen* makes an exception to this rule. This is a rare but typical malformation of the very young infant. Clinically two different types exist: one with excessive, the other with moderate shunt volume. The first type occurs early on during the newborn period presenting cardiac failure due to abundant shunt volume (Fig 1a, b). Invariably these symptoms are mistaken for congenital heart disease. A loud pulse-synchronous cranial bruit is pathognomonic; however, it may be absent. In one of four observations we made, diagnosis was established by angiography on the second day whilst the cranial bruit did not appear before the 6th day.

Infants with early congestive heart failure due to aneurysm of the great vein of Galen die within the first few days or weeks of life. Surgery was not successful in any of the published cases. This agrees with one of our observations.

In the second type of AV-malformation of the great vein of Galen prognosis is much more favorable. A much lower shunt volume produces moderate congestive heart failure only which responds to digitalis therapy. Clinical manifestation of hydrocephalus is always present. It is due to pressure of the aneurysm on surrounding structures resulting in aqueductal stenosis. Aneurysms of the great vein of Galen never rupture because of their wall being thick and solid. Extirpation should be considered after shunting procedure has been achieved.

The *classical form of AV-malformation* shows a preference for the hemisphere and in most cases causes subarachnoid hemorrhage associated with intracerebral bleeding. This form rarely evolved during the first 3 years of life. A dozen cases only have been published [4, 5].

The one case we were able to observe was a girl, 16 months old, with marked hydrocephalus. On angiography a large AV-malformation situated in the posterior cranial fossa showed up; surgical intervention was successful.

The association of recurrent intracranial hemorrhage with epileptic seizures is suggestive of AV-malformation.

To round off this review of different forms AV-angiomas I should like to demonstrate the angiogram of a boy, 18 months old, who suffered from AV-malformation of the external carotid artery that drained into the posterior cranial fossa. The AV-malformation was suc-

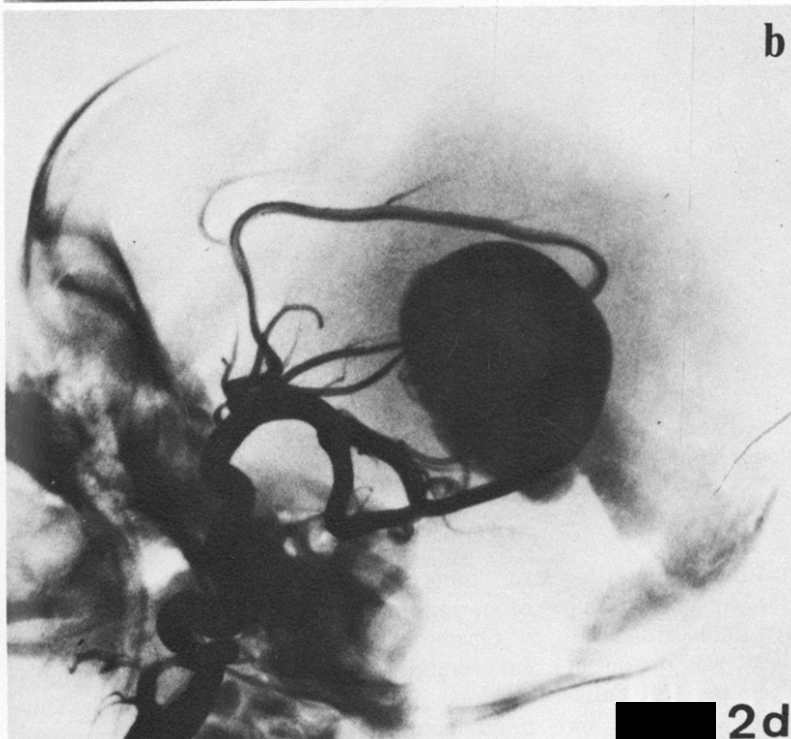
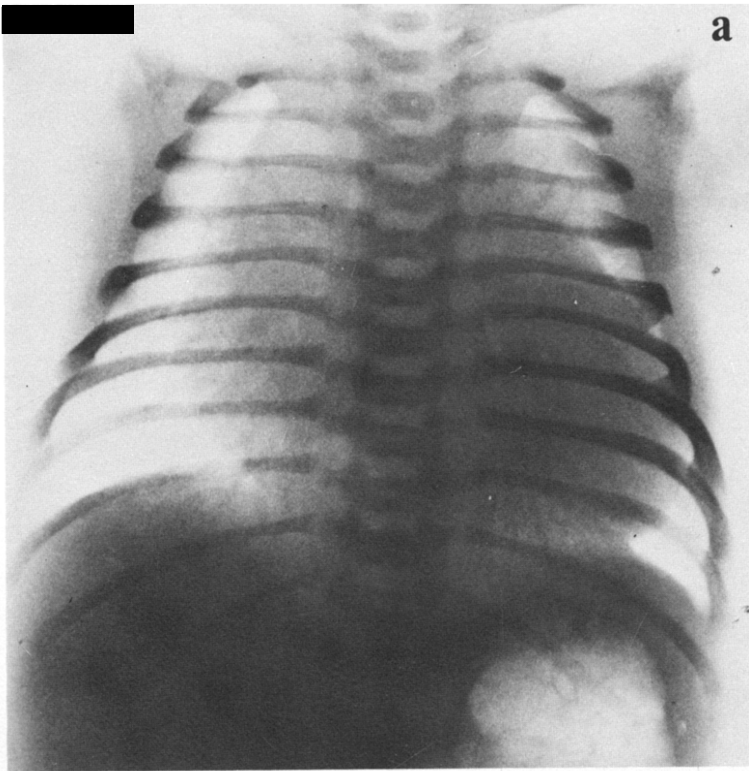


Fig 1 Congestive cardiac failure (a) in a 2-day-old newborn due to an aneurysm of the great vein of Galen (b).

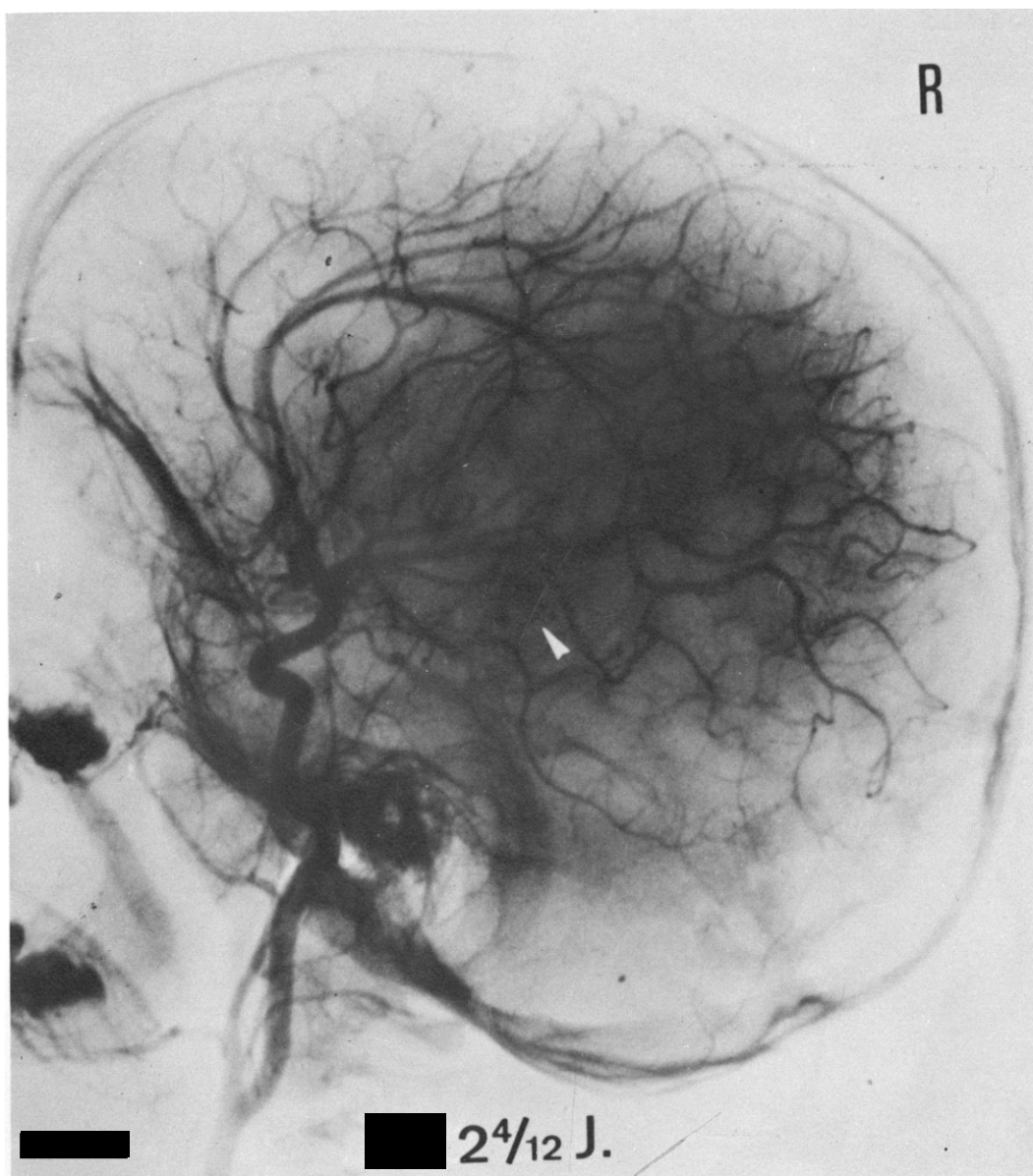


Fig 2 Small cavernous hemangiomas (arrow) in the right temporal lobe. 2-years-and-4-months-old girl.

cessfully cut off the circulation by inserting muscular tissue into both feeding and draining vessels. This patient showed mild cardiac failure, a pulse-synchronous bruit was present at one side of his neck. Off course, soft pulse-synchronous bruits can often be heard on cranial auscultation in healthy children. However, a cranial bruit in children under 1 year invariably indicates a vascular anomaly except

for congenital heart disease where murmurs often transmit to neck and head.

Cavernous hemangiomas are the most frequent cerebrovascular malformations in young children. They show a predilection for the temporal lobe. Massive intracerebral hemorrhage usually marks the onset of the disease. Moderate recurrent hemorrhages associated with epileptic seizures are less frequent. On angiogra-

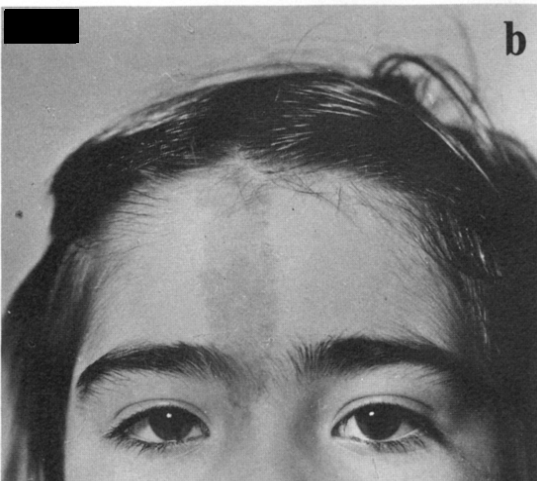
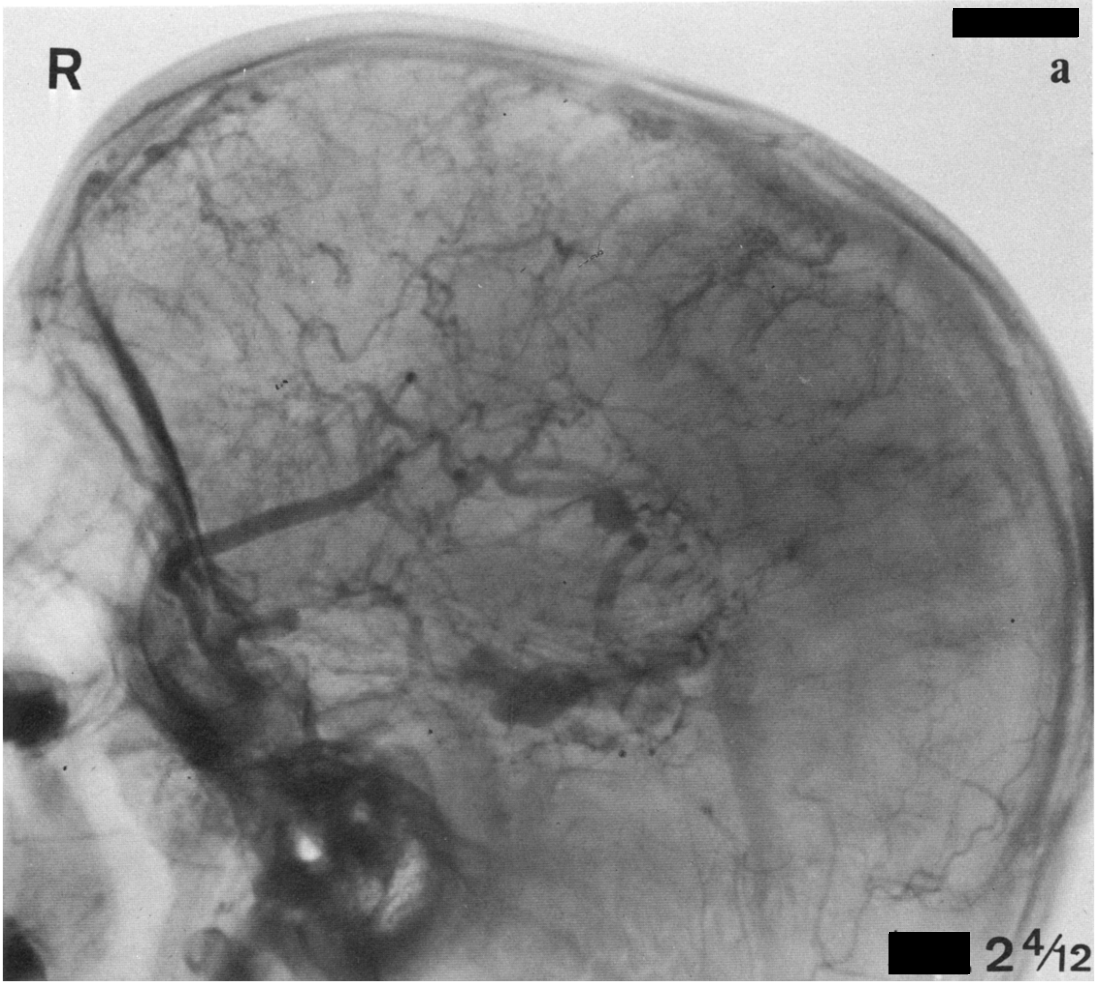

Fig 3 Venous angioma in the right cerebral hemisphere (a) with homolateral vascular skin nevus (b). 2-years-and-4-months-old girl.

phy cavernous hemangiomas may easily be overlooked because of their small size. On serial angiography a very small angioma may show up but once. One of our patients, a 14-month-old girl, suffered from recurrent moderate subarachnoid hemorrhage associated with convulsions. Another girl, 2 years old, presented massive bleeding into the temporal lobe that resulted in permanent hemiplegia, convulsions were absent. Rapidly expanding mass lesion made emergency surgery imperative (Fig 2).

A few cases of cavernous hemangiomas that have been published show a particular evolution. Because of the fact that recurrent moderate bleeding results in slowly progressing damage to brain tissue, the disease is mistaken for a brain tumor.

Phakomatosis frequently involves the cere-

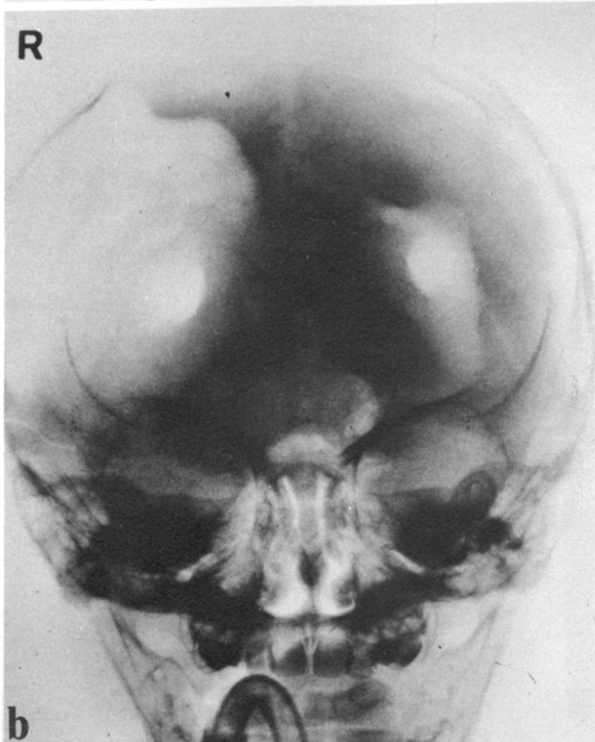
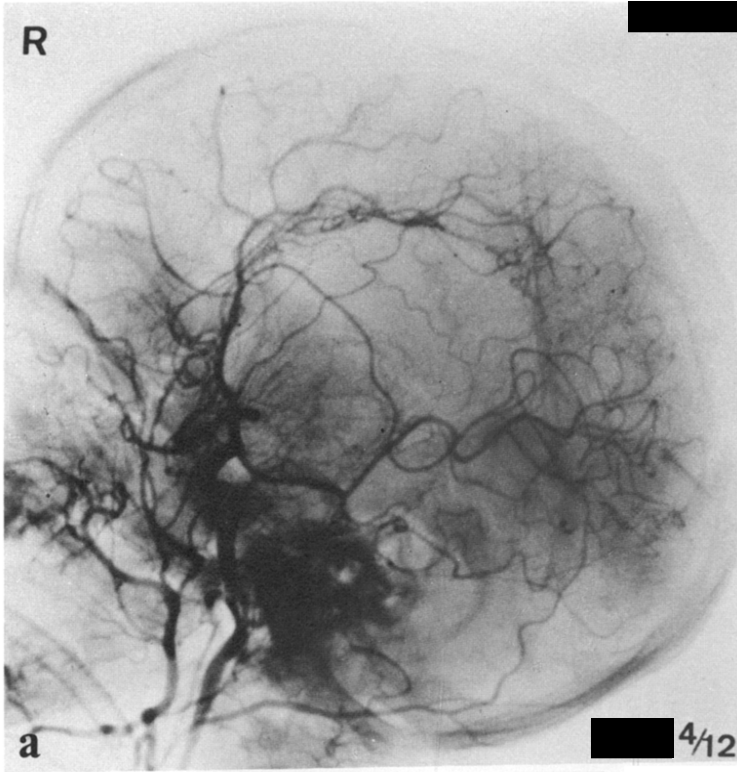


Fig 4 Occlusion of the middle cerebral artery during fetal life (a). Porencephaly in the deprived area (b). 4-month-old boy.

brovascular system. I should like to discuss a particular form of *pure venous angioma* situated in one hemisphere only and associated with strictly homolateral vascular nevus of the face (Fig 3a, b). We observed this disease in three children aged 9 months, 1 and 2 years respectively. The first child, a girl, was admitted to hospital with sudden hemiplegia while intracranial hemorrhage was absent, the other two patients showed convulsions. One of them is of particular interest since on serial angiography we almost missed the malformation the reason being that it opacified very late at the end of an already markedly prolonged venous phase [3]. It is interesting to note that calcification of brain parenchyma did not occur in any of our patients, not even after many years, 18 years at the utmost. This contrasts to the findings in Sturge-Weber phakomatosis.

Now I should like to discuss some aspects of *acquired arterial occlusion*. This disease may already occur during *fetal life*. We observed seven cases. All of them had a history of normal pregnancy and birth, the infants did not show any sign of postnatal disease that may have accounted for arterial occlusion. In all patients, a huge porencephalic cyst or a circumscribed ventricular dilatation associated with arterial occlusion was disclosed on neuroradiological examination (Fig 4a, b). One child in this group was born at term, again pregnancy and delivery were reported to be normal. The newborn had marked microcephaly, head circumference measured 29 cm only; otherwise the clinical condition appeared to be normal. At 3 months the infant was admitted to hospital with cerebral palsy involving the extremities to a comparable extent. At the age of 4 right sided hemiparesis became apparent and angiography was performed. It showed absence of the left internal carotid artery from its origin at the common carotid bifurcation. Pneumoencephalography demonstrated marked ventricular dilatation in the region of the middle cerebral artery. The rest of the hemisphere seemed sufficiently supplied by blood from the circle of Willis. A possible etiology may be a monozygotic twin pregnancy in which one fetus dies and undergoes resorption thus causing embolism in the common fetal circulation. Necrotic material from the placenta may likewise produce embolism.

In recent years occlusion of cerebral arteries in children became a topic of wide interest.

Table 1 *Diagnostic criteria of the "Moyamoya" syndrome*

Clinical features	Cerebrovascular episodes leading to more or less regressive deficits Relapses often alternating between the right and left sides Intellectual regression Convulsions Motor sequelae
Radiology	Bilateral distal stenosis of the internal carotid arteries Large collateral network Progression to complete obstruction of the main arterial channels Distal branches not affected
Etiology	Unknown Absence of specific arterial lesion ? Acquired frequent intercurrent infection or trauma ? Congenital: affected siblings; associated vascular malformations

Thus the "*Moyamoya*" syndrome became well-known (Table 1). Since I do not wish to carry owls to Athens, I shall refrain from further diagnostic comments. We were able to follow up nine patients with "*Moyamoya*," four of them between 5 months and 2½ years of age. In contrast to other cases published the disease took a much more severe course in our observations. One boy died at home of status epilepticus when he was 15 months old. One girl suffers from serious disablement due to bilateral spastic hemiparesis and severe mental retardation starting at the age of 2. Another girl showed gradually progressing hemiparesis since the age of 9 months while mental development now, at the age of 2 years and 6 months, appears to be satisfactory. In these three children, "*Moyamoya*" was diagnosed during infancy. The fourth child in this group was the only one whose motor development was not impaired, he is mentally retarded, though. An additional three out of nine cases differ from classical "*Moyamoya*" in so far as follow-up angiography, performed several months after onset of the disease, revealed the occlusion to be restricted to one side only (Fig 5a, b).

Another case seems worth mentioning: This

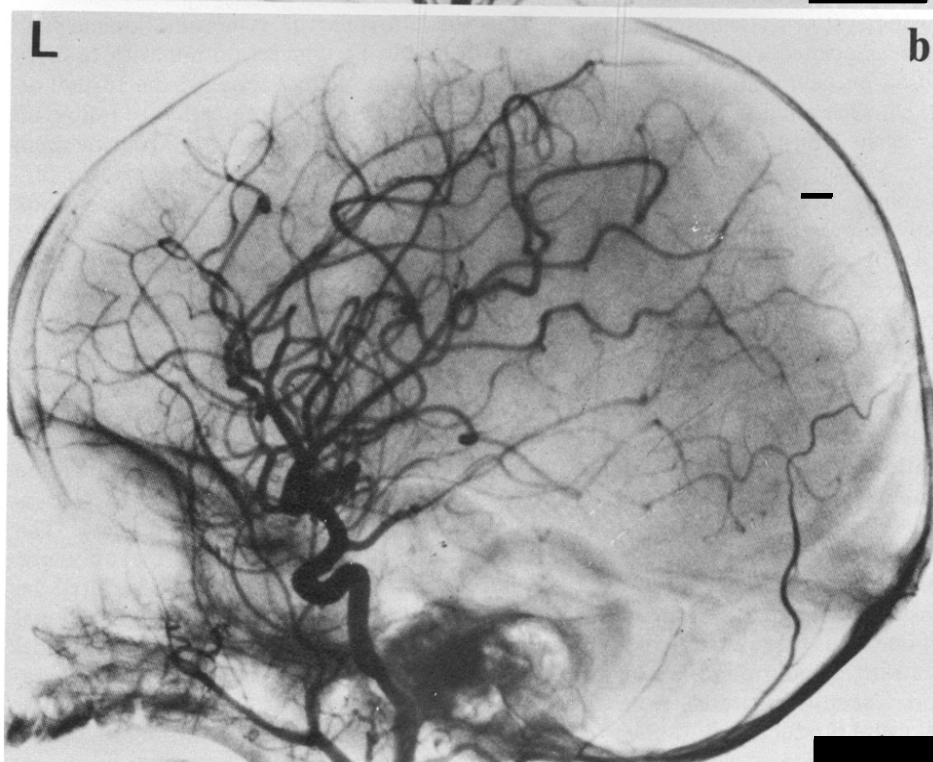
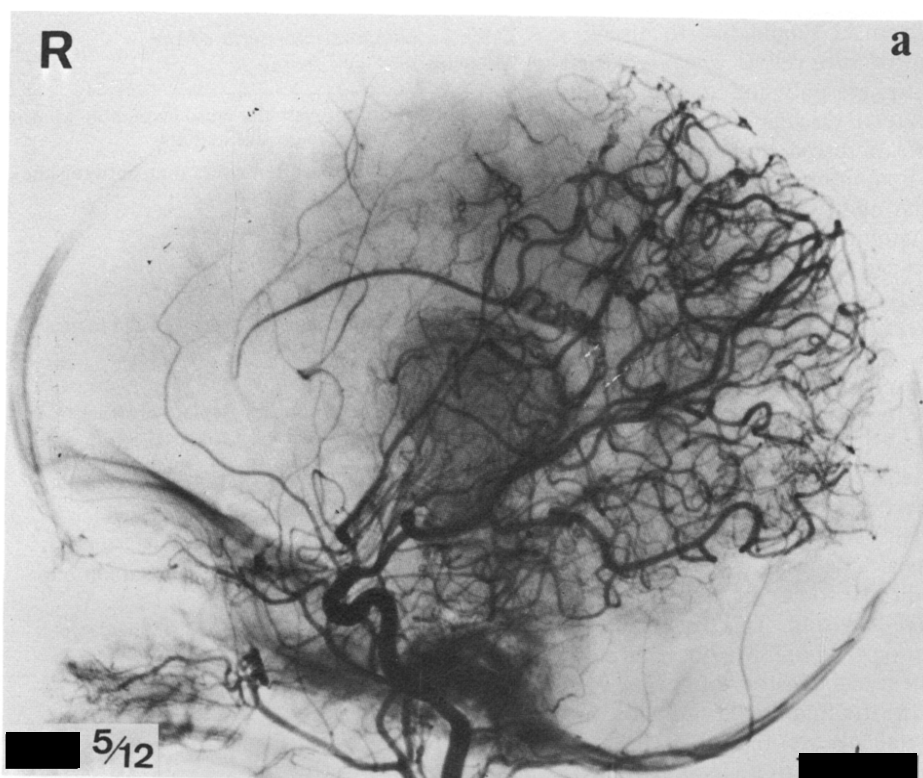


Fig 5 Unilateral "Moyamoya" syndrome in a 5-month-old girl.
a) affected side, b) spared side.

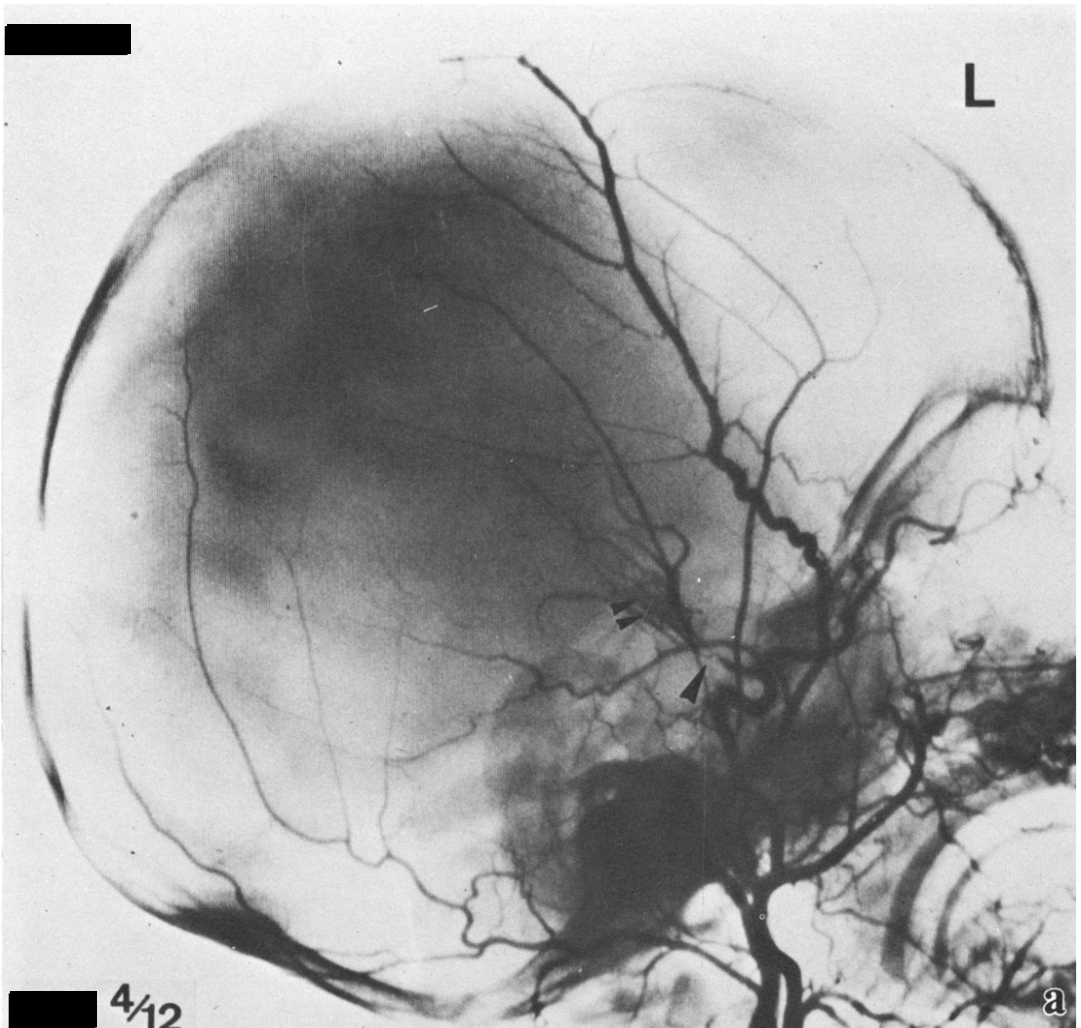


Fig 6 Transient "Moyamoya" syndrome (a). Repeat angiography 10 days later: disappearance of arterial stenosis and collateral network (b). Anterior cerebral artery supplied from contralateral side (c). 4-month-old girl.

girl was 4 months old when she had a banal infection of the upper respiratory tract. Because of continued fever she was admitted to our hospital 1 week after the onset. On admission the child suddenly developed hemiconvulsions that lasted a few minutes, they were followed by hemiparesis. Cerebrospinal fluid contained 250 cells; bacterial cultures, however, were negative. On angiography you will be able to recognize a "Moyamoya" pattern showing stenosis of the internal carotid artery at the site of the siphon and a network of collaterals at the site of the basal ganglia (Fig 6a). On repeat an-

giography 10 days later, the carotid stenosis as well as the collateral circulation were absent (Fig 6b, c).

This observation raises a few intriguing questions as to the etiology of the disease. Though comprehensive surveys have recently been completed, we still do not know whether "Moyamoya" is an acquired disease or whether it is a congenital form of angiodysplasia [6, 7]. Histological findings invariably demonstrate unspecific alterations of the wall, i.e. hyperplasia of the intima and disruption of the elastic laminae. There was no evidence for either an

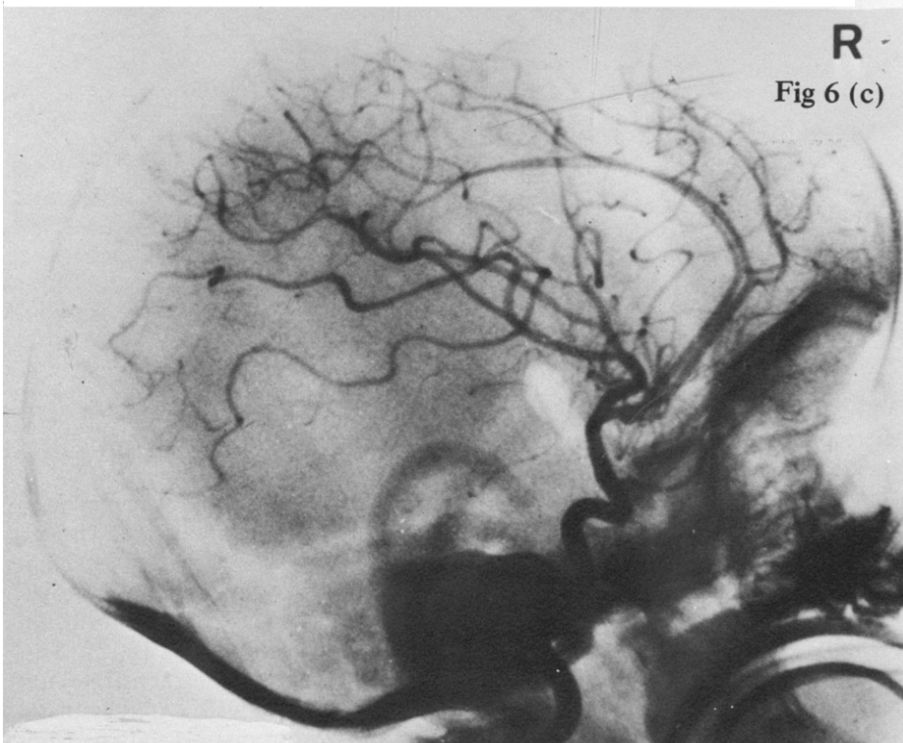
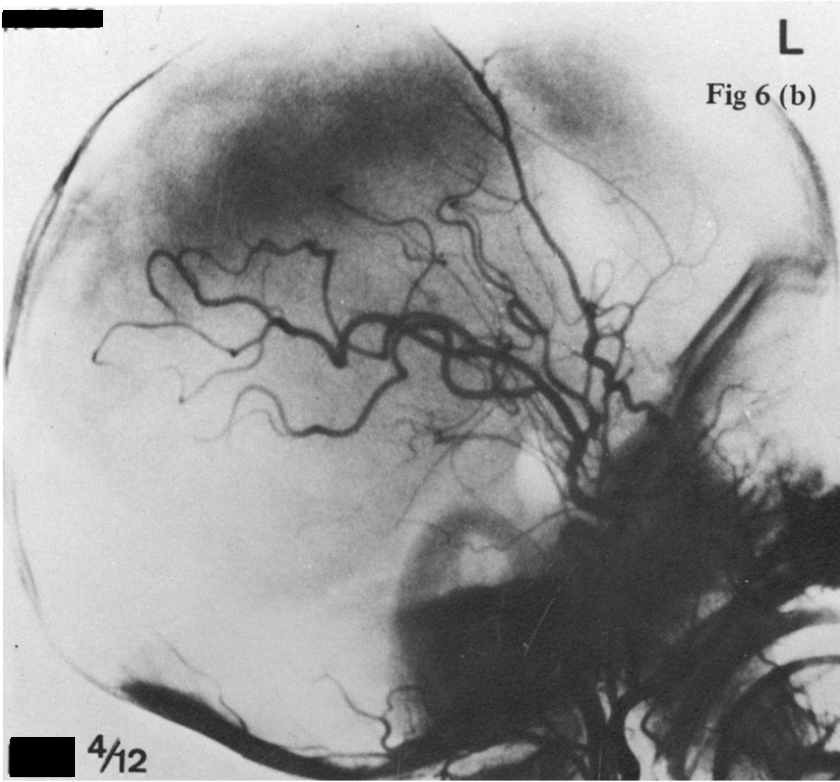


Fig 6 Continued.

infectious or a degenerative disease. Collateral vessels were made up of normal though enormously dilated capillaries.

The patient we just discussed showed a transient pattern characteristic of Moyamoya. Undoubtedly cranial infection has something to do with it. The swiftness with which the signs of vascular lesion disappeared is, at the least, remarkable. We do not know why "Moyamoya" did not fully develop in this case.

Recurrence of "Moyamoya" within the same family seems a point in favor of congenital malformation. Another point in favor of the latter is the sometime evident association of "Moyamoya" with unambiguous malformations such as aneurysms or phakomatosis. Thus, many questions remain to be answered.

I firmly believe that our understanding of cerebrovascular disease in children would greatly profit by efficient coordination of observations made worldwide. We on our part are hap-

py and willing to contribute to it as much as we possibly can.

References

1. Lipper S, Morgan D, Krigman MR, Staab EV. Congenital saccular aneurysm in a 19-day-old neonate: case report and review of the literature. *Surg Neurol* 1978;10:161-5.
2. Orozco M, Trigueros F, Quintana F, Dierssen G. Intracranial aneurysms in early childhood. *Surg Neurol* 1978;9:247-52.
3. Isler W. Acute hemiplegias and hemisyndromes in childhood. *Clin Dev Med Nos* 41/42, London: William Heinemann, 1971.
4. Kelly JJ. Intracranial arteriovenous malformations in childhood. *Ann Neurol* 1978;3:338-43.
5. Sing CS. Cerebral arteriovenous malformations in children. *Child's Brain* 1978;4:242-50.
6. Lévesque M, Lefebvre J, Bories J, Legré J. Infantile forms of the syndrome of progressive stenosis of branches of the polygone of Willis. *J Neuro-radiol* 1974;1:55-68.
7. Picard L, Lévesque M, Crouzet G, Simon J, André JM. The "moyamoya" syndrome. *J Neuro-radiol* 1974;1:47-54.