

CLINICAL CHALLENGES

RONALD M. BURDE AND PAUL HENKIND, EDITORS

Significance of Scintillating Scotoma of Late Onset

LAWRENCE A. RAYMOND, M.D., GEORGE KRANIAS, M.D., HELEN GLUECK, M.D., AND MARY ANN MILLER, B.S.

The Retina and Vitreous Service of the Department of Ophthalmology, and the Department of Pathology, University of Cincinnati Medical Center, Cincinnati, Ohio

Abstract. Scintillating hemianopic scotomas are usually caused either by migraine or, more rarely, vertebral-basilar insufficiency. We report two patients in whom this symptom was probably caused by platelet microthrombi or microemboli in pial vessels of the visual cortex. These patients were similar in that they had scintillating scotomas which began after the age of fifty and abnormal platelet aggregability. Since increased platelet aggregability is associated with cerebral vascular accidents and is treatable, older patients who develop teichopsias should have appropriate hematological tests. (*Surv Ophthalmol* 25:107-113, 1980)

Key words. estrogen • migraine • platelet aggregability
• scintillating scotoma • teichopsia • transient cerebral ischemia

The scintillating hemianopic scotoma begins often as a luminous, zigzag, shimmering sensation at its outer boundary, expanding toward the periphery and lasting for ten minutes or longer.^{1,14} The onset of these scotomas after the fortieth year of age is rare and should arouse suspicion that the patient has another cerebral vascular disease.⁴⁷ Scintillating scotomas of late onset have been described with cerebral vascular insufficiency,¹⁵ systemic lupus erythematosus (SLE),⁵ estrogens,³⁸ migraine,¹² mitral valve prolapse syndrome (Barlow's syndrome),²⁴ and after cardiac surgery.⁶

We report two patients who experienced their first teichopsias after the age of fifty. These teichopsias of late onset have received little attention from ophthalmologists. The confusion with migraine in the stroke-prone age warrants the description of this ischemic entity.

Case Reports

CASE 1

A 51-year-old medical secretary had her first scintillating scotoma in early February 1977 while driving home. She noted the upper right portion of a stopsign was missing when

viewed by either eye; a crescent of bright colors formed the outer edge of the scotoma. The episode persisted for twenty minutes. On May 7, 1977, a similar attack occurred while she was in a room lit only by candlelight.

She had not had "sick" headaches with nausea, vomiting, speech difficulty, weakness, ataxia, epilepsy, or a family history of migraine. One episode of teichopsia was followed by transient hemihypesthesia.

She had taken conjugated equine estrogen (Premarin®) 1.25 mg daily for the past eight years since a hysterectomy and bilateral oophorectomy.

Her eyes and visual field were normal. A neurosurgeon found no abnormalities when he examined her; there were no bruits in the neck or clinical features of SLE. Cardiac evaluation did not reveal a midsystolic click and late systolic murmur of the mitral valve prolapse syndrome or murmur of mitral-annulus calcification.

Serum antinuclear antibodies (ANA) and the Westergren erythrocyte sedimentation rate were normal.

Radiography of the skull and computerized axial tomography with contrast were normal. Arteriography of the aortic arch, cervical vessels and the intracranial vessels demonstrated no abnormality. During the arteriogram the patient had a scintillating scotoma in the left visual field which persisted for at least ten minutes.

We suspected that her scintillating scotomas were related to platelet microthrombi or microemboli in the pial vessels of the visual cortex.¹⁵ While on 300 mg dipyridole (Persantin®) and 900 mg aspirin daily to prevent future platelet aggregation,^{25,32} she experienced only two abortive visual episodes lasting two minutes each.

Her platelet aggregability was studied after stopping aspirin, dipyridole and conjugated equine estrogen for ten days. Platelet aggregation with adenosine diphosphate (ADP), epinephrine, and collagen was normal as compared to a normal control.⁴⁴ Following 16 days of oral estrogen, aggregation with all three aggregating agents was markedly increased with standard dilutions of these agents, as compared with the previous studies and a second normal control.⁴⁴ During these 16 days the patient experienced three classic scintillating scotomas. Because she refused to discontinue the use of estrogen, the dose was reduced to 0.625 mg daily and aspirin and

dipyridole were resumed. No teichopsias have occurred since.

CASE 2

A 75-year-old right-handed physician had the first of several scintillating scotomas which persisted for about twenty minutes at the age of 65 years. He had had similar attacks about twice a year since then; they were more frequent in his left hemianopic field, but occasionally occurred in the right. He did not have "sick" headaches, numbness in the extremities, speech difficulty, weakness, ataxia, epilepsy, or family history of migraine.

Propranolol hydrochloride (Inderal®) and methyldopa (Aldomet®) controlled his blood pressure at 150-160/90-100. He had a dissecting abdominal aneurysm resected with replacement by an aortic graft in May, 1975, and successful bilateral retinal detachment surgery in July, 1975.

In November, 1977, his best corrected vision was limited to the counting of fingers at eight feet in the right eye and 20/60 in the left eye. Visual fields were full except for a small central scotoma in the right eye. The poor vision could be explained by the previous retinal detachment, which involved the macula of the right eye. Mild lenticular changes were in the left eye.

The neurological examination was normal. There were no bruits. Radiographs of the skull and an electroencephalogram were not remarkable. No recommendation for further evaluation or treatment was made because the condition remained stable for ten years.

In early September, 1978, the patient experienced transient confusion and difficulty in writing and mathematics. No permanent localizing neurological signs were discovered. On September 8, 1978, computerized axial tomography (CAT) revealed an almost totally calcified 1.5 cm aneurysm of the left internal carotid artery, probably just above the origin of the ophthalmic artery. Multiple old infarcts were noted in both cerebral hemispheres, including the right frontal lobe, with some cerebral atrophy. A small low density area, which enhanced with contrast material, was present in the left parietal region, suggesting an infarct less than two weeks old. Another small, low density area in the left internal capsule near the genu represented either a new or old infarct (Figs. 1 and 2).

On September 9, 1978, the patient

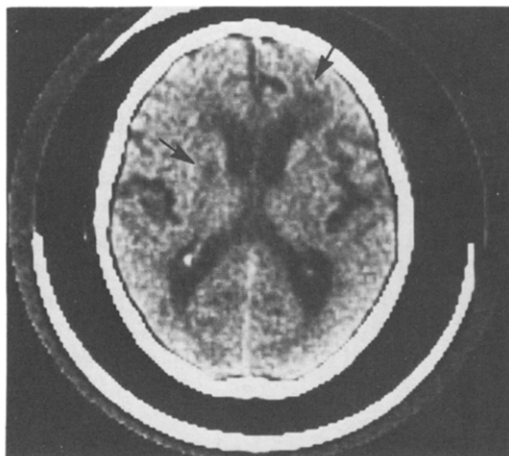


FIG. 1. (Case 2). Multiple infarcts (arrows) on computerized axial tomography (CAT) scan one day prior to right hemiparesis.

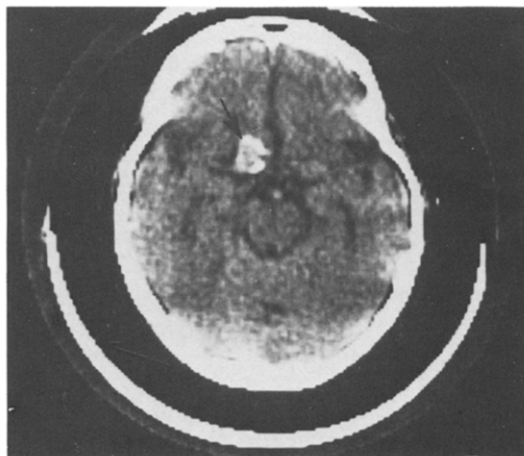


FIG. 2. (Case 2). Left presellar calcified aneurysm (arrow) above the origin of the ophthalmic artery on CAT scan.

suddenly developed right hemiparesis and difficulty expressing himself. Although he was readmitted to the hospital, he refused to have cerebral arteriography performed. He was treated with anticoagulants (heparin and Coumadin®). He was walking when discharged seven weeks later.

In early December, 1978, he lost vision in the left eye for two hours. When we examined him several days later we found two shiny, orange emboli in the arterioles of the left retina. The carotid pulses were good and we heard no cervical bruits. His platelet aggregability was markedly increased with ADP, epinephrine, and collagen when compared with the control.⁴⁴ The glucose tolerance test was normal. Because of a prior bleeding prepyloric ulcer, he was treated with 300 mg of aspirin only twice weekly along with the Coumadin®.³⁹

On March 17, 1979, the patient experienced a sudden blackout; echocardiogram was suggestive of aortic dissection. He died on March 23. Autopsy demonstrated no prolapsed mitral valve, mitral-annulus calcification, or platelet-fibrin thrombus adherent to the valves. Dissection of the ascending aorta associated with an intimal tear was found. Permission was not granted for examination of the central nervous system.

Discussion

UNFORMED VISUAL HALLUCINATIONS

Photopsias or unformed visual hallu-

cinations of retinal or vitreous origin may be confused with scintillating scotomas. Although there are exceptions, photopsias lasting for a few seconds or less may occur with acute posterior vitreous separation,⁴³ retinal emboli,^{15,30} retinal tear,⁴³ retinal detachment,⁴³ and Irvine-Gass syndrome.¹⁸ Brief punctate phosphenes have been described with acute optic neuritis.⁹

Multiple firefly-like flashes, lasting minutes to days, are seen in paracarcinomatous retinal receptor degeneration, where the lung is usually the distant site of cancer.⁴⁰

Occipital arterio-venous malformations are characterized by brief light flashes, generalized seizures, and cranial bruits.⁴⁵

LASHLEY'S SCINTILLATING SCOTOMA

Lashley,²⁰ a neurophysiologist, mapped his own expanding scintillating scotomas of migraine. Starting on either side of fixation, the scotoma subtended less than one degree. Over a twenty minute period, it drifted toward the temporal field of one side, increasing in size. Its shape was maintained during this spread. The scotoma was symmetrical in both eyes. Its leading edge was the fortification figures, consisting of luminous, dancing, angular lines. Rarely, there was complete hemianopia. He did not suffer the headache at the conclusion of the scotoma.

Lashley²⁰ predicted that the fortification figures were a function of the anatomic substrate of the visual cortex. Hoyt and Walsh⁴⁷

hypothesized that the orderly, repetitive patterns in columnar units found in Hubel and Wiesel's^{16,17} surface maps of the cat's visual cortex were similar to Lashley's fortification figures.

SPREADING CORTICAL DEPRESSION OF LEAO

Lashley²⁰ calculated a rate of 3 mm/min for the propagation of the scintillating disturbance in his visual cortex. Milner³¹ hypothesized that this visual phenomenon is related to the spreading depression (SD) of Leão,^{21,22} because they both have a striking similarity in their rate of spread.

The SD of cortical activity of Leão,^{21,22,27} described in experimental animals, consists of a marked reduction of electrical activity, appearing first in the area stimulated and spreading out from there; this negative phase is preceded and succeeded by smaller amplitude positive phases. Concurrently, the pial veins acquire an arterial hue and their flow increases, suggesting the possibility of arteriovenous shunting.

SD can be elicited by mechanical, electrical, photic, thermal, and chemical stimuli, arterial occlusion, and intense neuronal stimulation.^{21,27,48} Recently, cortical glucose utilization has been found to be increased during SD and in columnar units running perpendicularly through the cortex during recovery from SD.⁴¹

Hoyt and Walsh⁴⁷ hypothesized that spreading cortical events may be initiated by a focus of ischemia or chemovascular decompensation resulting in a scintillating scotoma.

PROBLEMS DIFFERENTIATING MIGRAINE AND VERTEBROBASILAR TRANSIENT ISCHEMIC ATTACKS

There are problems in differentiating the scintillating scotomas of vertebrobasilar transient ischemic attacks (TIAs) and migraine. The teichopsias are closely akin, if not identical.^{15,47} Headache may sometimes follow a TIA.¹⁵ Yet, migrainous scotoma with no headache following has been described;^{2,3} Alvarez² reported its occurrence in 12% of men and 0.7% of women.

A family history of migraine lends support to the diagnosis. The nonmigrainous scintillating scotoma is difficult to diagnose if the patient has a past history of migraine in youth.

Cerebrospinal abnormalities of gamma-

aminobutyric acid (GABA) and 3', 5' cyclic adenosine monophosphate (cyclic AMP) indicate that ischemia occurs in both migraine and TIA, but does not differentiate them.⁴⁹

Angiography in either condition rarely reveals a vascular lesion to explain the teichopsias because they are transient and apparently due to alterations in the cerebral microcirculation.^{10,11,47}

The exacerbation of a scintillating scotoma with arteriography in the patient described in Case 1 strongly suggests migraine. This increased morbidity of arteriography in migraine patients stresses the importance of discovering by other means whether the patient with a scintillating scotoma is migrainous.^{23,33,37} Five of 27 migraine patients (19%) experienced neurological complications with carotid angiography.³³ However, the overall complication rate in 604 arteriograms was 4.6%.³³ More recently, in 5000 arteriographies, Mani²⁶ noted a 1.6% overall complication rate, including a 0.02% mortality rate.

Fisher¹² recently described 37 patients with visual transient migrainous accompaniments (TMAs) of late onset with normal angiography. He believed a strong argument can be made for the migrainous nature of such transient deficits despite the absence of prior headache or transient attacks.

Both conditions lack clinicopathological correlation. A rare exception is reported by Polyak.³⁶ He describes the case of F. B. Mallory, the eminent pathologist, who had a permanent visual field defect after a scintillating scotoma of migraine. A shrunken malacic scar in the lower calcarine lip of the right occipital lobe was discovered at autopsy.

ETIOLOGY AND PATHOGENESIS OF TIA AND SCINTILLATING SCOTOMA

Hoyt hypothesized that some scintillating scotomas of late onset may be due to microemboli.¹⁵ Many other TIAs are due specifically to platelet, cholesterol or fibrin emboli arising from an atherosclerotic plaque.⁵³ Clinical attention has been drawn to platelets because of their central importance in the formation of arterial thrombi and initiation of vascular injury.^{15,25} Histologic study of platelet emboli reveals aggregates of platelets without fibrin, cholesterol, or red blood cells.²⁸

Litman and Friedman²⁴ hypothesized that increased aggregability of platelets may allow

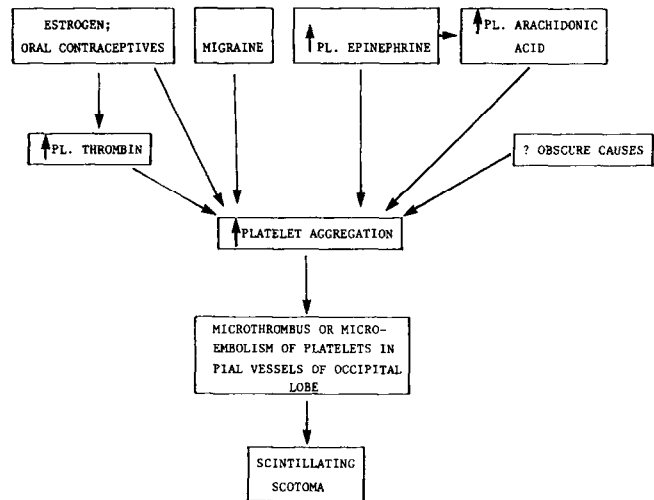


FIG. 3. Possible pathogenesis of scintillating scotoma of late onset. Pl. refers to plasma. (Modified after Deshmukh and Meyer¹⁰).

for embolically induced attacks of migraine from the abnormal mitral valves of Barlow's syndrome. In their patients, propranolol, a beta-adrenergic blocking agent, eliminated these episodes; propranolol⁴⁸ can decrease platelet aggregation and sympathetic tone.

Kalendovsky¹⁹ found increased platelet aggregation in four patients with stroke, two of whom had classical migraine. Deshmukh¹⁰ discovered enhanced platelet aggregation during the prodrome of three migraine patients, but not during the headache phase. Others¹³ have indicated that platelets may play a role in migraine pathogenesis. The possible pathogenesis of scintillating scotomata of late onset in our two patients is shown in Fig. 3, where platelet aggregation may have a role.

Willis and coauthors⁵² have reviewed the rapidly developing field of prostaglandins and platelet reactivity. The production or prevention of a platelet thrombus depends on a balance in vivo between arachidonate and dihomo- γ -linolenate. Linolenates are precursors of thromboxane A₁ which in turn is the precursor of prostaglandin E₁. The latter substance inhibits platelet aggregation. On the other hand arachidonates are precursors of thromboxane A₂, finally prostaglandin E₂, a potent vasoconstrictor and platelet aggregating substance.

NATURAL HISTORY OF TIA

It is generally agreed that patients with TIAs are more likely to develop a stroke,

although the precise magnitude of the risk is controversial.³⁹ Among patients with TIAs who do not die of a cause other than stroke, about one-third will experience a stroke within five years of the first attack.⁵⁰ Among patients with TIAs who experience a stroke within five years, more than 20% will do so within one month of the initial attack, and about 50% will do so within one year.⁵¹ Cartledge and associates⁷ found no difference in the probability of the occurrence of stroke between patients with vertebral-basilar TIAs and carotid TIAs.

ESTROGEN AND STROKE

Women who use oral contraceptives have an increased risk of stroke.⁸ Scintillating scotomas have been brought on by oral contraceptives.³⁸ In many patients taking these drugs increased blood viscosity,⁴ enhanced platelet adhesiveness and aggregation^{29,34,54} have been demonstrated. These changes are probably due to the estrogen component of the oral contraceptives.⁴²

Summary

Two patients with late onset of scintillating scotomas had increased platelet aggregation. The transient visual phenomena were probably related to estrogen therapy in one patient and atherosclerotic disease for the second patient. Both conditions can give rise to platelet microthrombi or microemboli, thus predisposing to cerebral ischemia includ-

ing scintillating scotomas. Since the stroke-prone patient is over 40, scintillating scotomas of late onset may have a serious import, especially if associated with increased platelet aggregation.

Acknowledgments

We are grateful to Doctors Ghahreman Khodadad and Samuel Trufant for the neurological evaluation of our patients, to Doctor Joel Sacks for reviewing the manuscript, and to Mrs. Joan Ausdenmoore for typing it.

References

1. Airy H: On a distinct form of transient hemiopia. *Philos Trans R Soc Lond* **160**:247-264, 1870
2. Alvarez WC: The migrainous scotoma as studied in 618 persons. *Am J Ophthalmol* **49**:489-504, 1960
3. Aring CD: The migrainous scintillating scotoma. *JAMA* **220**:519-522, 1972
4. Aronson HB, Magora F, Schenker JG: Effect of oral contraceptives on blood viscosity. *Am J Obstet Gynec* **110**:997-1001, 1971
5. Brandt KD, Lessell S: Migrainous phenomena in systemic lupus erythematosus. *Arthritis Rheum* **21**:7-16, 1978
6. Caplan LR, Weiner H, Weintraub RM, Austen WG: "Migrainous" neurologic dysfunction in patients with prosthetic heart valves. *Headache* **16**:218-221, 1976
7. Cartlidge NEF, Whisnant JP, Elveback LR: Carotid and vertebral-basilar transient cerebral ischemic attacks: a community study, Rochester, Minnesota. *Mayo Clin Proc* **52**:117-120, 1977
8. Collaborative group for the study of stroke in young women: Oral contraception and increased risk of cerebral ischemia or thrombosis. *N Engl J Med* **288**:871-878, 1973
9. Davis FA, Bergen D, Schauf C, McDonald I, Deutsch W: Movement phosphenes in optic neuritis: a new clinical sign. *Neurology* **26**:1100-1104, 1976
10. Deshmukh SV, Meyer JS: Cyclic changes in platelet dynamics and the pathogenesis and prophylaxis of migraine. *Headache* **17**:101-108, 1977
11. Edmeads J: Cerebral blood flow in migraine. *Headache* **17**:148-152, 1977
12. Fisher CM: Transient migrainous accompaniments (TMAs) of late onset. *Stroke* **10**:96-97, 1979
13. Gawel M, Burkitt M, Rose FC: The platelet release reaction during migraine attacks. *Headache* **19**:323-327, 1979
14. Gowers WR: Subjective visual sensations (Bowman Lecture). *Trans Ophthalmol Soc UK* **15**:1-38, 1895
15. Hoyt WF: Ocular symptoms and signs, in Wylie EJ, Ehrenfeld WK (eds): *Extracranial Occlusive Cerebrovascular Disease: Diagnosis and Management*. Philadelphia, WB Saunders, 1970, pp 36, 88
16. Hubel DH: The visual cortex of the brain. *Sci Am* **209**:54-62, 1963
17. Hubel D, Wiesel T: Shape and arrangement of columns in cat's striate cortex. *J Physiol* **165**:559-568, 1963
18. Irvine SR: A newly defined vitreous syndrome following cataract surgery interpreted according to recent concepts of structure of vitreous (Proctor Lecture). *Am J Ophthalmol* **36**:599-619, 1953
19. Kalendovsky Z, Austin J, Steele P: Increased platelet aggregability in young patients with stroke. *Arch Neurol* **32**:13-20, 1975
20. Lashley KS: Patterns of cerebral integration indicated by scotomas of migraine. *Arch Neurol Psychiat* **46**:331-339, 1941
21. Leão AAP: Spreading depression of activity in cerebral cortex. *J Neurophysiology* **7**:359-390, 1944
22. Leão AAP: Pial circulation and spreading depression of activity in cerebral cortex. *J Neurophysiology* **7**:391-396, 1944
23. Lesler J, Klee A: Complications of 337 percutaneous vertebral angiographies. *Acta Neurol Scandinav* **41**:301-314, 1965
24. Litman GI, Friedman HM: Migraine and the mitral valve prolapse syndrome. *Am Heart J* **96**:610-614, 1978
25. Management of thrombosis (editorial). *Lancet* **1**:361-362, 1971
26. Mani RL, Eisenberg RL, McDonald EJ Jr, et al: Complications of catheter cerebral arteriography: Analysis of 5,000 procedures. I. Criteria and Incidence. *Am J Roentgenol* **131**:861-874, 1978
27. Marshall WH: Spreading cortical depression of Leão. *Physiol Rev* **39**:239-279, 1959
28. McBrien DJ, Bradley RD, Ashton N: The nature of retinal emboli in stenosis of the internal carotid artery. *Lancet* **1**:697-699, 1963
29. Mettler L, Selchow BM: Oral contraceptives and platelet function. *Thromb Diath Haemorrh* **28**:213-220, 1972
30. Michelson JB, Whitcher JP, Wilson S, O'Connor GR: Possible foreign body granuloma of the retina associated with intravenous cocaine addiction. *Am J Ophthalmol* **87**:278-280, 1979
31. Milner PM: Note on a possible correspondence between the scotomas of migraine and spreading depression of Leão. *Electroencephalogr Clin Neurophysiol* **10**:705, 1958
32. O'Brien JR: Effects of salicylates on human platelets. *Lancet* **1**:779-783, 1968
33. Patterson RH, Goodell H, Dunning HS: Complications of carotid arteriography. *Arch*

- Neurol* 10:513-520, 1964
34. Poller L, Priest CM, Thomson JM: Platelet aggregation during oral contraception. *Br Med J* 4:273-274, 1969
 35. Poller L, Tabiowo A, Thomson JM: Effect of low-dose oral contraceptives on blood coagulation. *Br Med J* 3:218-219, 1968
 36. Polyak S: *The Vertebrate Visual System*. Chicago, University of Chicago Press, 1957, pp 735-747
 37. Prendes JL: Transient cortical blindness following vertebral angiography. *Headache* 18:222-224, 1978
 38. Salmon ML, Winkelman JZ, Gay AJ: Neuro-ophthalmic sequelae in users of oral contraceptives. *JAMA* 206:85-91, 1968
 39. Sandok BA, Furlan AJ, Whisnant JP, Sundt TM Jr: Guidelines for the management of transient ischemic attacks. *Mayo Clin Proc* 53:665-674, 1978
 40. Sawyer RA, Selhorst JB, Zimmerman LR, Hoyt WF: Blindness caused by photoreceptor degeneration as a remote effect of cancer. *Am J Ophthalmol* 81:606-613, 1976
 41. Shinohara M, Dollinger B, Brown G, et al: Cerebral glucose utilization: local changes during and after recovery from spreading cortical depression. *Science* 203:188-190, 1979
 42. Stolley PD, Tonascia JA, Tockman MS, et al: Thrombosis with low-estrogen oral contraceptives. *Am J Epidemiology* 102:197-208, 1975
 43. Tolentino FI, Schepens CL, Freeman HM: *Vitreoretinal Disorders: Diagnosis and Management*. Philadelphia, WB Saunders Co, 1976
 44. Triplett DA (ed): *Platelet Function, Laboratory Evaluation and Clinical Application*. Chicago, ASCP, 1978, pp 109, 277
 45. Troost BT, Newton TH: Occipital lobe arteriovenous malformations—clinical and radiologic features in 26 cases with comments on differentiation from migraine. *Arch Ophthalmol* 93:250-256, 1975
 46. Van Harreveld A: Discussion of Grafstein B: Neuronal release of potassium during spreading depression, in Brazier MA (ed): *Brain Function: Cortical Excitability and Steady Potentials; Relations of Basic Research to Space Biology, Proc First Conf, 1961*. Berkeley and Los Angeles, University of California Press, 1963, p 98
 47. Walsh FB, Hoyt WF: *Clinical Neuro-Ophthalmology, Vol 2 and 3*, Baltimore, Williams and Wilkins, 1969, ed 3, pp 1654-1667, 1707-1708, 1836-1841
 48. Weksler BB, Gillick M, Pink J: Effect of propranolol on platelet function. *Blood* 49:185-196, 1977
 49. Welch KMA, Chabi E, Nell JH, et al: Biochemical comparison of migraine and stroke. *Headache* 16:160-167, 1976
 50. Whisnant JP: A population study of stroke and TIA: Rochester, Minnesota, in Gillingham FJ, Mowdsley C, Williams AE (eds): *Stroke*. New York, Churchill Livingstone, 1976, pp 21-39
 51. Whisnant JP, Matsumoto N, Elveback LR: Transient cerebral ischemic attacks in a community: Rochester, Minnesota, 1955 through 1969. *Mayo Clin Proc* 48:194-198, 1973
 52. Willis AL, Stone KJ, Hart M, et al: Dietary fatty acids, prostaglandin endoperoxides, and the prevention of thrombosis, in Silver MJ, Smith JB, Kocis JJ (eds): *Prostaglandins in Hematology*. New York, Spectrum Publications, 1977, pp 371-410
 53. Wylie EJ, Ehrenfeld WK: *Extracranial Occlusive Cerebrovascular Disease: Diagnosis and Management*. Philadelphia, WB Saunders, 1970
 54. Zuck TF, Bergin JJ, Raymond JM, et al: Platelet adhesiveness in symptomatic women taking oral contraceptives. *Thromb Diath Haemorrh* 26:426-430, 1971

Reprint requests should be addressed to Lawrence A. Raymond, M.D., Department of Ophthalmology, Holmes Hospital, University of Cincinnati Medical Center, Eden and Bethesda Avenues, Cincinnati, Ohio 45219.