

NOTE

RIGHT HEMISPHERE DOMINANCE FOR PRAXIS AND LEFT HEMISPHERE DOMINANCE FOR SPEECH IN A LEFT-HANDER

DAVID I. MARGOLIN

Department of Neurology, University of Oregon, Portland, OR 97201, U.S.A.*

(Received 14 April 1980)

Abstract—A left-handed woman suffered marked apraxia and agraphia in the non-dominant hand, without aphasia, following a large right hemisphere infarct. This is a case of co-dominance with reading and speech mediated by the intact left hemisphere and praxis by the damaged right hemisphere.

IN ABOUT 98% of right-handers; reading, speech, and praxis (including writing) are dependent upon an intact dominant left hemisphere and virtually independent of the non-dominant right hemisphere [1].

In left-handers, ambidexters, and in a small percentage of right-handers there is a more complex interaction between the two hemispheres in the mediation of language function. Such subjects may demonstrate a lateralization of language function to the right hemisphere, or, more likely, share language functions between two co-dominant hemispheres [2, 3].

The following is a case of a left-handed woman who demonstrates a marked divergence of hemisphere specialization, with right hemisphere dominance for praxis including writing and left hemisphere dominance for the other language functions.

CASE REPORT

This patient is a 62-yr-old strongly left-handed (non-inverted writing posture) black woman who worked as a 5th-6th grade teacher. There was no family history of left-handedness. She enjoyed good health except for adult onset diabetes mellitus which was controlled with tolbutamide. Four weeks prior to admission she suffered a transient left visual field cut which resolved spontaneously within several hours. She sought no medical attention, and 2 days later awoke with a dense left hemiplegia and left homonymous hemianopsia. She was initially hospitalized at another institution where computerized tomography (CT) scan revealed early edema formation in the distribution of the right middle cerebral artery.

The patient was transferred to this hospital 4 weeks following the infarct. At this time she had an unremarkable general physical examination including normal vital signs. On mental status testing she was alert and oriented in all three spheres. The interview was compromised by a moderate degree of inattention.

Cranial nerve examination was remarkable for a left homonymous hemianopsia and a marked gaze preference to the right. The eyes could be brought fully to the left via a strong stimulus such as a brightly colored ball. There was a moderate central facial palsy on the left, and a marked left hemiplegia with spastic tone.

The patient's speech was fluent without paraphasic errors. She understood commands and could name objects without error. Repetition was intact including "no ifs, ands, or buts". She could read and spell well. When writing spontaneously or to dictation, however, her graphics were markedly impaired (Fig. 1). Copying was somewhat better (Fig. 1). Frequently she would hold the pen in an awkward manner which made writing impossible. Praxis was markedly impaired in the right hand. Sometimes she would only make rudimentary movements to command, and at best she would use body part as object for such commands as brushing her teeth or combing her hair. Performance was not greatly improved by providing a model to imitate. At times she would even have difficulty using objects correctly in spontaneous activities, such as eating. She also displayed an intermittent autotopagnosia for the left arm, and usually there was an anosognosia for the left hemiplegia and left homonymous hemianopsia. A repeat CT scan performed 5 weeks following the insult (Fig. 2) revealed an extensive right-sided infarct in the middle cerebral artery distribution. The left hemisphere appeared normal.

*Requests for reprints to David Margolin at this address.

DISCUSSION

This case closely resembles the left-handed patient reported by HEILMAN *et al.* [4]. Their patient also displayed apraxia and agraphia of the right hand without aphasia following a right hemisphere infarct. Although originally left-handed, he had been trained to write with his right hand while in school. There are only a small number of well-documented cases of markedly disparate speech and handedness dominance in the world's literature [5]. Quite recently, VALENSTEIN and HEILMAN [6] described a left-handed patient who suffered agraphia and apraxia following a well-circumscribed right parietal infarct. Again, there was no evidence of aphasia in this patient. The fact that the patient could type with his left hand suggests that he was able to transfer linguistic information from his intact left hemisphere to the right hemisphere. His agraphia would then represent a true apraxia for writing rather than a disconnection syndrome.

These cases are consistent with the widely accepted theory that language functions are less rigidly lateralized in the left-handed population than in right-handers [2]. Right-handers, however, may also display a dissociation of language dominance. A right-handed patient reported by HEILMAN *et al.* [7], for example, displayed apraxia and agraphia without aphasia following a left hemisphere infarct. In right-handers with aphasia following right hemisphere lesions (crossed aphasia), praxis and writing are usually spared [1, 8]. In addition to demonstrating co-dominance, these patients serve to suggest that praxis is more consistently mediated by the hemisphere contralateral to the dominant hand than is speech.

HECAEN and SAUGUET [9], have studied the influence of familial incidence of left-handedness on cerebral dominance. In "familial" left-handers, left and right hemisphere lesions produced similar language deficits. "Non-familial" left-handers, however, displayed virtually no language deficit following right hemisphere damage. Our patient, a "non-familial" left-hander, obeys this prediction in that she displayed no dysphasia or reading disturbance. The severe dyspraxia, however, suggests a right hemisphere dominance for writing.

Our patient was reported to have used the non-inverted left-handed writing posture. LEVY and REID [10] have proposed that the inverted posture may be a result of ipsilateral language dominance. Other investigators [11], however, have not supported this hypothesis and the significance of writing posture with regard to cerebral dominance is unclear. The lack of speech or reading disturbance in our patient does not conform to the Levy hypothesis.

Dominance for reading may also be dissociated from dominance for language functions other than writing. ERKULVRAWATR [12] described a left-handed patient who suffered alexia without agraphia following a right occipital lobe hemorrhagic infarct. The Wada test demonstrated that this patient was left hemisphere dominant for speech. In this person, reading would appear to be mediated by the right hemisphere, and speech by the left.

The significance of our case rests in the apparent independence of speech and writing, two functions which are usually affected in tandem by lesions of the dominant hemisphere. The lack of speech disturbance in our patient despite an extensive right hemisphere infarct demonstrated that she was left hemisphere dominant for speech. The profound apraxia of her right hand, however, indicated that her right hemisphere was dominant for control of praxis including writing. In such patients, there appears to be anatomically and functionally distinct control mechanisms for speech and handedness.

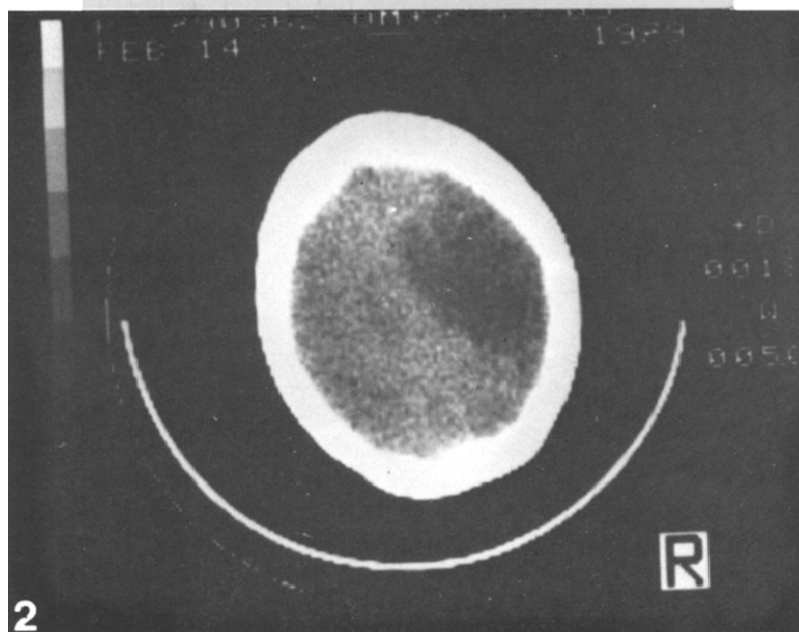
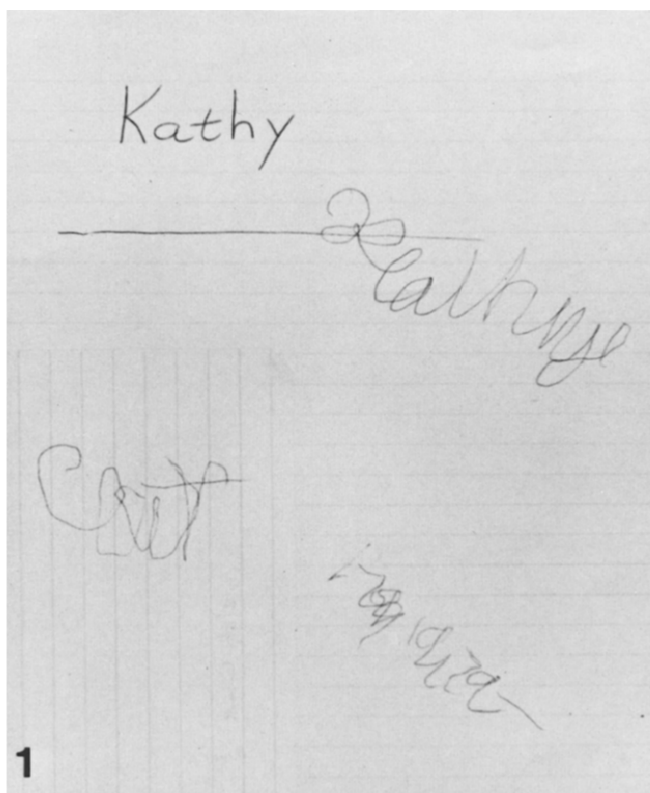
Acknowledgements—Thanks to DR. THOMAS ROSENBAUM for allowing the author to examine this patient, and to DR. ROBERT RAFAL for reviewing an early draft of the manuscript.

REFERENCES

1. ZANGWILL, O. L. Two cases of crossed aphasia in dextrals. *Neuropsychologia* 17, 167–172, 1979.
2. HECAEN, H. and ALBERT, M. L. *Human Neuropsychology*, pp. 84–87. J. Wiley, New York, 1978.
3. ETTlinger, G., JACKSON, C. V. and ZANGWILL, O. L. Cerebral dominance in sinistrals. *Brain* 79, 569–588, 1956.
4. HEILMAN, K. M., COYLE, J. M., GONYEA, E. F. *et al.* Apraxia and agraphia in a left-hander. *Brain* 96, 21–28, 1973.
5. POECK, K. and KERSCHENSTEINER, M. Ideomotor apraxia following right-sided cerebral lesion in a left-handed subject. *Neuropsychologia* 9, 359–361, 1971.

FIG. 1. At the top right-hand corner is the patient's attempt to copy the word Kathy which the examiner has printed at the top left-hand corner. At the bottom left-hand corner is the patient's attempt to write the word cat, and in the bottom right-hand corner to write May, 1979.

FIG. 2. The unenhanced CT scan demonstrates infarction in the entire right middle cerebral artery distribution. There was no change following contrast agent administration. The lucent area in the left hemisphere is the upper border of the Sylvian fissure.



6. VALENSTEIN, E. and HEILMAN, K. M. Apraxic agraphia with neglect-induced paraphasia. *Archs. Neurol.* **36**, 506-508, 1979.
7. HEILMAN, K. M., GONYEA, E. F. and GESCHWIND, N. Apraxia and agraphia in a right-hander. *Cortex* **10**, 284-288, 1973.
8. BROWN, J. W. and WILSON, F. R. Crossed aphasia in a dextral. *Neurology* **23**, 907-911, 1973.
9. HECAEN, H. and SAUGUET, J. Cerebral dominance in left-handed subjects. *Cortex* **7**, 18-48, 1971.
10. LEVY, J. and REID, M. Variations in writing posture and cerebral organization. *Science* **194**, 337-339, 1976.
11. HERRON, J., GALIN, D., JOHNSTONE, J. *et al.* Cerebral specialization, writing posture, and motor control of writing in left-handers. *Science* **20**, 1285-1289, 1979.

Résumé :

Une femme gauchère présentait à la suite d'un large ramollissement de l'hémisphère droit une agraphie et une apraxie importantes de la main non dominante sans aphasie. Il s'agit d'un cas de co-dominance, lecture et langage étant sous-tendus par l'hémisphère gauche intact et la praxie par l'hémisphère droit lésé.

Zusammenfassung

Eine linkshändige Frau bekam eine deutliche Apraxie und Agraphie in der nicht dominanten Hand ohne Aphasie nach einem großen rechtshemisphärischen Infarkt. Dies ist ein Fall, wo Lesen und Sprechen durch die intakte linke Hemisphäre und Apraxie durch die geschädigte rechte Hemisphäre verarbeitet wird.