

Visual Evoked Potentials in Occipital Lobe Lesions

Leopold J. Streletz, MD; Sung Ho Bae, MD; Robert M. Roeshman, DO; Norman J. Schatz, MD; Peter J. Savino, MD

● **Recording of visual evoked potentials (VEPs) to pattern reversal is considered to be a reliable diagnostic procedure for examining patients with anterior visual pathway lesions (optic nerves and chiasm). Less consistent results have been reported in studies of more posterior lesions. The VEPs were recorded in 20 patients with occipital lobe lesions. A maximal VEP response (P_{90}) was recorded at the scalp electrodes situated over the involved occipital lobes and contralateral to the hemianoptic visual field defect, indicating a positive correlation of unilateral occipital lobe lesions, homonymous visual field loss, and the VEP abnormality.**

(Arch Neurol 38:80-85, 1981)

Visual evoked potential (VEP) recordings are recognized as a reliable diagnostic procedure in the investigation of lesions of the anterior visual pathways.¹⁻⁵ Geniculocalcarine lesions accompanied by hemianoptic visual field defects also show asymmetrical VEPs.² We report our experience with VEPs to pattern reversal stimuli in patients with occipital lobe lesions.

MATERIALS AND METHODS

Twenty patients (seven men and 13 women) with occipital lobe lesions were

selected for VEP studies to pattern reversal stimuli. Ages ranged from 22 to 71 years (mean, 56 years). All patients underwent neuro-ophthalmologic examination, including Goldmann perimetry. A computerized axial tomographic (CT) scan was performed for anatomical verification of the site of the lesion on all but one patient. Similarly, 20 (ten men and ten women) normal volunteers were studied according to the following technique. With the international 10-20 system of electrode placement, five scalp electrodes were located transversely in the temporo-occipital region (T_3 , O_1 , O_z , O_2 , and T_6) with a frontal (F_z) reference site (Fig 1). Electrodes were attached to the scalp with collodion jelly. Impedance was maintained between 1,000 and 3,000 Ω . The volunteers and patients were comfortably seated in a chair before a translucent screen on which a black-and-white checkerboard pattern was back-projected (Digitimer Pattern Generator 4330). They were instructed to fixate on a red dot at the center of the screen while the responses were being recorded. Each eye was tested separately. A stimulator (Grass S-8) rhythmically reversed this pattern by deflecting a small mirror system twice per second. The slew rate of the mirror system was 2.4 ms. The patterned screen subtended 30° of the visual angle. Each individual square made up 1° 15' of arc. The luminance of the screen measured 60 foot-lamberts.

The VEP signal was amplified (Grass 8A5) with a bandpass of 1 to 1,000 cps. A four-channel averaging computer (Nicolet 1072) was triggered by the stimulator. The analysis time was 200 ms, and 128 responses were summated. The sampling rate was 1.25 kHz. The resulting VEP signals were recorded on an X-Y plotter (Hewlett-Packard 7035 B). The averaging process was continuously displayed on an oscilloscope (Tektronix RM 504) to monitor artifacts of electrical or biological origin. Individual VEPs were superimposed to aid in differentiating time-locked from random activity. The peak latency, amplitude, and distribution of the VEP were compared with the patients.

RESULTS

Full-field stimulation of 20 normal volunteers resulted in a VEP response with maximal amplitude in the midline (O_z). This response was a triphasic wave form with negative-positive-negative components. The peak latencies (mean \pm SD) for these components were 71.0 ± 3.6 , 94.0 ± 5.6 , and 134.0 ± 9.5 ms. The major positive potential was the most consistent and largest component with a mean amplitude of 14.7 ± 4.6 μ V measured peak to peak from the preceding negative potential. Measureable amplitude asymmetries at lateral occipital recording sites (O_1 and O_2) were said to have a predominance on the side of greatest amplitude. The mean difference in amplitude for 20 subjects was 0.5 ± 2.7 μ V, which suggested no definite predominance of either side. (The mean difference amplitude between the O_1 and O_2 recording sites was calculated as follows: [$X\mu$ V (O_1 lead) - $Y\mu$ V (O_2 lead) OS] + [$X'\mu$ V (O_1 lead) - $Y'\mu$ V (O_2 lead) OD]/2 = amplitude difference in a subject [P_{90} , peak-peak].)

In all 20 patients with occipital lobe abnormalities (18 occipital infarcts, two biopsy-proved tumors), some form of VEP abnormality was detected (Table 1). All lesions were associated with congruous homonymous visual field defects and two patients (No. 9 and 20) displayed Riddoch's phenomenon.⁶

In two patients (No. 19 and 20) with bilateral occipital lobe infarctions, grossly abnormal VEP wave forms were obtained that made determination of predominance impossible. In patients 17 and 18, the peak latency of the major positive component was delayed in the absence of demonstra-

Accepted for publication April 24, 1980.

From the Department of Neurology, Jefferson Medical College, Thomas Jefferson University, Philadelphia (Drs Streletz, Bae, and Roeshman); Neuro-ophthalmology Unit, Wills Eye Hospital, Philadelphia (Drs Schatz and Savino); and the Departments of Neurology and Ophthalmology, University of Pennsylvania, Philadelphia (Drs Schatz and Savino).

Reprint requests to Department of Neurology, Thomas Jefferson University Hospital, Room 9606 NH, 11th and Walnut streets, Philadelphia, PA 19107 (Dr Streletz).

ble abnormality of anterior visual pathways. Both patients had left occipital lobe infarctions, but no definite amplitude asymmetry was detected.

In 15 of 18 patients (patients 1 through 16) with unilateral occipital lobe lesions and homonymous visual field defects, the P_{94} component had the greatest amplitude ipsilateral to the lesion and contralateral to the visual field defect. This predominance applied whether the right or left occipital lobe was involved (Fig 2). Predominances were also observed in two cases (No. 8 and 12) with superimposed ocular and optic nerve lesions.

All three groups (normal subjects and the two groups of unilateral left

[six] and right [12] occipital lobe lesions) demonstrated highly significant intergroup variation with regard to predominance of the P_{94} component (Fig 2). With the use of the Newman-Keuls method, the groups were found to differ significantly among themselves ($P < .01$ for normal vs right and for left vs right and $P < .05$ for normal vs left). Although differences in amplitude were dissimilar between groups, this measurement was not effective in distinguishing individual patients with unilateral occipital abnormalities from normal subjects (Table 2).

Despite this limitation under some clinical circumstances when an occipi-

tal lesion was suspected and objective laboratory confirmation was needed, this technique proved to be a useful adjunct to the neuro-ophthalmologic evaluation (Table 1, patients 6, 9, and 10).

REPORT OF CASES

CASE 15.—A 64-year-old woman noted the sudden onset of inability to see to on the right three months prior to examination. This remained unchanged and was unaccompanied by neurologic or visual symptoms. Neuro-ophthalmic examination revealed visual acuity of 6/6 bilaterally. The results of pupillary and ophthalmoscopic examinations were normal. An exquisitely congruous right homonymous hemianoptic scotoma was detected on visual field testing. Neurologic examination gave normal results. Potassium perchlorate brain scan and skull x-ray films were normal. An EEG was normal, but VEP testing revealed a left-sided predominance. Computerized tomographic scan revealed a low-density area in the left occipital lobe consistent with infarction (Fig 3, left).

CASE 5.—A 46-year-old man had a convulsive seizure disorder. A large occipital meningioma was discovered and removed. He remained well for four years, when he had another generalized seizure. Following removal of a recurrent occipital meningioma, he complained of decreased vision. His visual acuity was 6/6 bilaterally. Perimetry revealed a left inferior homonymous paracentral scotoma. Pupillary reaction and results of ophthalmoscopy were normal. The CT scan revealed encephalomalacia and focal dilation of the occipital horn of the right lateral ventricle. The VEP disclosed predominance of the P_{94} component over the right temporo-occipital region (Fig 3, right).

COMMENT

In studies of cerebral lesions producing homonymous visual field defects, flash stimulation VEPs have demonstrated reduction in amplitude of early components of the response recorded from occipital leads ipsilateral to the side of the lesion.⁷⁻⁹ There are, however, considerable difficulties between patients and within individual patients in distinguishing such changes from normal variations with the flash technique. Earlier investigations with full-field pattern reversal techniques have not identified consistent abnormalities in posterior visual pathway lesions.^{3,4}

One difficulty in the interpretation of pattern-reversal VEP findings is the paradoxical lateralization of the normal half-field response in transverse temporo-occipital scalp leads. Barrett et al reported that the half-field responses in referential and bipolar recordings appeared asymmetrical and had a potential maxi-

Fig 1.—Normal computerized tomographic scan indicating location of recording electrodes in relation to occipital lobes (top). Visual evoked potentials show symmetrical distribution of P_{94} component (bottom).

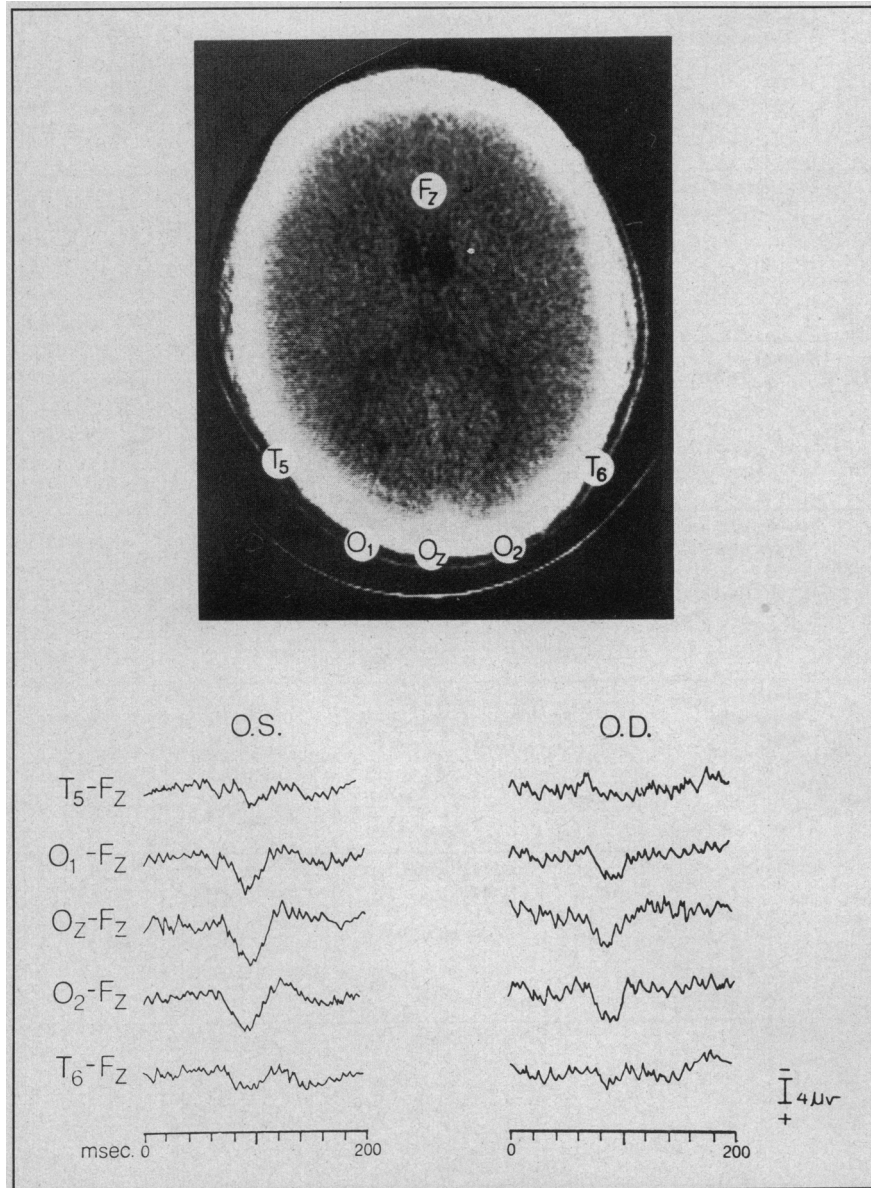


Table 1.—Twenty Patients With Occipital Lobe Lesions

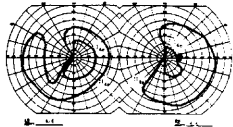
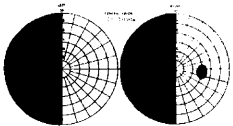
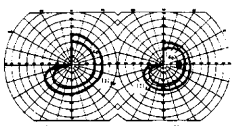

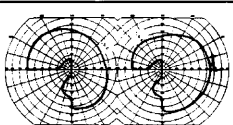
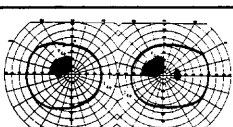
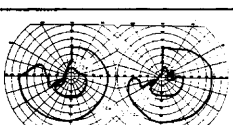
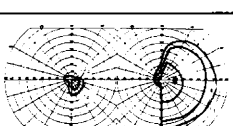
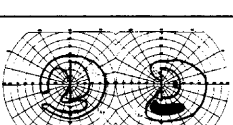
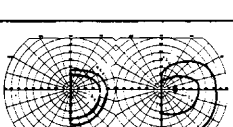
Patient/Age, yr/Sex	Clinical Diagnosis	Computerized Tomographic Scan	Visual Evoked Potential	Visual Field
1/47/M	Occipital lobe infarction (R)	Low-density area R occipital lobe	Predominance R side	
2/70/F	Occipital lobe infarction (R)	Low-density area R occipital lobe	Predominance R side	
3/67/F	Occipital lobe infarction (R)	Low-density area R occipital lobe	Predominance R side	
4/36/M	Occipital lobe metastasis (R)	Low-density area R occipital lobe	Predominance R side	
5/46/M	Occipital lobe meningioma (R)	Low-density area R occipital lobe	Predominance R side	
6/59/F	Occipital lobe infarction (R)	Normal	Predominance R side	
7/65/F	Occipital lobe infarction (R)	Low-density area R occipital lobe	Predominance R side	
8/71/M	Optic atrophy (L), occipital lobe infarction (R)	Low-density area R occipital lobe	No response (OS) Predominance R side (OD)	
9/54/F	Occipital lobe infarction (R)	Normal	Predominance R side	
10/22/F	Occipital lobe infarction (R), migraine	Normal	Predominance R side	

Table 1.—Twenty Patients With Occipital Lobe Lesions (cont)

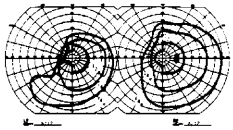
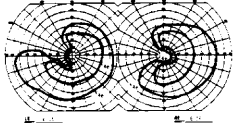
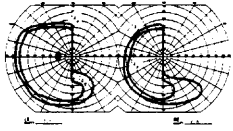
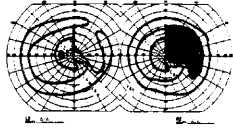
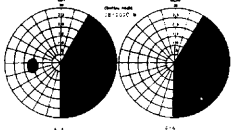
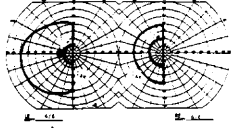
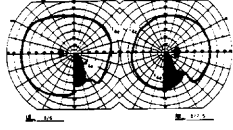
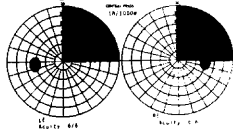
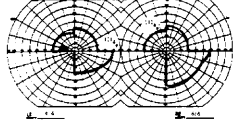
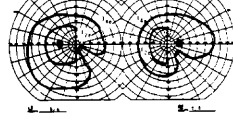
Patient/Age, yr/Sex	Clinical Diagnosis	Computerized Tomographic Scan	Visual Evoked Potential	Visual Field
11/67/F	Occipital lobe infarction (R)	Low-density area R occipital lobe (?), cortical atrophy	Predominance R side	
12/51/F	Occipital lobe infarction (R), maculopathy (R), and aqueductal stenosis	Ventricular dilation, R occipital porencephaly	Predominance R side	
13/42/F	Occipital lobe infarction (L)	Low-density area L occipital lobe, cortical atrophy	Predominance L side	
14/57/F	Occipital lobe infarction (L)	Low-density area L occipital lobe	Predominance L side	
15/70/F	Occipital lobe infarction (L)	Low-density area L occipital lobe	Predominance L side	
16/67/F	Occipital lobe infarction (L)	Low-density area L occipital lobe	Predominance L side	
17/64/M	Occipital lobe infarction (L)	Low-density area L occipital lobe	Symmetrical but delayed	
18/52/M	Occipital lobe infarction (L)	Not done	Symmetrical but delayed	
19/63/M	Bilateral occipital lobe infarctions	Low-density area both occipital lobes, R > L	Grossly abnormal wave forms	
20/57/F	Bilateral occipital lobe infarctions	Low-density areas both occipital lobes, hydrocephalus	Grossly abnormal wave forms	

Table 2.—Predominance of P₉₄ Component of Visual Evoked Potential

	Normal	Occipital Lobe Lesions	
		L	R
Mean difference, μ V	0.5	3.0	-3.3
SD	± 2.7	± 2.0	± 2.1
n	20	6	12

imum for the major positive component (P₁₁₀) on the side ipsilateral to the stimulated side of the visual field.¹⁰ They proposed a simple dipole model to explain their findings and located the cortical generators for this component of the response in the posteromedial surface of the occipital lobes. In this model, the scalp electrodes located in the midline and lateral sites in the temporo-occipital region ipsilateral to the stimulated half field are best

aligned to record from the generators in the contralateral visual cortex. This finding was confirmed in nine healthy subjects and was used to predict the type of response asymmetry to be found in cases of homonymous hemianopsia with full-field stimulation. The full-field response in patients with hemispherectomy and occipital lobectomy have subsequently shown the predicted lateralization of the response to the side of the surgical removal.^{2,11,12} Thus, unilateral occipital lobe lesions paradoxically leave unaffected responses recorded on the side of clinical involvement that are generated in the intact contralateral occipital lobe.

The VEP findings in our patients with occipital lobe abnormalities are consistent with this hypothesis. A demonstrable predominance of the P₉₄ component was present over the involved side in 83% of our patients with unilateral occipital lobe lesions and a homonymous hemianoptic visual field defect. Similar findings have been reported by Carlow and Rodriguez¹³ in studies of posterior cerebral dysfunction with this technique (transient pattern response).

We confirm a positive correlation between occipital lobe damage, ho-

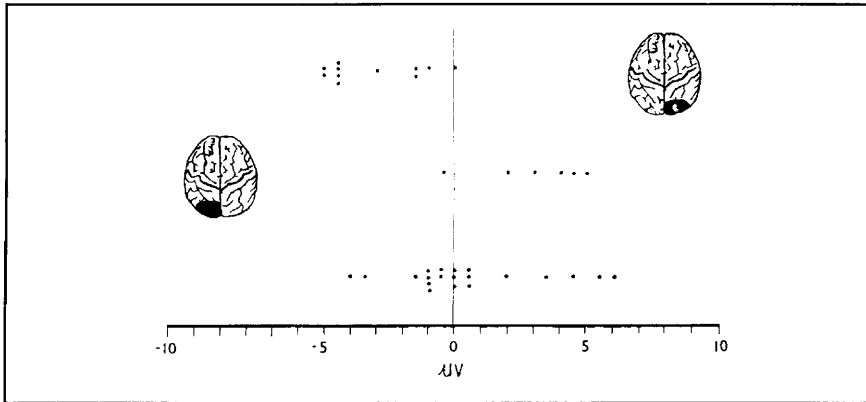


Fig 2.—Correlation between side of lesion and visual evoked potential predominance in 18 patients and 20 control subjects. Scattergram shows mean differences (P₉₄) in amplitude (microvolts) in patients with right (top) and left (middle) occipital lobe lesions compared with control subjects (bottom).

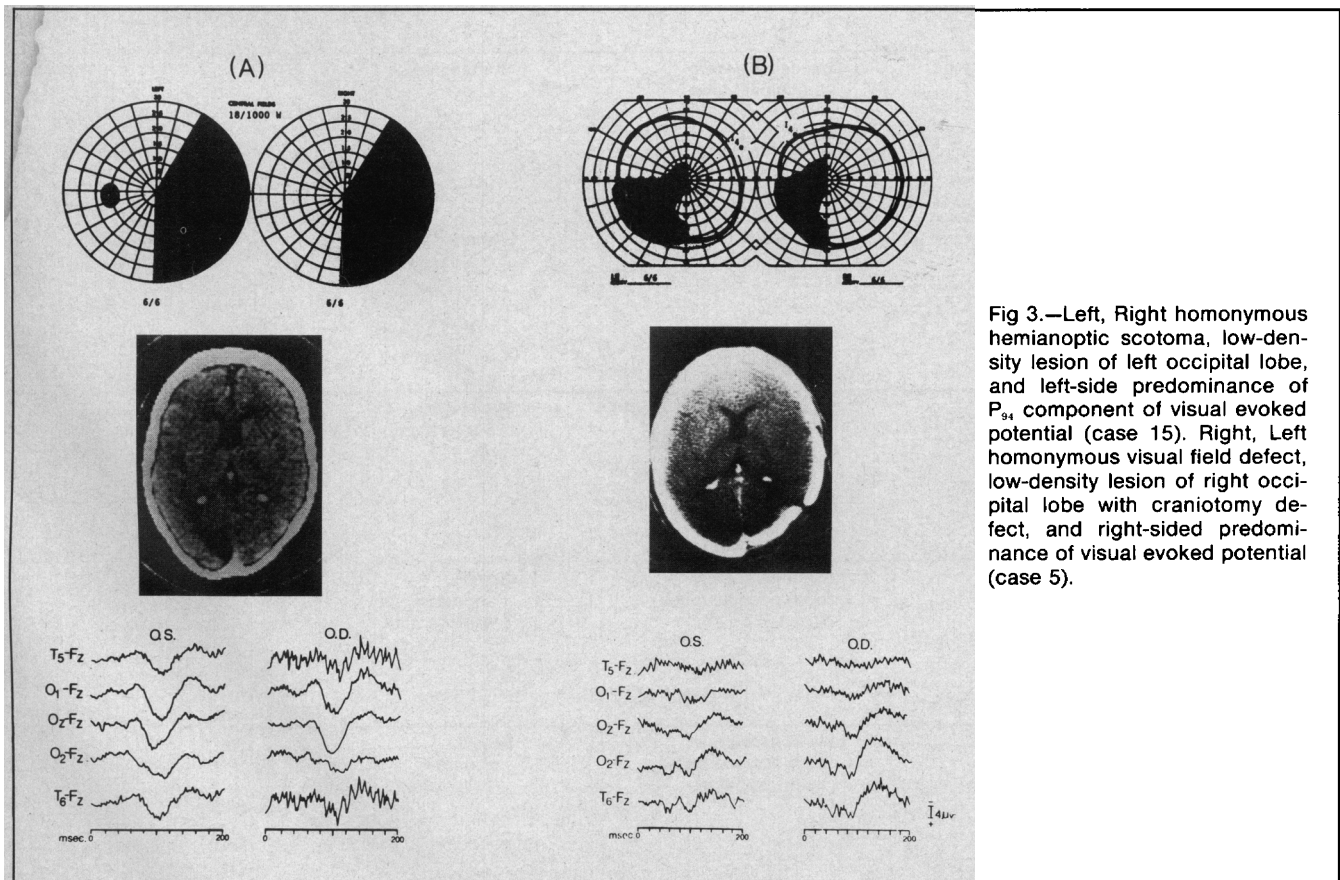


Fig 3.—Left, Right homonymous hemianoptic scotoma, low-density lesion of left occipital lobe, and left-side predominance of P₉₄ component of visual evoked potential (case 15). Right, Left homonymous visual field defect, low-density lesion of right occipital lobe with craniotomy defect, and right-sided predominance of visual evoked potential (case 5).

monymous visual field defects, and abnormalities of the VEP, especially a predominance of the P₉₄ component ipsilateral to unilateral lesions. The presence of asymmetry on VEP alone is not prima facie evidence of occipital lobe damage, since normal subjects have asymmetry in some cases. However, when this finding is combined with a visual field deficit, the asymmetry (with increased amplitude over the involved occipital lobe) is highly suggestive of occipital lobe damage. We caution that our patient population comprised exclusively destructive lesions, and recent reports indicate that irritative lesions may show a reversal of the patterns we describe.¹³

The abnormal wave forms detected in our two patients with bilateral occipital lobe lesions probably arise from

grossly disorganized generators in preserved calcarine cortex or visual association areas. The delayed peak latencies and symmetrical appearance of responses in two patients with left occipital lobe lesions is more difficult to explain. Ashworth et al¹⁴ reported such VEP delays in an autopsy case of bilateral visual pathway abnormality (astrocytoma of corpus callosum) with no anterior visual pathway lesions. The usefulness of the VEP observations in this instance seems limited by the fact that single-channel recording was obtained without comparison to control subjects from their laboratory. Nevertheless, the multichannel recordings of the P₉₄ component in our two patients (cases 17 and 18) indicate definite delays (110 and 130 ms, respectively), but none of our patients have had complete neuropathologic

examination. We cannot exclude subclinical anterior visual pathway involvement in our patients.

Supplementation of full-field VEP techniques with half-field steady state and/or flash stimulation^{11-13,15,16} may increase the specificity and accuracy of this technique as a diagnostic test. Nevertheless, it is clear that clinically useful VEP abnormalities are not confined to the anterior visual pathways, and further study of geniculocalcarine lesions will clarify the role of this technique in evaluating pathologic abnormalities of the posterior visual pathways.

Hyman Menduke, PhD, provided valuable help in the statistical analysis of the data. Miriam Heebner Kogan and Ruth Buley did the art preparation and typed the manuscript.

References

- Halliday AM, Halliday E, Kriss A, et al: The pattern-evoked potential in compression of the anterior visual pathways. *Brain* 99:357-374, 1976.
- Blumhardt LD, Barrett G, Halliday AM: The asymmetrical visual evoked potential to pattern reversal in one half field and its significance for the analysis of visual field defects. *Br J Ophthalmol* 61:454-461, 1977.
- Asselman P, Chadwick DW, Marsden CD: Visual evoked responses in the diagnosis and management of patients suspected of multiple sclerosis. *Brain* 98:261-282, 1975.
- Celesia GG, Daly RF: VECA: A new electrophysiologic test for the diagnosis of optic nerve lesions. *Neurology* 27:637-641, 1977.
- Holder GE: The effects of chiasmal compression on the pattern visual evoked potential. *Electroencephalogr Clin Neurophysiol* 45:278-280, 1978.
- Riddoch G: Dissociation of visual perception due to occipital injuries with especial reference to appreciation of movement. *Brain* 40:15, 1915.
- Vaughan HG, Katzman R, Taylor J: Alterations of visual evoked responses in the presence of homonymous visual defects. *Electroencephalogr Clin Neurophysiol* 15:737-746, 1963.
- Kooi KA, Guvener AM, Bagchi BK: Visually evoked responses in lesions of the higher optic pathways. *Neurology* 15:841-854, 1965.
- Oosterhuis HJGH, Ponsen L, Jonkman EJ, et al: The average visual response in patients with cerebrovascular disease. *Electroencephalogr Clin Neurophysiol* 27:23-34, 1969.
- Barrett G, Blumhardt LD, Halliday AM, et al: A paradox in the lateralization of the visual evoked response. *Nature* 261:253-255, 1976.
- Blumhardt LD, Barrett G, Halliday AM, et al: The effect of experimental 'scotomata' on the ipsilateral and contralateral responses to pattern reversal in one half field. *Electroencephalogr Clin Neurophysiol* 45:376-392, 1978.
- Hoepfner TJ, Bergen D, Morrell F: Visual evoked potentials after partial occipital lobectomy, abstracted. *Electroencephalogr Clin Neurophysiol*, to be published.
- Carlow TJ, Rodriguez M: Localization of cerebral dysfunction by visual evoked responses, abstracted. *Ann Neurol* 4:176, 1978.
- Ashworth BA, Maloney FJ, Townsend RA: Delayed visual evoked potentials with bilateral disease of the posterior visual pathways. *J Neurol Neurosurg Psychiatr* 41:449-451, 1978.
- Celesia G, Kuroiwa Y: Quantification of transient and steady-state evoked potentials during hemifield stimulation and its significance for the detection of visual field defects, abstracted. *Electroencephalogr Clin Neurophysiol*, to be published.
- Wildberger HGH, van Lith GHM, Wijn-gaarde R, et al: Visually evoked cortical potentials in the evaluation of homonymous and bitemporal visual field defects. *Br J Ophthalmol* 60:273-278, 1976.