

IDEATORY APRAXIA IN A LEFT-HANDED PATIENT WITH RIGHT-SIDED BRAIN LESION

Klaus Poeck and Gerd Lehmkuhl

(Abteilung Neurologie, RWTH, Aachen, West-Germany)

INTRODUCTION

The syndrome of ideatory apraxia is not uniformly described in the literature. There is general agreement that the diagnosis of ideatory apraxia is made when a patient exhibits faulty use of objects, and when this is due neither to a paralysis, sensory disturbance, lack of understanding of the task nor of recognition of the object, nor overall mental confusion. This last requirement holds true even though the first case reports, in particular those by Pick (1905), described patients who had diffuse brain damage and severe overall intellectual deficit.

Two opposed positions, however, are maintained in the literature with regard to the general motor setting where the faulty use of objects appears. Liepmann (1905, 1908) considered ideatory apraxia as an "Apraxie der Handlungsfolgen". For him the syndrome was a disturbance in the performance of complex actions involving the serial ordering of simple movements, which, in isolation, could be executed correctly. Along the same line Hécaen (1968) described ideatory apraxia as "an impairment of the logical and harmonious sequence of the several elementary movements that make up a complex act, though each movement by itself is executed correctly".

In sharp contrast, Morlaas (1928) advocated the view that the failure in complex serial motor actions was not crucial for the diagnosis of ideatory apraxia, and that the distinctive feature of the syndrome was a disturbance in the use of real objects, in simple as well as in complex serial movements. This view was adopted, among others, by De Renzi, Pieczuro and Vignolo (1968). The three cases described by Heilmann (1973) fall in neither category since their motor impairment was confined to pantomime, whereas the handling of real objects was intact.

Ideatory apraxia is considerably rarer than ideomotor apraxia. Hécaen (1968) found that ideomotor apraxia is six times more frequent than

ideatory apraxia. It is obvious that in research based on the definition of Morlaas a larger number of patients with ideatory apraxia is likely to be detected among a given population of brain damaged patients than in research based on Liepmann's concept. For instance, De Renzi, Pieczuro and Vignolo (1968) found ideatory apraxia in 28% of their left brain damaged patients. In contrast, Ajuriaguerra, Hécaen and Angelergues (1960) found the syndrome in only 4.7% of their left brain damaged patients.

With regard to the localization of the brain lesion, Pick (1905) had initially considered ideatory apraxia as a symptom of diffuse brain damage and this view was reiterated by Nielsen (1936) and Denny-Brown (1968). Later, Liepmann (1908) regarded the syndrome, like ideomotor apraxia, as the consequence of a circumscribed lesion in the hemisphere dominant for language. To-day there is general agreement that ideatory apraxia is one of the classical syndromes of damage to the left hemisphere, in particular to its posterior portions (Hécaen, 1960, 1968; Kimura and Archibald, 1974; Hécaen and Albert, 1978). Most authors (e.g. Alajouanine and Lhermitte, 1963) feel that the underlying brain lesion is quite extensive. To our knowledge, no case has been described in the literature where ideatory apraxia was brought about by a focal right-sided brain lesion in a left-hander.

This raises the question of whether aphasia and ideomotor apraxia have an influence on the syndrome of ideatory apraxia. There is little agreement in the literature on the question of whether these three left hemispheric syndromes occur in close association (Nathan, 1947) or in relative independence (Hécaen, 1968; De Renzi et al., 1968). These problems are discussed extensively in Hécaen and Albert (1978).

The current state of affairs makes it desirable to publish well documented cases in which the syndrome of ideatory apraxia can be observed unequivocally and in which it is possible to ascertain the locus of the brain lesion as well as to determine the possible relation of the syndrome with aphasia and ideomotor apraxia. We want to discuss a case of ideatory apraxia in a left-handed patient with a right-sided brain lesion and a merely transient aphasia, but a persisting ideatory apraxia after the initial ideomotor apraxia had cleared. For reasons discussed in detail by Poeck (1978) we are going to follow the definition that ideatory apraxia is a disturbance in the motor organisation of a complex situation, requiring a series of movements, where the handling of actual objects is involved (Poeck and Lehmkuhl, 1980).

CASE REPORT

H.G., a sixty-nine-year old left-handed housewife, was admitted to our department on March 17th, 1978, because a rapidly expanding, space occupying

intracranial lesion was suspected. Personal and family history were unremarkable.

The evening prior to admission her husband found her confused and disorientated. She went to bed at about 10 in the evening. In the morning she was not able to get up, she talked very little and complained of a headache. During the following hours she became increasingly drowsy. On admission the patient was found somnolent; she was not co-operative and hardly reacted to questions and commands. Movements with the left arm and leg were reduced. She had a left-sided hemianopia.

The EEG showed a sleep pattern with a focal abnormality in the theta-delta range in the right basal temporal area. Computerized cranial axial tomography on the day of admission showed a marked impression of the right cella media and a slight displacement of the ventricular system to the left (Figure 1 A, B). There was hemorrhage located in the area of the posterior part of the sylvian fissure, about 4 cm in diameter and surrounded by an area of edema about 1 cm in diameter.

Following the day of admission the patient was still somnolent, disorientated, and she had a left-sided hemiparesis. Three days later a carotid angiography was performed. It did not reveal the source of the hemorrhage.

The patient's condition improved rapidly, so that she could move her left arm. She was, however, still disorientated. These symptoms cleared during the following days. A control CT (Figure 1 C, D) on March 30th, that is two weeks after admission, showed that the area of hemorrhage had diminished whereas the surrounding edematous area had increased. There was still a displacement of the ventricular system. The EEG now showed an irregular alpha rhythm, with delta activity over the entire right hemisphere.

NEUROPSYCHOLOGICAL FINDINGS

During the first days of hospitalization the patient had an aphasia of the Wernicke type. She spoke fluently with many semantic paraphasias. The structure of the sentences was paragrammatic, comprehension impaired. In naming tasks she made numerous errors. The aphasia improved over a period of about ten days. At this time the patient showed little initiative and had to be repeatedly encouraged to carry out the requested tasks.

Formal aphasia examination on April 6th

In her overall communicative behaviour the patient showed no discernible difficulties (Goodglass-Kaplan severity score of 4). The semantic and syntactic structure of her spontaneous speech production was only slightly impaired; phonemic errors did not occur. However the patient's speech did contain a number of stereotyped utterances. On the Token Test the patient achieved 7 points (corrected value, Orgass 1976a, 1976b), indicating only a very mild language disorder.

The patient was able to repeat isolated phonemes, monosyllabic words, compound nouns and sentences correctly.

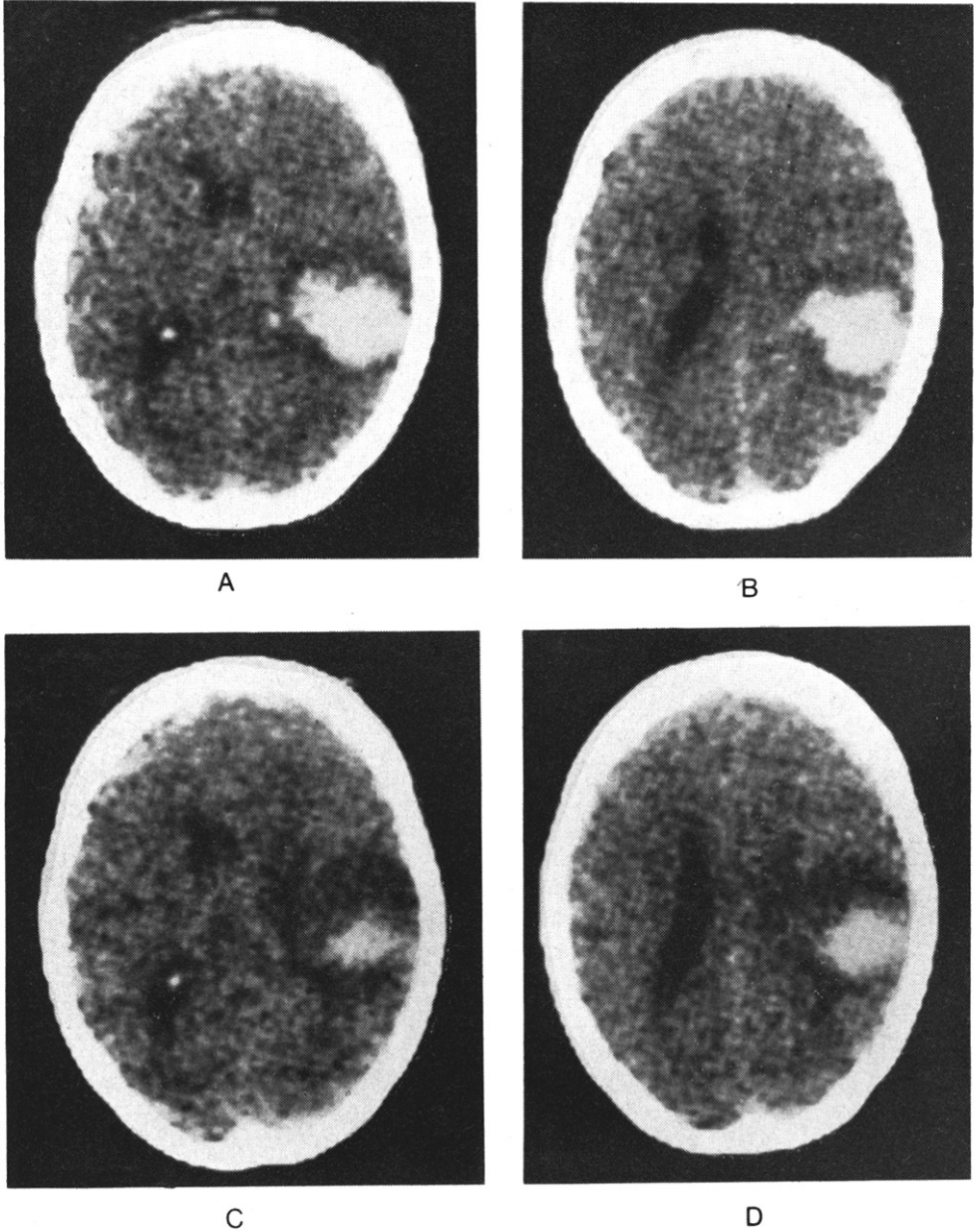


Fig. 1 — Computerized axial tomography of patient H. G.
A, B: 17.3.78, note large area of hemorrhage at the level of the posterior part of sylvian fissure, surrounded by edema. For details see text. C, D: 2 weeks after admission.

In a naming task she identified 22 out of 30 depicted objects, 27 of 30 colours were identified. In describing pictures the patient showed the same degree of impairment as when naming objects (18/30). The patient's comprehension for written words (23/30) was somewhat better than her auditory comprehension for words (19/30), however no difference was found between her comprehension for written and spoken sentences (18/30). In reading words and sentences aloud no paralexias could be observed. But when writing words and sentences on dictation many paraphasias were observed (24/120). The patient failed to put together block letters in response to dictated words and sentences. As usual, this aphasia due to a space occupying lesion could not be classified as a belonging to one of the major vascular aphasic syndromes.

Testing for intelligence on April 17th

The Performance IQ in the German version of the Wechsler Intelligence Test was 74. In all subtests the patient rated considerably below normal, whereas she was able to describe satisfactorily the visually presented test material. The Verbal IQ was not assessed because of the patient's aphasia.

Examination for ideomotor apraxia on March 31st

Table I summarizes the patient's performance in the symbolic and non-symbolic tasks for ideomotor apraxia. For each performance 10 tasks were given. The total number of tasks for ideomotor apraxia was 200. The percentage of tasks correctly solved is given in the table. The patient evidently had only a moderate bilateral ideomotor apraxia of both arms and legs.

TABLE I
Results of Examination for Ideomotor Apraxia

Task	On imitation	On verbal command
Symbolic movements		
right arm	60%	40%
left arm	80%	60%
both hands	80%	60%
right leg	90%	70%
left leg	80%	80%
Non-symbolic movements		
right arm	70%	80%
left arm	80%	80%
right leg	100%	90%
left leg	80%	80%
Oral apraxia tasks	60%	70%

Examination for ideatory apraxia on April 3rd

The patient was requested to perform a number of sequential actions requiring the use of various objects placed, separately for each of the tasks, in front of her. These tasks, together with the patient's performance, are described in the following (see Poeck and Lehmkuhl, 1980).

Hanging a picture on the wall. A picture, a nail and a hammer were placed in front of the patient. The patient commented adequately on the task and approached it without hesitation. She first tried to fix a tag on the picture although there was already one there. She then took the nail and pushed it through the tag, remarking: "It goes like this". She did not make use of the hammer and kept on pushing the nail through the tag. Only when the examiner indicated that there was a hammer at hand did she take it and try to hit the nail into the wall while the picture was hanging on the nail.

Telephoning. A telephone book and a telephone were in front of the patient. She first leafed over several pages of the telephone book. The examiner then pointed to the telephone. She turned the dial without lifting the receiver. She lifted the receiver after having dialled.

Putting butter and marmalade on a slice of bread. The patient had no difficulties performing the task.

Punching several sheets of paper and then putting them in a loose-leaf folder. Paper, a folder and a paper-punch were in front of the patient. The patient said: "The paper has to be put in there," and pointed to the folder. She took the sheets of paper in her hand and opened the folder. She stopped helplessly. When shown the paper-punch she correctly punched one sheet and put it into the folder, without making use of the two holes she had just made. After being corrected she was able to perform the task but immediately afterwards she took another sheet of paper and put it directly into the folder, without punching it.

Preparing a cup of coffee. A pot of water, a cup, a spoon, a jar of Nescafe, and a water immersion-heater (familiar object for Germans) were placed in front of the patient. The patient grasped the water immersion-heater and remarked: "I have to prepare coffee." After making several helpless movements with the heater the patient took the plug, put it into the water pot and stirred around with it. With a helpless expression on her face she said: "It does not work like this." For a moment she did not move at all. When the examiner pointed to the socket, she answered: "Well, that's it." It was only after several trials, however, that she managed to plug in the heater. Then she took the water immersion-heater again and did not know what to do with it. She aimed at the cup, hesitated,

and then correctly put it into the water pot. She opened the jar of Nescafe, but she did not know what to do with the coffee. She made a movement with the jar in the direction of the water pot and looked inquiringly at the examiner saying: "I know, that's not it," and she started to put the coffee into the cup. She did not use the spoon although she was told that there was one. She then took the spoon and stirred the coffee in the cup with no water in it.

Opening a tin. A tin, a tin opener, a spoon and a pot were in front of the patient. On seeing these objects the patient remarked: "To prepare a soup." She took the tin in her hands, turned it around and said: "Can be opened." But she continued to hold the tin in her hand until the examiner pointed to the tin opener. She then took the tin opener; however instead of using it properly, she beat on the tin with it several times. Only with the aid of the examiner did she manage to use the opener properly. She then stirred around in the tin with the spoon. After the pot was placed near her she started to spoon small portions of the peas into the pot (with a stirring spoon).

Arrangement of photographs showing segments of a sequential action. A test was developed to further investigate the patient's ability to organize correctly a sequential action (Lehmkuhl and Poeck, in press). The test consists of a series of tasks similar to the ones just described. However, instead of having the patient actually perform the actions, the entire series of events is represented on 5 - 7 photographs which show the single steps leading to the final result. The first photograph showed all the objects used in the task. The patient was requested to put these pictures in the correct order. Table II summarizes her performance. Again, her comments indicated that she recognized the objects.

TABLE II

*Performance in the Task of Arrangement of Photographs
(logical sequence = 1 - 4, 1 - 5 or 1 - 6, respectively)*

Task	Sequence of steps as indicated by the patient						
Putting on a coat	1	3	2	5	4		
Preparing coffee	1	3	4	2	5	7	6
Putting butter on bread	1	3	4	2	6	5	
Telephoning	1	2	3	5	4	6	
Putting on shoes	1	2	4	3	5	6	
Punching paper	1	6	3	4	5	2	
Opening a can	1	2	3	5	4		
Hanging up a picture	1	3	2	4	5		
Brushing teeth	1	2	5	4	3	6	

Putting together a puzzle. A further examination showed that the patient's impaired performance was not due to an inability to recognize (and imagine) objects visually. She was given five puzzles (a snake, a locomotive, a light bulb, a house, and a car). She succeeded to put the parts together with no difficulty.

Non-verbal vs. verbal processing of serial tasks

The patient was given a test in which she was required to order 6 pictures in such a way that a story resulted. The test (Huber, 1978) comprised nine such series of pictures. Besides having to order pictures the patient was also requested to order series of 6 sentences in such a way that a coherent text resulted. These sentences corresponded to the individual pictures in the mentioned picture ordering task. For each picture story there were two sets of sentences: in one set the six sentences were long and cohesively bound, in the other set they were short and had no cohesion. There was a total number of 27 tasks (3×9). In each of the 27 tasks the patient could achieve a maximum error score of 5 points. The results are given in Table III.

TABLE III

Performance in Non-Verbal versus Verbal Processing of Serial Tasks

	Error points	Possible error points
Pictures	18	45
Short, non-cohesive sentences	3	45
Long, cohesive sentences	2	45

DISCUSSION

Ideatory apraxia is defined here, following Pick (1905), Liepmann (1908), Ajuriaguerra, Hécaen and Angelergues (1960) and Zangwill (1970) as a neuropsychological syndrome where brain damaged patients are unable to carry out a series of actions requiring the use of various objects in the correct sequence necessary to achieve the desired goal. The following types of errors are observed: The logical sequence of single movements is not respected, i.e. objects are improperly used, or single movements constituting the action are skipped or repeated in a perseveratory manner.

As mentioned in the introduction, the faulty use of a single object in a single movement (Morlaas, 1928; Ajuriaguerra et al., 1960; Ajuriaguerra and Tissot, 1965) is not sufficient for the diagnosis of ideatory apraxia. This behaviour, in our view, is either indicative of a severe degree of

ideomotor apraxia where even the presence of an object is not able to evoke the correct movement or it demonstrates erroneous recognition of objects.

In our experience, even grossly incorrect performances still have some relation to the target action. We have not observed – neither in this case nor in other patients with ideatory apraxia – the behaviour described sometimes in the older literature (Pick, 1905; Nielsen and Ives, 1936; Nielsen, 1946) where patients carry out movements having no relation at all to the target action, like in the classical example described by Pick, where a patient bites into a piece of soap. In contrast to such cases of severe behavioural disturbance the patients we diagnose as having ideatory apraxia are able to name or describe the target action and the objects necessary, including those which they use improperly.

Most of the patients with ideatory apraxia, if not all, are aphasic. However, the reverse is not the case, only few aphasic patients have ideatory apraxia (Ajuriaguerra et al., 1960; De Renzi et al., 1968). The aphasia, as a rule, is of the Wernicke or global subtype. A high degree of severity of aphasia is no prerogative for the occurrence of ideatory apraxia (Ajuriaguerra et al., 1960; De Renzi et al., 1968). No intrinsic relationship between the linguistic features of the aphasic syndrome and the movement disorder can be concluded. We agree with De Renzi et al. (1968) that the presence of aphasia merely indicates a posterior lesion in the hemisphere dominant for language.

Our patient H.G. had Wernicke's aphasia in the first period of her illness. The aphasia, however, improved rapidly and was only very mild at a time where ideatory apraxia was still clearly demonstrable (see her good communicative performances, as evidenced by a Goodglass-Kaplan severity rating of 4). Ideatory apraxia therefore cannot be considered a language dependent disturbance in our patient. The improvement of aphasia in the presence of a persisting brain lesion suggests that in this patient, like in many other left-handers, language had a bilateral hemispheric representation.

The assumption of a disconnection syndrome does not appear plausible because ideatory apraxia was present with visual as well as somesthetic input. A disconnection mechanism (Geschwind, 1965) under these conditions would imply that in this case there was an extensive watershed lesion, as in the syndrome of isolation of the speech area (Geschwind, Quadfasel and Segarra, 1968). This syndrome, however, was not present in our case, neither clinically nor anatomically. The ideatory apraxia was in no way dependent on ideomotor apraxia. The ideomotor (limb and oral) apraxia, which was initially present in our case, had cleared very rapidly, quite similar to the Wernicke aphasia.

There remains the question whether ideatory apraxia in this case was

the consequence of a visual cognitive disturbance. We would not accept this hypothesis, because the patient was able to grasp the situation of the task immediately and to verbalize it. She recognized the single objects correctly, she named them and described the individual actions required to perform the whole sequence. She also showed good performance in the task of putting together jigsaw puzzles.

Several authors have put forward the question whether ideatory apraxia is the consequence of an overall intellectual deficit (Nielsen and Ives, 1936) or of a defective conceptual process (Denny-Brown, 1968). Some of the case descriptions by Pick and Liepmann might in fact suggest this assumption. Our patient was given the German version of the Wechsler Intelligence Test. Since she had a mild aphasia, we wanted to avoid a bias due to the language deficit. Therefore only the performance IQ was tested. The value of 74 points is clearly below normal. The patient's behaviour on the ward and during the examinations, however, gave clear evidence that she was not severely demented.

In our view, the basic disturbance in our patient was the inability to combine various movements into a purposeful sequential action. This deficit was apparent in three different situations:

- (a) handling of objects in the above described test situations,
- (b) placing pictures representing segments of sequential actions in correct order, and
- (c) arranging pictorial representations of stories, each consisting of six individual drawings.

The term "agnosie de l'usage" (Morlaas, 1928) does not appear to us appropriate for the behavioural deficit in ideatory apraxia. It is true that some aspects of these patients' behaviour suggest that they do not know how to use the objects in question. There are many other errors however which cannot be adequately explained on this basis. Frequently the patient fails just because of a sequential error, sometimes the same action is executed once correctly and then incorrectly, and, finally, quite often the patients are able to describe verbally or to indicate by gestures that they are aware of the use of the objects. The sequential deficit could be demonstrated also in tasks where no actual use of objects was required.

ABSTRACT

A case is described of a left-handed patient with a circumscribed right-sided posterior brain lesion, who presented with a neuro-psychological syndrome of Wernicke's aphasia, ideomotor and ideatory apraxia. The aphasia and ideomotor apraxia cleared within 10 days, while ideatory apraxia persisted. Ideatory apraxia therefore was not dependent on the language disorder, nor was it related

to ideomotor apraxia. On the basis of various neuropsychological examinations, the nature of the apraxic movement disorder in this case is discussed. To our knowledge, this is the first case of ideatory apraxia with right-sided brain damage described in the literature. A particular feature of this patient is that obviously language and the motor functions underlying performance in tests for ideomotor apraxia had a bilateral hemispheric representation whereas a unilateral lesion was sufficient to bring about persistent ideatory apraxia.

REFERENCES

- ALAJOUANINE, T., and LHERMITTE, F. (1963) *Some problems concerning the agnosias, apraxias, and aphasia*, in Problems of Dynamic Neurology, ed. by L. Halpern, Jerusalem Post Press, Jerusalem.
- AJURIAGUERRA, J. DE., HÉCAEN, H., and ANGELERGUES, R. (1960) *Les apraxies. Variétés cliniques et latéralisation lésionnelle*, Rev. Neurol., 102, 566-594.
- , and TISSOT, F. (1969) *The apraxias*, in Handbook of Clinical Neurology, Vol. 4, Disorders of Speech, Perception and Symbolic Behavior, ed. by P. J. Vinken and G. W. Bruyn, Elsevier, New York.
- DENNY-BROWN, D. (1968) *The nature of apraxia*, J. Nerv. Ment. Dis., 126, 9-32.
- DE RENZI, E., PIECZURO, A., and VIGNOLO, A. (1968) *Ideational apraxia: a quantitative study*, Neuropsychologia, 6, 41-52.
- GESCHWIND, N. (1965) *Disconnexion syndromes in animals and man*, Brain., 88, 585-644.
- , QUADFASEL, F. A., and SEGARRA, J. M. (1968) *Isolation of the speech area*, Neuropsychologia, 6, 327-340.
- GOODGLASS, H., and KAPLAN, E. (1972) *The Assessment of Aphasia and Related Disorders*, Lea and Febiger, Philadelphia.
- HÉCAEN, H. (1960) *Les apraxies*, Rev. Neurol., 102, 541-550.
- (1968) *Suggestions for a typology of the apraxias*, in The Reach of Mind, ed. by M. L. Simmel, Springer, New York.
- , and ALBERT, M. L. (1978) *Human Neuropsychology*, Wiley, New York.
- HEILMAN, K. M. (1973) *Ideational apraxia — a re-definition*, Brain, 96, 861-864.
- HUBER, W. (1978) *Linguistic and nonlinguistic processing of narratives in aphasia*, paper presented at the 16th Annual Meeting of the Aphasia Academy in Chicago.
- KIMURA, D. S., and ARCHIBALD, Y. (1974) *Motor functions of the left hemisphere*, Brain, 97, 337-350.
- LEHMKUHL, G., and POECK, K. Cortex, in press.
- LIEPMANN, H. (1905) *Über Störungen des Handelns bei Gehirnkranke*, Karger, Berlin.
- (1908) *Drei Aufsätze aus dem Apraxiegebiet*, Karger, Berlin.
- MORLAAS, J. (1928) *Contribution à l'étude de l'apraxie*, Legrand, Paris.
- NATHAN, P. W. (1947) *Facial apraxia and apraxic dysarthria*, Brain, 70, 449-478.
- NIELSEN, J. M. (1946) *Agnosia, Apraxia, Aphasia. Their Value in Cerebral Localisation*, Hafner, New York.
- , and IVES, E. (1936) *The motor nature of apraxia*, Bull. Los Angel. Neurol. Soc., 1, 133-140.
- ORGASS, B. (1976a) *Eine Revision des Token-Tests. I. Vereinfachung der Auswertung, Itemanalyse und Einführung einer Alterskorrektur*, Diagnostica, 22, 70-87.
- (1976b) *Eine Revision des Token-Tests. II. Validitätsnachweis, Normierung und Standardisierung*, Diagnostica, 22, 141-156.
- PICK, A. (1905) *Studien über motorische Apraxie und ihr nahestehende Erscheinungen, ihre Bedeutung in der Symptomatologie psychopathologischer Symptomenkomplexe*, Deuticke, Leipzig.
- POECK, K. (1976) *Review paper on apraxia*, EBBS meeting London.
- (1978) *The nature of ideatory apraxia*, paper read at the meeting of the research group on aphasia of the WNF, Iowa City, USA.

POECK, K., and LEHMKUHL G. (1980) *Das Syndrom der ideatorischen Apraxie und seine Lokalisation*. *Nervenarzt*, 51, 217-225

ZANGWILL, O. L. (1960) *Le problème de l'apraxie idéatoire*, *Rev. Neurol.*, 102, 595-603.

Prof. K. Poeck, Abteilung Neurologie, Goethestrasse 27-29, D-51 Aachen, West-Germany.