

M. Shimodozono
K. Kawahira
N. Tanaka

Functioning heterotopic grey matter? Increased blood flow with voluntary movement and sensory stimulation

Received: 24 November 1993
Accepted: 23 March 1994

M. Shimodozono (✉) · K. Kawahira ·
N. Tanaka
Department of Rehabilitation
and Physical Medicine,
Faculty of Medicine,
Kagoshima University,
1208-1, Usuki-cho, Kagoshima 890, Japan

Abstract A 66-year-old woman with a right hemiplegia due to cerebral haemorrhage was found to have heterotopic grey matter in the left frontal and right frontal and parietal lobes. She had no neurological disturbance prior to the haemorrhage. Regional cerebral blood flow (rCBF) was measured by xenon-CT (Xe-CT) in the zones of heterotopic grey matter during voluntary movement and sensory stimulation of her left limbs. During voluntary movement, rCBF increased markedly in

the heterotopic grey matter of the frontal lobes and the overlying cortex. During sensory stimulation, rCBF increased in the right parietal heterotopic grey matter and the overlying cortex. This strongly suggests that the heterotopic grey matter is functional.

Key words Heterotopic grey matter · Xenon computed tomography · Regional cerebral blood flow

Introduction

Heterotopic grey matter is a rare developmental anomaly caused by disturbed migration of neuroblasts during fetal life [1–4] and usually associated with epileptic seizures and mental retardation [2, 4–7]. CT [2, 3, 8, 9], MRI [2, 6–11], positron emission tomography (PET) [12, 13], and single photon emission computed tomography (SPECT) [1, 14] have facilitated the diagnosis of heterotopic grey matter, making it detectable by means other than autopsy [4, 6–9, 11, 12, 14].

Heterotopic grey matter has never been reported to have any neuronal function other than as an epileptic focus. However, recent advances in measurement of regional cerebral blood flow (rCBF) and cerebral metabolism have enabled us to assess localised function and functional changes of the brain. We saw a patient with cerebral haemorrhage with bilateral heterotopic grey matter. No neurological deficits or seizures were present before the haemorrhage. To establish the function of the heterotopic grey matter, we studied changes in their rCBF during voluntary movement and sensory stimulation of unilateral extremities using xenon-CT (Xe-CT) [13, 15].

Case report

A 66-year-old woman was admitted for rehabilitation following a right hemiplegia caused by a hypertensive cerebral haemorrhage 4 months earlier. She had no neurological history and had led an active life until the stroke. On admission, she was alert and showed no dysphasia, visuospatial agnosia, or behavioural disturbances; she had a right hemiplegia with spasticity, synergia, brisk tendon reflexes, pathological reflexes, and moderate right sensory disturbance. The Mini-Mental State examination score was 28/30 points. The EEG showed no abnormality, even with photostimulation. CT showed a low density area in the left thalamus, extending to the corona radiata, compatible with the recent cerebral haemorrhage. Deformities of the frontal horns and three faint subcortical nodules were observed without contrast enhancement. MRI clearly demonstrated nodules in the left and right frontal lobes, and another in the right parietal lobe, isointense with the overlying cortex (Fig. 1). These were thought to represent heterotopic grey matter, because they were isodense on CT and isointense on MRI with the overlying cortex and showed no contrast enhancement.

The rCBF was measured by Xe-CT [13, 15] using high-sensitivity collimation and a computer to calculate local Xe tissue saturation curves according to Kety's formula [16]. The patient inhaled 30% Xe gas from a closed chamber for 4 min and then breathed room air for 5 min into a trap chamber. Colour-coded images of rCBF were displayed and quantitation of rCBF of the heterotopic

Fig. 1 **a** Axial proton density-weighted (TR 2000 TE 30 ms) and **b** sagittal T1-weighted (TR 500 TE 20 ms) images showing the heterotopic grey matter in both frontal lobes and the right parietal lobe (*arrows*), and deformity of the ventricles. The heterotopic grey matter is isointense with the overlying cortex

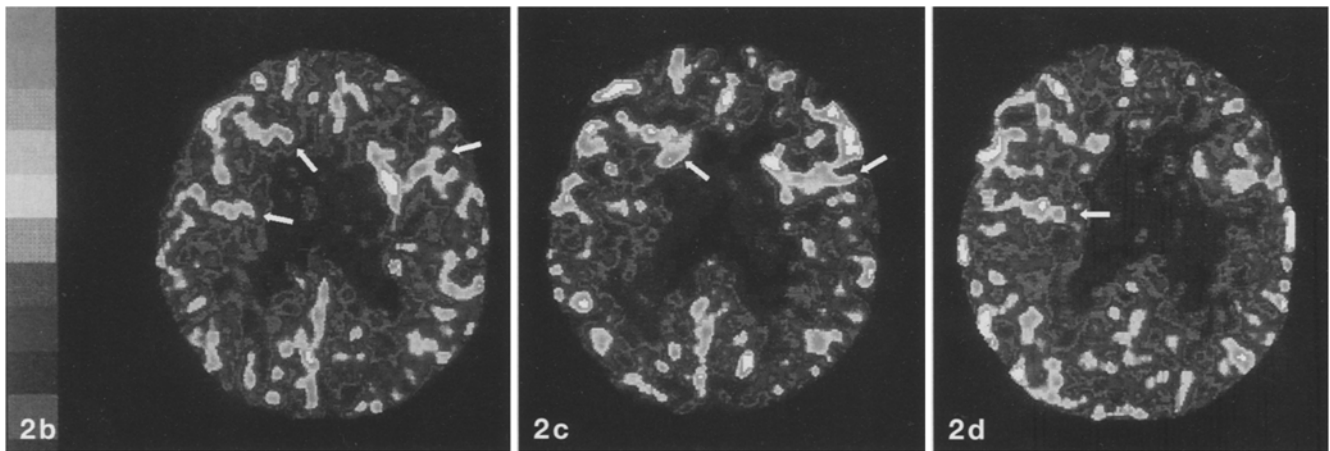
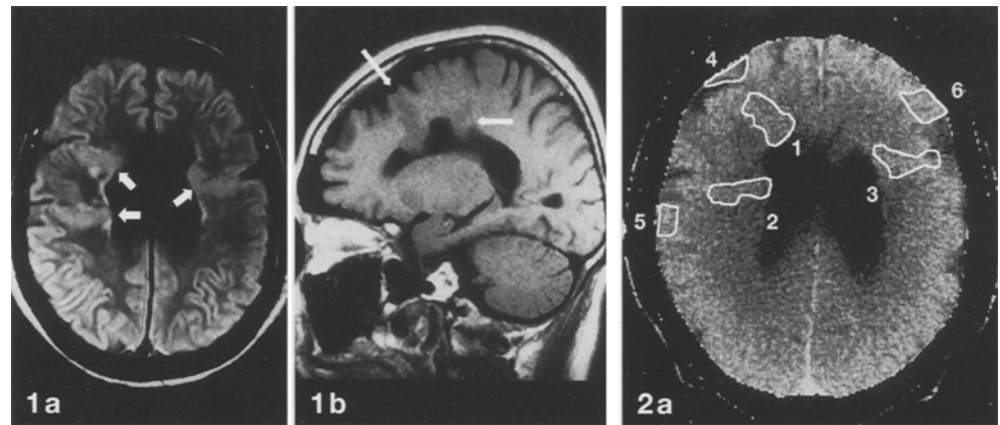


Fig. 2 **a** CT showing the regions of interest in the zones of heterotopic grey matters (1–3) and overlying cortex (4–6). **b–d** Xenon-CT: **b** awake, resting, eyes closed; **c** during voluntary movement of the left limbs; and **d** during sensory stimulation of the left limbs. At rest the areas of heterotopic grey matter (*arrows*) showed the same regional cerebral blood flow (rCBF) as the overlying cortex. Voluntary movement induced an increase in rCBF in both frontal areas of heterotopia (*arrows*) and the overlying cortex. Sensory stimulation induced an increase in the rCBF of the right parietal heterotopic grey matter (*arrow*) and overlying cortex

Table 1 Regional cerebral blood flow (ml/100 g tissue/min) of each region of interest (Fig. 2a) under three conditions (HGM heterotopic grey matter)

	Rest	Voluntary movement of left limbs	Sensory stimulation of left limbs
Right frontal HGM	31.3	37.8	32.7
Right parietal HGM	28.4	26.7	39.1
Left frontal HGM	34.6	42.4	29.3
Right frontal cortex	11.9	42.7	31.1
Right parietal cortex	26.1	18.7	45.8
Left frontal cortex	29.3	43.4	29.3

grey matter and the cerebral cortex was performed by outlining the area on a display console (Fig. 2a). We selected two CT planes, showing the heterotopic grey matter, to allow simultaneous study of rCBF in all three regions. rCBF was measured in the supine position under three different conditions: awake, resting, with eyes closed, as a control; rhythmic voluntary flexion and extension of the left wrist and ankle for 9 min; and continuous stimulation of the left forearm and calf with soft nylon brushes for 9 min.

Figure 2b shows that, at rest, the rCBF of the three areas of heterotopic grey matter was nearly the same as that of the overlying cortex. During voluntary movement of the left limbs, the rCBF increased greatly in the heterotopic foci in the frontal lobes, as well as in the overlying cortex (Fig. 2c, Table 1). The rCBF of the right parietal heterotopic grey matter, and of adjacent cortex, was unchanged. During sensory stimulation of the left limbs, the rCBF increased in the right parietal heterotopic grey matter and overlying cortex (Fig. 2d, Table 1). The rCBF of the frontal heterotopic areas and the adjacent left frontal cortex was unchanged.

Discussion

Heterotopic grey matter consists of anomalous collections of nerve cells in subcortical white matter whose radial migration from the periventricular germinal zones was arrested [17]. Patients with heterotopic grey matter usually have micropolygyria and pachygyria, in-

tractable epileptic seizures, an abnormal EEG and mental retardation [2, 3, 5–9]. Barkovich et al. [4] found five patients with heterotopic grey matter in more than 20,000 MRI studies; and all of the affected patients had severe epileptic seizures and developmental delay. The four patients reported by Michael and Mattar [1] also had intractable seizures, mental retardation and developmental cortical malformations. Histologically, these ectopic nodules consist of abnormally large neurons and increased numbers of astrocytes and oligodendrocytes, with minimal architectonic stratification. Abnormally located neurons in heterotopic grey matter have aberrant axonal and dendritic connections with the surrounding brain tissue and these connections, and gliosis, are thought to cause the associated epileptic seizures [4, 5, 11, 18–21].

In this case, heterotopic grey matter was found incidentally on CT. The patient had normal psychomotor

development and no epileptic seizures or EEG abnormality. The rCBF of the heterotopic grey matter, and the adjacent cortex, was significantly increased by contralateral voluntary movements or sensory stimulation. A reactive increase in rCBF has been considered to imply neuronal activation of the corresponding area of the brain (blood flow-metabolism coupling). Therefore, our findings suggest that the heterotopic grey matter in this patient could play a functional role in voluntary movement and sensory perception. However, it is unknown whether the changes in rCBF reflect specific or nonspecific neuronal activation of the heterotopic grey matter as motor or premotor and sensory perceptive centres. More detailed examinations using EEG topography and PET with higher spatial resolution may help to define the neuronal function of heterotopic grey matter.

References

1. Michael MA, Matter AG (1978) Malformation of the cerebral cortex with heterotopia of the gray matter. *J Comput Assist Tomogr* 2: 291–296
2. Hager BC, Dyme IZ, Guertin SR, Tyler RJ, Tryciecky EW, Fratkin JD (1991) Linear nevus sebaceous syndrome: megalencephaly and heterotopic gray matter. *Pediatr Neurol* 7: 45–49
3. Zimmerman RA, Bilaniuk LT, Grossman RI (1983) Computed tomography in migratory disorders of human brain development. *Neuroradiology* 25: 257–263
4. Barkovich AJ, Jackson DE, Boyer RS (1989) Band heterotopias: a newly recognized neuronal migration anomaly. *Radiology* 171: 455–458
5. Layton DD (1967) Heterotopic cerebral gray matter as an epileptogenic focus. *J Neuropathol Exp Neurol* 121: 244–249
6. Zisch R, Artmann W (1991) MRI in the diagnosis of heterotopic gray matter; report of three cases first discovered in adulthood. *Neuroradiology* 33: 527–528
7. Arena A, Scuderi D (1990) Heterotopic gray matter: report of a case. *Ital J Neurol Sci* 11: 301–302
8. Mineura K, Fushimi S, Sugawara T, Kowada M (1990) Computed tomography (CT) and magnetic resonance (MR) imaging of heterotopic gray matter presenting with late-onset seizures. *Comput Med Imaging Graph* 14: 217–220
9. Dunn V, Mock T, Bell WE, Smith W (1986) Detection of heterotopic gray matter in children by magnetic resonance imaging. *Magn Reson Imaging* 4: 33–39
10. Deeb ZL, Rothfus WE, Maroon JC (1985) MR imaging of heterotopic gray matter. *J Comput Assist Tomogr* 9: 1140–1141
11. Smith AS, Weinstein MA, Quencer RM, et al (1988) Association of heterotopic gray matter with seizures: MR imaging. *Radiology* 168: 195–198
12. Bairamian D, Chiro GD, Theodore WH, Holmes MD, Dorwart RH, Larson SM (1985) MR imaging and positron emission tomography of cortical heterotopia. *J Comput Assist Tomogr* 9: 1137–1139
13. Meyer JS, Shinohara T, Imai A, et al (1988) Imaging local cerebral blood flow by xenon-enhanced computed tomography: technical optimization procedures. *Neuroradiology* 30: 283–292
14. Henkes H, Hosten N, Cordes M, Neumann K, Hansen ML (1991) Increased rCBF in gray matter heterotopias detected by SPECT using ^{99m}Tc hexamethyl-propylenamine oxime. *Neuroradiology* 33: 310–312
15. Gur D, Yonas H, Good WF (1989) Local cerebral blood flow by xenon-enhanced CT: current status, potential improvements, and future directions. *Cerebrovasc Brain Metab Rev* 1: 68–86
16. Kety S (1951) The theory and applications of the exchange of inert gas at the lungs and tissues. *Pharmacol Rev* 3: 1–41
17. Volpe JJ (1977) Normal and abnormal human brain development. *Clin Perinatol* 4: 3–30
18. Taylor DC, Falconer MA, Bruton CJ, Corsellis JAN (1971) Focal dysplasia of the cerebral cortex in epilepsy. *J Neurol Neurosurg Psychiatry* 34: 369–387
19. Kernohan JW (1930) Cortical anomalies, ventricular heterotopias and occlusion of the aqueduct of Sylvius. *Arch Neurol Psychiatry* 23: 460–480
20. Meencke HJ, Janz D (1985) The significance of microdysgenesis in primary generalized epilepsy: an answer to the considerations of Lyon and Gastaut. *Epilepsia* 26: 368–371
21. Friede RL (1975) *Developmental neuropathology*. Springer, New York Berlin Heidelberg, pp 1–23, 197–339