

## Isolated Cortical Venous Thrombosis— Discrepancy Between Clinical Features and Neuroradiologic Findings

### A Case Report

Yeu-Jhy Chang, M.D.  
Chin-Chang Huang, M.D.  
and Yau-Yau Wai, M.D.\*

TAIPEI, TAIWAN

---

#### ABSTRACT

Isolated cortical venous thrombosis (CVT) is rare, and the discrepancy between clinical features and neuroradiologic findings has not been adequately emphasized. A thirty-one-year-old woman presented with focal seizures and occasionally secondary generalization. There was no focal neurologic deficit except for Todd's paralysis. Electroencephalography showed intermittent theta waves at the left frontoparietal area. Brain computed tomography (CT) and magnetic resonance imaging (MRI) disclosed a large lesion in the left frontoparietal area. An extensive occlusion of the superior cerebral veins of the left hemisphere with a patency of the dural sinuses was noted in the cerebral angiography. Eight months later, the CT hypodense lesion disappeared. Her neurologic status was stationary, but the seizures, mostly focal, still occurred occasionally. In this report, the authors emphasize the dissociation between minor clinical features and larger CT and MRI lesions in isolated CVT.

---

From the Departments of Neurology and \*Radiology, Chang Gung Memorial Hospital, Taipei, Taiwan.

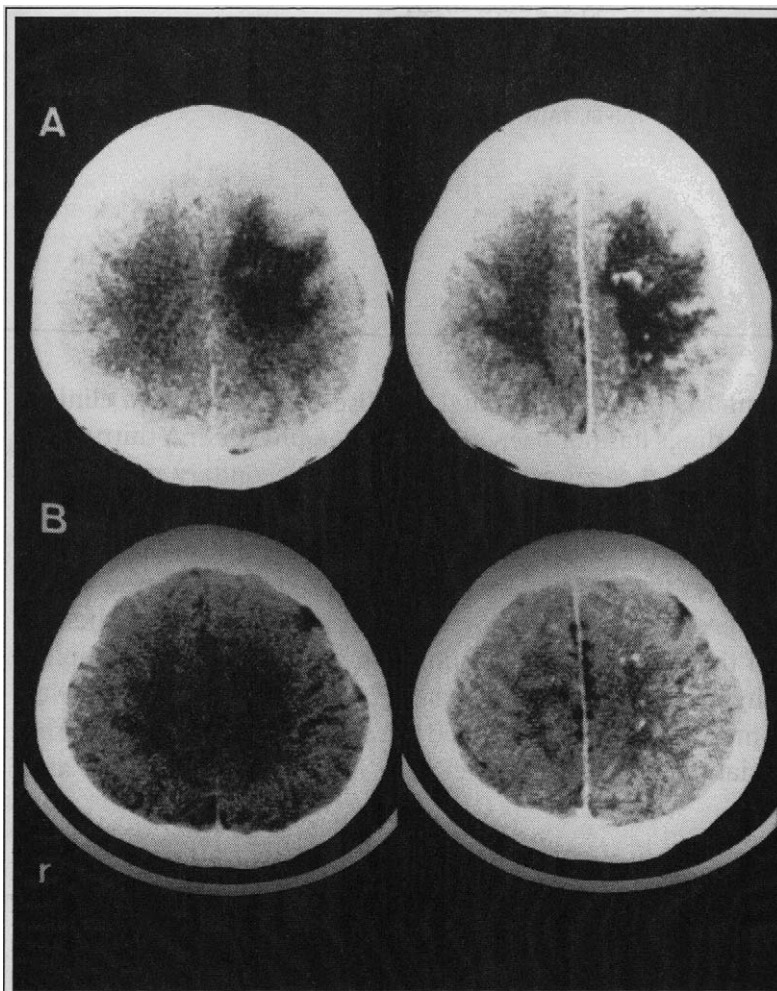
©1995 Westminster Publications, Inc., 708 Glen Cove Avenue, Glen Head, NY 11545, U.S.A.

*Introduction*

Cerebral venous thrombosis may present with a wide spectrum of clinical features including headache, papilledema, seizures, focal deficits, hemorrhagic infarction, coma, and even death.<sup>1,2</sup> If cortical veins are involved, focal neurologic deficits and seizures are common. Isolated cortical venous thrombosis (CVT) without sinus involvement is rare.<sup>1,3,4</sup> Its angiographic findings have been shown, but computed tomography (CT) and magnetic resonance imaging (MRI) studies have been seen only in animal studies.<sup>5,7</sup> Recently, we encountered a patient with isolated CVT with a large CT/MRI lesion and minor clinical features. We describe the clinical manifestations and neuroradiologic findings and discuss possible mechanisms.

Case Report

A thirty-one-year-old woman was rather healthy until February 16, 1992, when she developed sudden onset of generalized tonic-clonic seizures while playing cards. The family and birth histories were unremarkable. There was no history of major systemic diseases, infection, drug abuse, seizure, or of oral contraceptive use. She had had a traffic accident with transient loss of consciousness but without any sequelae in 1988. Focal motor seizures with twitching of the right upper limb that usually lasted for about two minutes occurred and might be followed by secondary generalization. The postictal confusion persisted for one and a half hours. On March 8, 1992, status epilepticus developed. Though a combination of phenytoin, carbamazepine, and valproic acid was

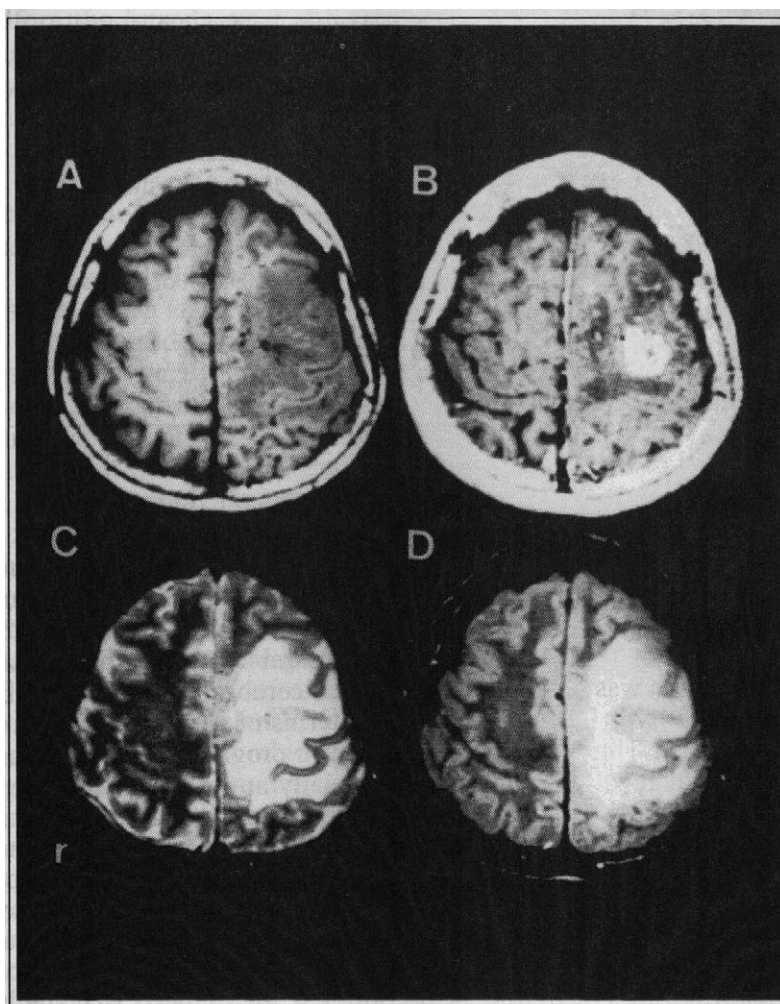


**Figure 1.** Brain CT showed a large hypodense lesion over the subcortical white matter of the left frontoparietal lobes, with compression of the left lateral ventricle. Dot and wormlike enhancements were seen in the left parietal area after contrast medium injection (A). Eight months later, the low-density lesion had disappeared, although enhancement was still present (B).

used, continuous focal motor seizures over the right hand still occurred with sleep deprivation, emotional stress, or tiredness. On examination, she was alert and her intellectual function was normal. The cranial nerves, motor, sensory, cerebellar, and sphincter functions were intact. No papilledema was noted, but Todd's paralysis of the right limbs was observed.

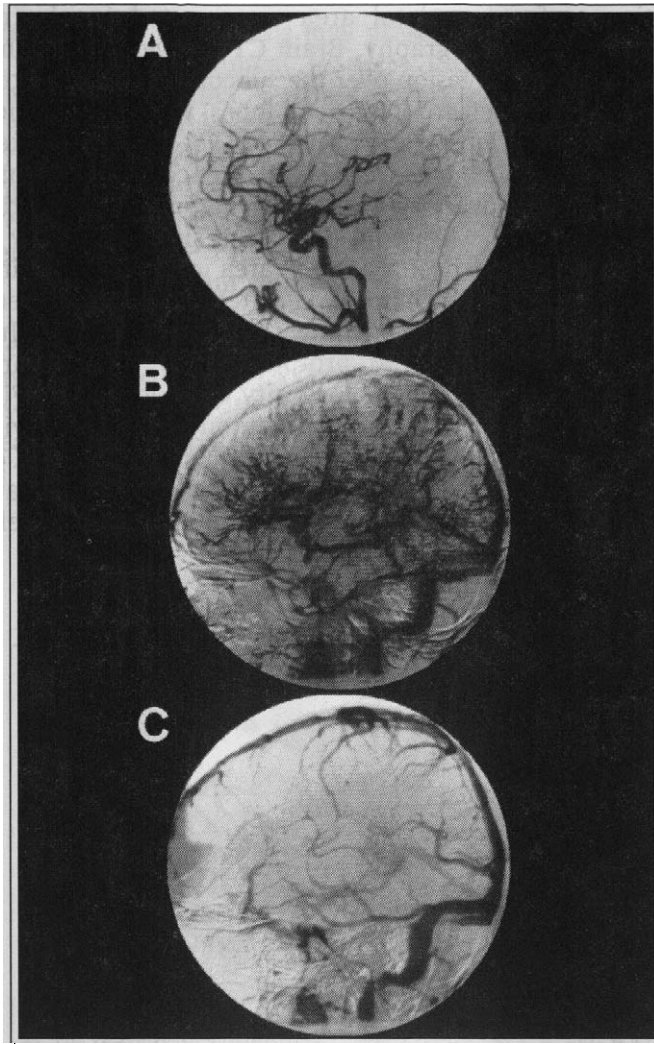
Laboratory examinations including liver functions, electrolytes, thyroid function tests, erythrocyte sedimentation rate, antinuclear antibody, complements of C3 and C4, venereal disease research laboratory, alpha-fetoprotein, carcinoembryonic antigen, human chorionic gonadotropin, and antibodies to DNA, mitochondria, and smooth muscle showed no definite abnormalities except for positive surface antigen of hepatitis B. The electrocardiogram appeared normal.

Mild intermittent theta waves over the left frontoparietal area were noted in electroencephalography. Brain CT showed a large hypodense lesion over the subcortical white matter of the left frontoparietal lobes, with compression of the left lateral ventricle. Dot and wormlike enhancements were found after contrast medium injection at the same area (Figure 1A). MRI studies demonstrated a decreased signal intensity over the left frontoparietal area in  $T_1$ -weighted image and an enhancement after gadolinium injection over the left frontal area (Figure 2A, B). In  $T_2$ -weighted and proton density images, an increased signal intensity was observed (Figure 2C, D). Cerebral angiography showed nonvisualization of the left superior cerebral veins. A compensatory engorgement of collateral circulations as corkscrew vessels was found from the left in-



**Figure 2.**

Brain MRI showed (A) a decreased signal intensity over the left frontoparietal areas in  $T_1$ -weighted images (TR/TE = 467 ms/20 ms). (B) After gadolinium injection, an enhancement was found at the left frontal area (TR/TE = 517 ms/20 ms). An increased signal intensity was noted over the same regions in (C)  $T_2$ -weighted images (TR/TE = 2000 ms/80 ms) and (D) proton density image (TR/TE = 2000 ms/30 ms).



**Figure 3.** Cerebral angiography showed a normal opacification of the main arteries from the left internal carotid artery injection of contrast media (A). Numerous collateral circulations as corkscrew vessels were drained into internal cerebral and basal veins. Though appearing late and less opacified, the dural sinuses were detected. The superior cerebral veins were not seen (B). However, sinus and venous systems were well demonstrated by right internal carotid artery injection of contrast medium (C).

ternal carotid artery injection (Figure 3A, B). The dural sinuses and right cerebral venous systems were patent (Figure 3C). There was neither anticoagulant nor surgical intervention.

Eight months later, her clinical condition was stationary and CT scan showed that the hypodense lesion had disappeared (Figure 1B). The condition was stationary, but occasional focal seizure still bothered her.

### Discussion

The diagnosis of cerebral venous thrombosis became more common with widespread use of CT,

MRI, and cerebral angiography.<sup>8</sup> Variations of clinical presentations, numerous causes, and unpredictable outcome remain a challenge.<sup>1,9</sup> The clinical pictures of cerebral venous thrombosis are similar to those of cerebral arterial thrombosis. Nevertheless, in terms of survival, it is relatively benign and better in prognosis.<sup>4,10</sup> The favorable outcome is especially apparent in isolated CVT, owing probably to a better collateral circulation. Although a large lesion was present over the left hemisphere in our patient, the clinical symptoms were minimal. The dissociation between imaging studies and clinical pictures may be a characteristic feature of isolated CVT. The resolution of this large lesion on CT scans suggests that the hypo-

dense lesion represented edema due to venous congestion rather than infarction.<sup>11,12</sup> To our knowledge, only few patients with this condition have been described, and their clinical features and CT/MRI findings are still lacking.<sup>1,5,6</sup> Only 2 of 110 cases with cerebral venous thrombosis in Ameri's series had isolated CVT.<sup>1</sup> In the series of Boussier et al<sup>3</sup> and Srinivasan et al,<sup>4</sup> there was no patient with isolated CVT.

In spite of numerous causes of the cerebral venous thrombosis reported, many cases still remain unknown, with an incidence up to 35%.<sup>1,8,9</sup> In young women, cerebral venous thrombosis may occur in puerperium or pregnancy or with oral contraceptive use.<sup>3,4,13</sup> Our patient was not pregnant and was not taking contraceptives. Other possible etiologies may include congenital vascular agenesis of the left superior cerebral veins, head injury, and some hyperviscosity conditions, such as dehydration and other unknown hypercoagulable states.

Before the introduction of angiography and CT, cerebral venous thrombosis was diagnosed mainly on the basis of autopsy, and therefore, it was thought to be lethal. In fact, the disease may be underdiagnosed owing to mild clinical symptoms, such as transient ischemic attacks, migraine-like phenomenon, headache, vomiting, and pseudotumor cerebri.<sup>3,14</sup> Headache is frequent, particularly if there is involvement of the dural sinus, which leads to intracranial hypertension.<sup>1</sup> Our case did not have headache but had seizures, which were probably due mainly to the involvement of cortical veins and rarely or not at all to involvement of sinuses.<sup>1</sup> Because of the high sensitivity of MRI and the invasiveness of angiography, MRI study may be helpful for the diagnosis of cerebral venous thrombosis.<sup>1,15</sup>

The treatment of CVT is still controversial owing to the variability in its natural course. Medications with anticonvulsants and antibiotics, methods of reducing intracranial pressure, and/or use of anticoagulants are recommended. However, the use of anticoagulants remains controversial, owing to the risk of rebleeding after a hemorrhagic infarct.<sup>16,17</sup> Nonetheless, the risk of increasing intracranial hemorrhage has probably been overestimated.<sup>3,8,18,19</sup> Despite the use of anticoagulants having no obvious complication, a large series of prospective studies is needed. Because the clinical symptoms and signs were so mild in our patient, an anticoagulant was not prescribed and the condition was stationary.

### *Conclusion*

Our patient provided a natural course with spontaneous remission in the CT scan of isolated CVT. The discrepancy between clinical features and neuroradiologic findings may be characteristic for isolated CVT. Its outcome is better than that in arterial occlusion. Angiography for diagnosis of isolated CVT is still important, although the application of MRI may be more popular in the future.

Chin-Chang Huang, M.D.  
Department of Neurology  
Chang Gung Memorial Hospital  
199, Tung Hwa North Road  
Taipei, Taiwan

### References

1. Ameri A, Bousser MG: Cerebral venous thrombosis. *Neurologic Clinics* 10:87-111, 1992.
2. Kalbag RM: Cerebral venous thrombosis. In: *The Cerebral Venous System and Its Disorders*, ed. by Kapp JP, Schmidek HH. Orlando, Florida: Grune & Stratton, 1984, pp 505-536.
3. Bousser MG, Chiras J, Bories J, et al: Cerebral venous thrombosis—a review of 38 cases. *Stroke* 16:199-213, 1985.
4. Srinivasan K: Cerebral venous and arterial thrombosis in pregnancy and puerperium—a study of 135 patients. *Angiology* 34:731-746, 1983.
5. Gabrielsen TO, Seeger JF, Knake JE, et al: Radiology of cerebral vein occlusion without dural sinus occlusion. *Radiology* 140:403-408, 1981.
6. Yasargil MG, Damur M: Thrombosis of the cerebral veins and dural sinuses. In: *Radiology of the Skull and Brain*, ed. by Newton TH, Potts DG. St. Louis: Mosby, 1974, 2:2375-2400.
7. Secrist RD, Traynelis V, Schochet SS Jr: MR imaging of acute cortical venous infarction: Preliminary experience with an animal model. *Magnetic Resonance Imaging* 7:149-153, 1989.
8. Thron A, Wesse K, Linden D, et al: Superior sagittal sinus thrombosis: Neuroradiological evaluation and clinical findings. *J Neurol* 233:283-288, 1986.
9. Lefkowitz D: Cortical thrombophlebitis and sinovenous disease. In: *Handbook of Clinical Neurology—Vascular Diseases Part II*, ed. by Vinken PJ, Bruyn GW, Klawans HL, et al. Amsterdam: Elsevier Science Publishers, 1989, 54:395-423.
10. Nain-Ur-Rahman, Al-Tahan AR: Computed tomographic evidence of an extensive thrombosis and infarction of the deep venous system. *Stroke* 24:744-746, 1993.
11. Haley EC Jr, Brashear HR, Barth JT, et al: Deep cerebral venous thrombosis. *Arch Neurol* 46:337-340, 1989.
12. Brown JIM, Coyne TJ, Hurlbert RJ, et al: Deep cerebral venous system thrombosis: Case report. *Neurosurgery* 55:911-913, 1993.
13. Estanol B, Rodriguez A, Conte G, et al: Intracranial venous thrombosis in young women. *Stroke* 10:680-684, 1979.
14. Newman DS, Levine SR, Curtis VL, et al: Migraine-like visual phenomenon associated with cerebral venous thrombosis. *Headache* 29:82-85, 1989.
15. Ramadan NM, Deveshwar R, Levine SR: Magnetic resonance and clinical cerebrovascular disease—an update. *Stroke* 24:13-18, 1989.
16. Barnett HJM, Hyland HH: Non-infective intracranial venous thrombosis. *Brain* 76:36-49, 1953.
17. Buchanan DS, Brazinsky JH: Dural sinus and cerebral venous thrombosis. Incidence in young women receiving oral contraceptives. *Arch Neurol* 22:440-444, 1970.
18. Fairburn B: Intracranial venous thrombosis complicating oral contraception: Treatment by anticoagulant drugs. *Br Med J* 2:647, 1973.
19. Levine SR, Twyman RE, Gilman S: The role of anticoagulation in cavernous sinus thrombosis. *Neurology* 38:517-522, 1988.