

EEP 93560

Short communication

Intraoperative recording of parietal SEP can miss hemodynamic infarction during carotid endarterectomy: a case study

W.F. Haupt^{a,*}, H. Erasmi-Körber^b and H. Lanfermann^c

Departments of ^a Neurology, ^b Surgery and ^c Radiology, University of Cologne, Joseph-Stelzmann-Str. 9, D-50924 Cologne (Germany)

(Accepted for publication: 14 October 1993)

Summary Serial recording of median nerve somatosensory evoked potentials (SEPs) provides reliable intraoperative information on critical lowering of brain perfusion which compares favorably with other monitoring methods. However, single-channel parietal SEP recording may not detect hemodynamic cerebral infarctions affecting the pre-rolandic area. Following left carotid endarterectomy for high-grade symptomatic stenosis in a 66-year-old male, predominantly motor hemiparesis and aphasia were detected which were largely reversible. Pre- and intraoperative SEPs were normal. Postoperative SEPs showed significant interhemispheric amplitude differences. Postoperative CT examinations demonstrated hemodynamic watershed-type infarctions. This rare complication of carotid endarterectomy was not detected by intraoperative single-channel parietal SEP monitoring.

Key words: Carotid endarterectomy; Intraoperative monitoring; Monitoring by somatosensory evoked potentials (SEPs); Hemodynamic cerebral infarction

Somatosensory evoked potential (SEP) monitoring is considered a safe and reliable method to detect critical lowering of brain perfusion during carotid endarterectomy (Markand et al. 1984; Haupt et al. 1985; Amanitini et al. 1992; Haupt and Horsch 1992). Comparison of this method with EEG (Harris et al. 1967; Chiappa et al. 1979; Mola et al. 1986) and examinations of regional cerebral blood flow (RCBF) (Trojaborg and Boysen 1973; Sundt et al. 1981) as well as carotid artery stump pressure (Gigli et al. 1987) has demonstrated the high sensitivity and reliability of SEP monitoring. The majority of intraoperative complications are due to emboli arising from the carotid artery, the ensuing infarctions in the supply region of the middle cerebral artery are easily detected by SEP monitoring. However, critical lowering of systemic blood pressure or insufficient intracranial arterial collateralization can also produce watershed-type perfusion defects in the border regions between the middle and anterior/posterior cerebral artery supply areas (Ringelstein et al. 1985). Since these areas are remote from the primary sensory cortex, single-channel SEP monitoring which records only parietal cortical activity may not detect impaired brain function as demonstrated in the following case report.

Methods

Median nerve SEPs were recorded by stimulation at the wrist with 0.2 msec rectangular electrical stimuli with an intensity above the motor threshold. The stimulus frequency was set at 3 Hz. The preoperative recordings were obtained for both median nerves using

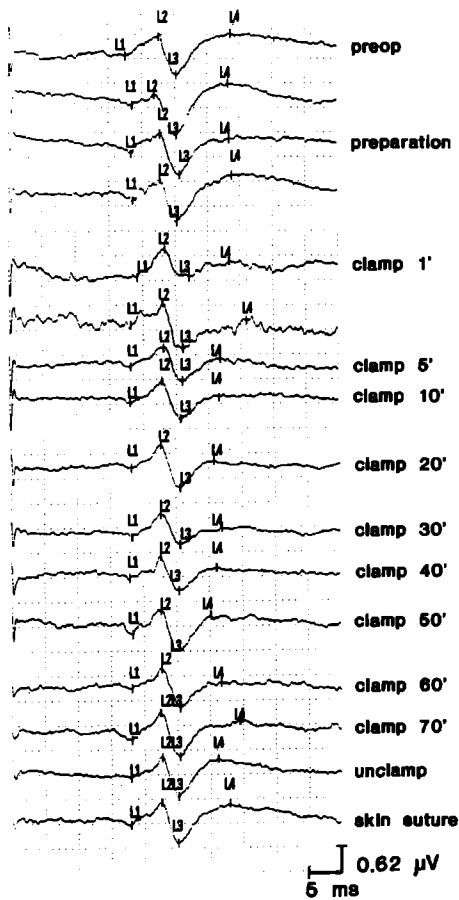
single-channel registration with steel needles placed over the contralateral parietal region at C3' and C4' (2 cm posterior to C3 and C4) referred to F3 and F4, respectively. Filter bandpass was 20–1000 Hz, bin width 50 μ sec, 256 responses were averaged for each registration. The intraoperative recordings were performed from the right median nerve only at intervals of 2–10 min according to the stages of the operation. Postoperative recordings were obtained for both median nerves in the same recording conditions. Absolute N20 latencies and interhemispheric differences of N20 latencies were compared to laboratory standards and considered abnormal when they exceeded 2.5 S.D. of the normal values (absolute N20 mean latency: 19.4 msec, upper limit of normal 23.1 msec; upper limit of normal interhemispheric difference: 0.95 msec). Amplitude of the N20/P25 deflections was considered abnormal for interhemispheric difference over 50%. The intraoperative recordings were considered pathological when the N20/P25 amplitude was more than 50% lower than that of baseline preoperative recording.

Case report

A 66-year-old male had experienced intermittent impairment of vision for 10 years and clinically inapparent posterior wall cardiac infarction 7 years prior to operation. On May 14, 1992, he developed acute paresis of the right arm which lasted for 3 days. On carotid angiography, a 60% stenosis of the left internal carotid artery was detected. No signs of intracranial tandem stenosis were found. The preoperative cranial CT scan revealed no pathological findings. Following extensive preoperative examinations, left-sided carotid endarterectomy was performed. General anesthesia was performed using isoflurane 0.2 vol% during induction, propofol 300–400 mg/h,

* Corresponding author. Tel.: +221-478-4007; Fax: +221-478-4108.

Intraoperative SEP



H.H. EP 924/92

Fig. 1. Intraoperative SEP registration without significant latency or amplitude changes during endarterectomy.

and fentanyl 0.1 mg. Blood pressure varied between 130/80 and 150/90 mm Hg during the operation. During induction of anesthesia, however, blood pressure fell to between 100/60 and 80/50 mm Hg for about 20 min. Extensive endarterectomy was performed and the carotid artery was closed with a Dacron patch.

Preoperative SEP recordings were normal. Intraoperative monitoring throughout the operation did not show any significant latency or amplitude changes. SEP tracings immediately postoperatively were also normal (Fig. 1). The patient awoke after the operation with marked right-sided hemiparesis, aphasia and apraxia as well as right hemianopia. Due to aphasia, the absence of marked sensory deficit was not noted until improvement of communication allowed detailed sensory examination. CT scan 24 h after the operation demonstrated hypodensities in the border regions between the supply areas of the left anterior cerebral artery (ACA) and the middle cerebral artery (MCA) as well as between the MCA and the posterior cerebral artery (PCA) indicative of watershed-type hemodynamically induced infarction (Fig. 2). Postoperative SEP, performed on day 22, demonstrated a relative delay of right median nerve N20 with an interhemispheric difference of 1.8 msec and normal absolute latencies. Moreover, a 50% amplitude reduction of right median nerve N20 was detected. The right-sided paresis improved moderately well with a residual, predominantly proximal paresis of the right arm. Serial CT scans of the brain showed progressive demarcation of the hypodense lesions with small hyperdense lesions in the parieto-occipital area.

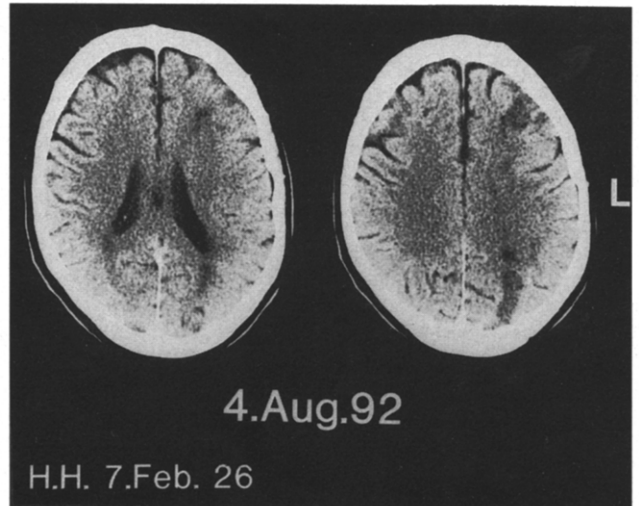


Fig. 2. Unenhanced cranial CT scans 24 h after left carotid endarterectomy, demonstrating left hemispheric watershed infarction.

The findings were attributed to infarctions in the ACA/MCA and MCA/PCA border supply areas with small hemorrhages secondary to watershed-type infarctions of hemodynamic origin (Fig. 3).

Discussion

Carotid endarterectomy must be considered a high-risk operation. Intraoperative monitoring of brain function is desirable to enhance patients' safety by detecting intraoperative complications as early as possible. Monitoring of conventional or spectral analyzed EEG has been performed for many years in a large series of patients; however, it does not invariably detect functional impairment of the brain although the entire cortex activity is monitored (Harris et al. 1967; Trojaborg and Boysen 1973; Chiappa et al. 1979; Sundt et al. 1981; Rampil et al. 1983).

In their series of 38 patients monitored by single-channel parietal SEP during carotid endarterectomy, Markand et al. (1984) found

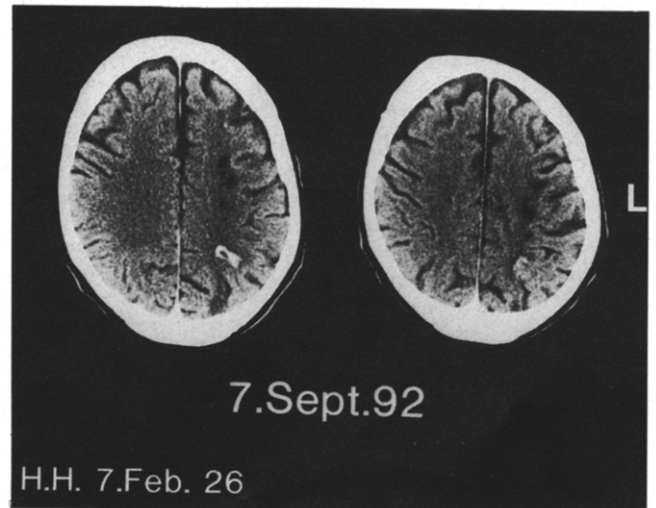


Fig. 3. Unenhanced cranial CT 4 weeks after endarterectomy, showing a better demarcated left hemispheric watershed infarction with small hemorrhage in the left postcentral gyrus.

that none of the patients with unaffected SEPs during operation suffered any neurological deficits during or after the operation. In their view, SEPs were superior to EEG monitoring as the latter is impaired by sensitivity to various systemic factors such as depth of anesthesia, blood pressure changes, and drug levels. Therefore, false-positive findings are more likely to occur with EEG than with SEP monitoring. In a series of 994 carotid endarterectomies with single-channel parietal SEP monitoring reported by our group (Haupt and Horsch 1992), only one case with postoperative deficit was not detected by intraoperative SEPs. The rate of false-negative findings amounted to 0.1%. Gigli et al. (1987) used 4-channel SEP monitoring (cervical, ipsi- and contralateral post-rolandic, and contralateral pre-rolandic registrations) in 40 endarterectomies and reported no postoperative deficits in patients with unchanged SEPs. Amantini et al. (1992) reported 368 monitored operations using 3-channel (cervical, post-rolandic, and pre-rolandic) SEP registration. They found 4 cases of flattened SEPs, all followed by postoperative neurological deficits. False-positive or false-negative results were not reported. Therefore, SEP monitoring appears to be a more reliable method than EEG in this application even though the SEP recordings reflect only a small portion of the total brain activity.

In their analysis of intraoperative strokes during endarterectomies followed by EEG, Krul et al. (1989) determined that embolic events were responsible for 27 of 34 cerebral infarctions, only 5 watershed-type hemodynamic strokes were found. Embolic occlusion of the trunk or branches of the middle cerebral artery is invariably detected by changes of the SEP generated by the somatosensory cortex. This case report suggests that rare cases of hemodynamic strokes, leading to watershed-type infarctions, may not be detected by single-channel parietal SEP monitoring. This circumstance does not seriously lessen the value of SEP monitoring as this situation is very rare. Considering the much higher rate of false-positive and false-negative findings when employing EEG monitoring, this disadvantage should be tolerable. Physicians using single-channel parietal SEP as a monitoring method during carotid endarterectomy should be aware of this potential problem. Multiple-channel SEP recording with post-rolandic as well as pre-rolandic SEP registrations, using an earlobe reference electrode, can improve the quality of intraoperative monitoring with only slightly higher technical expenditure.

References

- Amantini, A., Bartelli, M., De Scisciolo, G., Lombardi, M., Macucci, M., Rossi, R., Pratesi, C. and Pinto, F. Monitoring of somatosensory evoked potentials during carotid endarterectomy. *J. Neurol.*, 1992, 239: 241–247.
- Chiappa, K.H., Burke, S.R. and Young, R.R. Results of electroencephalographic monitoring during 367 carotid endarterectomies. *Stroke*, 1979, 10: 381–388.
- European Carotid Surgery Trialists' Collaborative Group. MRC European carotid surgery trial: interim results for symptomatic patients with severe (70–99%) or with mild (0–29%) carotid stenosis. *Lancet*, 1991, 337: 1235–1243.
- Gigli, G.L., Caramia, M., Marciani, M.G., Zarola, F., Lavaroni, F. and Rossini, P.M. Monitoring of subcortical and cortical somatosensory evoked potentials during carotid endarterectomy: comparison with stump pressure levels. *Electroenceph. clin. Neurophysiol.*, 1987, 68: 424–432.
- Harris, E.J., Brown, W.H., Pavy, R.N., Anderson, W.W. and Stone, D.W. Continuous electroencephalographic monitoring during carotid artery endarterectomy. *Surgery*, 1967, 62: 441–447.
- Haupt, W.F. and Horsch, S. Evoked potential monitoring in carotid surgery: a review of 994 cases. *Neurology (Minneapolis)*, 1992, 42: 835–838.
- Haupt, W.F., De Vleeschauwer, Ph. and Horsch, S. Veränderungen somatosensibler evozierter Potentiale während Karotis-Desobliteration. Diagnostische Bedeutung und mögliche Konsequenzen für die Therapie. *Z. EEG-EMG*, 1985, 16: 201–205.
- Krul, J.M.J., Van Gijn, J., Ackerstaff, R.G.A., Eikelboom, B.C., Theodirides, T. and Vermeulen, F.E.E. Site and pathogenesis of infarcts associated with carotid endarterectomy. *Stroke*, 1989, 20: 324–328.
- Markand, O.N., Dilley, R.S., Moorthy, S.S. and Warren, C. Monitoring of somatosensory evoked responses during carotid endarterectomy. *Arch. Neurol.*, 1984, 41: 375–378.
- Mola, M., Collice, M. and Levati, A. Continuous intraoperative electroencephalographic monitoring in carotid endarterectomy. *Eur. Neurol.*, 1986, 25: 53–60.
- North American Symptomatic Carotid Endarterectomy Trial Collaborators. Beneficial effect of carotid endarterectomy in symptomatic patients with high-grade carotid stenosis. *New Engl. J. Med.*, 1991, 325: 445–453.
- Rampil, I.J., Holzer, J.A., Quest, D.O., Rosenbaum, S.H. and Correll, J.W. Prognostic value of computerized EEG analysis during carotid endarterectomy. *Anesth. Analg.*, 1983, 62: 186–192.
- Ringelstein, E.B., Zeumer, H. and Schneider, R. Der Beitrag der zerebralen Computertomographie zur Differentialtypologie und Differentialtherapie des ischämischen Grosshirninfarktes. *Fortschr. Neurol. Psychiat.*, 1985, 53: 315–336.
- Sundt, T.M., Sharbrough, F.W., Piepgras, D.G., Kearns, T.P., Messick, J.M. and O'Fallon, W.M. Correlation of cerebral blood flow and electroencephalographic changes during carotid endarterectomy. *Mayo Clin. Proc.*, 1981, 56: 533–543.
- Trojaborg, W. and Boysen, G. Relation between EEG, regional cerebral blood flow and internal carotid artery pressure during carotid endarterectomy. *Electroenceph. clin. Neurophysiol.*, 1973, 34: 61–69.