

---

## NOTES AND NEW DEVELOPMENTS

---

### **MONOMELIC MUSCLE HYPERTROPHY FOLLOWING TRANSIENT ISCHEMIC ATTACKS: A CASE REPORT**

Edward R. Isaacs, MD, and Paul Larson, MD

---

**Abstract:** A 39-year-old right-handed male suffered several episodes of transient right-sided weakness, sensory loss, and Broca's aphasia at age 31. Diagnostic studies failed to demonstrate any cause for these events. Following a complete recovery, he noted the onset of stiffness and increasing muscle bulk in his right arm, which gradually restricted its use. Simultaneous recordings from contracting biceps and triceps muscles in both arms suggested that the hypertrophy was physiologically induced by an abnormal mechanism providing resistance during phasing activity.

MUSCLE & NERVE 1:242-244 1978

---

It is a unique experience to receive a patient who complains of a progressive increase in bulk and stiffness involving the musculature of one arm. Muscle hypertrophy associated with dystonia or athetosis has been described as a physiologic consequence of a central nervous system disorder,<sup>3</sup> but it is not usually a major feature of such conditions. Hypertrophy as a pathologic manifestation of diseased muscle, such as myotonia congenita or muscular dystrophy, is usually symmetrical<sup>5</sup> and rarely confined to one extremity.<sup>1</sup> Atrophy is a more commonly observed sequel to a cerebrovascular event.

#### **CASE REPORT**

The patient, a 39-year-old right-handed male, was referred to neurology service at Keesler Air Force Base Medical Center, Biloxi, Mississippi, because of progressive enlarge-

ment and stiffness of the muscle of his right arm. At age 31 he experienced four episodes of light headedness, right-sided weakness, and difficulty expressing himself. These episodes began abruptly and lasted for approximately 30 min. During one of these episodes, right-sided hemiparesis with hyperreflexia, hemianesthesia, and Broca's aphasia were documented. A residual, mild, lower-right facial weakness persisted for several days and then cleared. During this period, electroencephalogram, brain scan, left carotid arteriogram, and cerebrospinal fluid evaluation were reported as normal. The patient returned to active duty, his assignment confined to administrative responsibilities and his major physical activity restricted to an occasional game of golf. He denied participation in any formal exercise program. Two years later he noticed mild aching pain and stiffness in his right arm. After that, the right arm became noticeably larger than the left, and because of associated stiffness and cramping, it was finally rendered ineffective for even the simplest of chores. Even a casual handshake would cause the arm to go into painful spasms.

On examination, there was marked hypertrophy of the musculature of the right upper arm and forearm (fig. 1). Circumferential measurements of contracted musculature at symmetrical locations were: right biceps—33 cm, left biceps—29 cm; right forearm—29 cm, left forearm—26 cm; wrist—18 cm bilaterally. At rest, awake and asleep, the patient held his right arm slightly flexed, adducted and internally rotated. When strength was tested, his muscles could not be overcome, but severe cramping with painful spasms quickly ensued and the involved muscles became quite firm. Passive

---

From Richmond Neurological Consultants, Inc., Richmond, VA (Dr. Isaacs), and Louisiana State University Medical School, New Orleans (Dr. Larson).

Read by title at the 111rd International Congress on Muscle Disease, Newcastle upon Tyne, Great Britain, September 15-21, 1974.

The authors wish to thank Dr. Donald C. Oxenhandler for his referral of this patient.

Address reprint requests to Dr. Isaacs at Richmond Neurological Consultants, Inc., 8919 Three Chopt Rd., Richmond, VA 23229.

Received for publication November 16, 1977; revision received February 15, 1978.

motion was slightly limited, with lead-pipe hypertonicity and occasional cogwheeling present in the biceps, triceps, and wrist extensors as well as in the flexors, pronators, and supinators of the right upper extremity. Deep tendon reflexes were depressed in the right arm but normal elsewhere. Percussion myotonia was not present. The remainder of the neurologic examination was normal.

#### MATERIALS AND METHODS

Pertinent studies included X rays of the skull, cervical spine, and both arms and shoulders; electroencephalograms; brain scan; selective four-vessel arteriography; cerebrospinal fluid evaluation; and determination of serum creatine phosphokinase and serum T-3 and T-4 levels. Electrodiagnostic studies showed normal peripheral nerve conduction velocities, and needle electrode studies of the involved muscles showed electrical silence at rest but prolonged discharges of normal-appearing motor units during cramping spasms. No myotonic or bizarre high-frequency discharges were seen even after cooling with ice packs.

Using a four-channel polygraph adapted from a Grass Model 6 Electroencephalograph (Quincy, MA), needle electrode recordings of the right and left triceps and biceps muscles were made simultaneously (fig. 2). Cocontraction with failure of antagonistic muscles on the right to relax was demonstrated. In addition, cocontraction of the right biceps and triceps was seen when either the left biceps or left triceps was maximally contracted. After 1% xylocaine block to the right brachial plexus, there was a dramatic relaxation of the musculature of the right arm for approximately 30 min. There was no concomitant loss of strength or sensation for position, touch, or vibration.

Adequate trials with various medications, such as diphenylhydantoin, levodopa, and amantadine, failed to afford any relaxation. Partial relaxation of the patient's right arm was finally achieved with diazepam, but the dosage had to be increased frequently. A combination of dantrolene sodium 200 mg/day and diazepam 20 mg/day, in divided doses, provided complete sustained relaxation. After three months of this regimen, tone returned to normal and the patient was again using his right arm without difficulty or pain. The following measurements were obtained: right biceps—relaxed 27 cm, contracted 31.5 cm; left biceps—relaxed 26 cm, contracted 29.5 cm; right forearm—relaxed 27 cm, contracted 28 cm; left forearm—relaxed 26 cm, contracted 27 cm.

#### DISCUSSION

The muscle hypertrophy observed in this patient was probably physiologic in that it represented true work hypertrophy. With delayed relaxation of antagonists as well as cocontraction of both agonists and antagonists, there was in effect both static and dynamic exercise against ever-increasing resistance. Both maneuvers are responsible for muscle hypertrophy,<sup>6,10</sup> but the latter may have the greatest influence.<sup>6</sup> The patient's past history of a transient left cerebral dysfunction, along with the tendency for nonvoluntary muscle contractions in the right arm,<sup>8,9</sup> suggests that a left basal ganglion lesion is responsible for the basic abnormality in tone. Relaxation following a 1% xylocaine block suggests an increased contribution from the gamma motor system,<sup>11</sup> either as a direct reflection of a dystonic state or as an aggravating factor resulting from increased feedback from the contracted muscle.<sup>7</sup>




Figure 1. Patient demonstrating marked hypertrophy of the muscles of the right arm and shoulder.

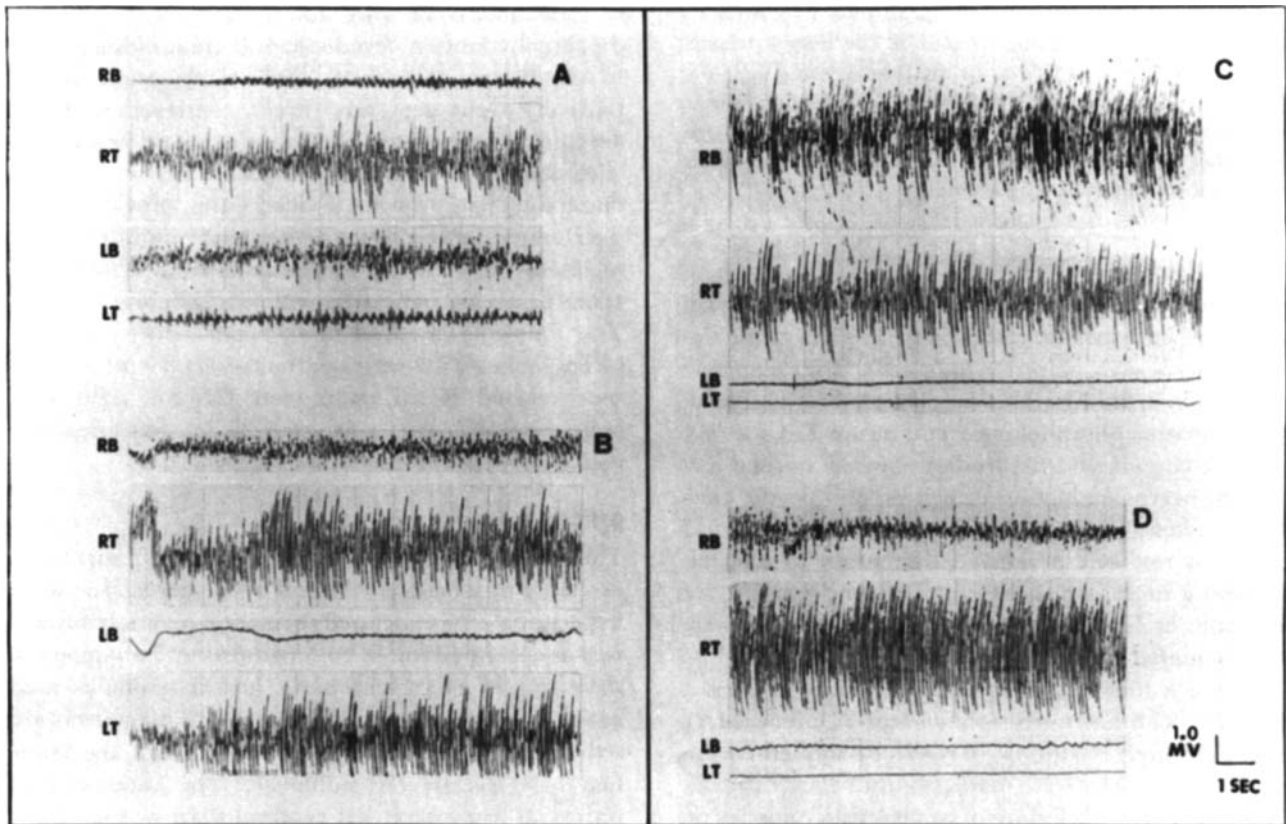


Figure 2. Simultaneous EMG polygraph recordings of right biceps (RB), right triceps (RT), left biceps (LB), and left triceps (LT). Tracings show the effect of voluntary contractions of (A) left biceps, (B) left triceps, (C) right biceps, and (D) right triceps.

The action of dantrolene<sup>2,4</sup> appears to be mainly peripheral. Its ameliorating effect when coupled with diazepam was apparently capable of reversing a positive feedback system underlying or aggravating the

patient's condition. The failure of levodopa, amantadine, or diphenylhydantoin to successfully treat this condition suggests that neither dopaminergic nor peripheral nerve influences were responsible.

## REFERENCES

1. Celesia GG, Andermann F, Wiglesworth FW, Robb JP: Monomelic myopathy. *Arch Neurol* 17:69-77 1967.
2. Chyatte SB, Birdsong JH, Roberson DL: Dantrolene sodium in athetoid cerebral palsy. *Arch Phys Med Rehabil* 54:365-368, 1973.
3. Denny-Brown D: Experimental studies pertaining to hypertrophy, regeneration and degeneration. *Recent Pub Assoc Neu Ment Diseases* 38:147-196, 1961.
4. Dykes MHM: Evaluation of a muscle relaxant: dantrolene sodium (Dantrium). *JAMA* 231:862-864, 1975.
5. Gardner-Medwin D, Walton JN: A classification of the neuromuscular disorders and a note on the clinical examination of the voluntary muscles. In Walton JN (Editor): *Disorders of Voluntary Muscle*, 2nd ed. London, J & A Churchill Ltd, 1969.
6. Gordon EE: Anatomical and biochemical adaptations of muscle to excessive use in compensatory hypertrophy and increased phasic activity. *Physiol Bohemoslov* 20:205-212, 1971.
7. Gordon EE, Januszko DM, Kaufman L: A critical survey of stiff-man syndrome. *Am J Med* 42:582-599, 1967.
8. Green JB: An electromyographic study of mirror movements. *Neurology (Minneapolis)* 17:91-94, 1967.
9. Gregg RA, Mastellone AF, Gersten JW: Cross-exercise—a review of the literature and study utilizing electromyographic techniques. *Am J Phys Med* 36:269-289, 1957.
10. Gutmann E, Hajek I: Differential reaction of muscle to excessive use in compensatory hypertrophy and increased phasic activity. *Physiol Bohemoslov* 20:205-212, 1971.
11. Matthews PBC: *Mammalian Muscle Receptors and Their Central Actions*. London, Edward Arnold Publishers, Ltd, 1972.