

CLINEU 00322

## Case report

**Acute systemic vanadate poisoning presenting as cerebrovascular ischemia with prolonged reversible neurological deficits (PRIND)**Hans-Peter Schlake<sup>a,\*</sup>, Hans Peter Bertram<sup>b</sup>, Ingo Wilhelm Husstedt<sup>c</sup> and Gerhard Schuierer<sup>d</sup><sup>a</sup>*Department of Neurosurgery, University of Würzburg, Josef-Schneider-Straße 11, D-97080 Würzburg, Germany,*<sup>b</sup>*Institute of Pharmacology and Toxicology,* <sup>c</sup>*Department of Neurology,* <sup>d</sup>*Department of Radiology, University of Münster, D-48149 Münster, Germany*

(Received 26 January, 1993)

(Revised, received 26 April, 1993)

(Accepted 30 September, 1993)

**Key words:** Vanadium intoxication; Ammonium metavanadate; Na<sup>+</sup>,K<sup>+</sup>-ATPase**Summary**

A 22-year-old woman is reported who attempted suicide by oral ingestion of approximately 10–15 g ammonium metavanadate (NH<sub>4</sub>VO<sub>3</sub>). A few hours later she developed gastrointestinal symptoms followed by a transient right sensomotor hemiparesis and aphasic disturbances. Brain MRI and SPECT with <sup>99m</sup>Tc-HMPAO revealed a lesion in the left parietal cortex. Plasmapheresis, ascorbic acid and desferoxamine led to a complete clinical recovery within a few days.

**Introduction**

Vanadium (V), a metallic group Vb element (molecular weight 50.9) of the first transition series, is widely distributed in the environment, exerting various effects on enzymatic processes and biological membranes [1–7]. It is supposed to be an essential trace element in some higher animals, and probably in man [2,4,5]. Toxic effects have been described, mainly occurring in oil industry workers and miners after chronic inhalation of dust containing vanadium pentoxide (V<sub>2</sub>O<sub>5</sub>), which results from the combustion of petroleum and coal [6–10]. These toxic effects chiefly include local inflammatory changes of mucous membranes, particularly of the respiratory tract. More recently, vanadium has also been postulated

to play a role in the pathogenesis of manic depressive illness [11,12].

We report here a patient who developed transient hemiplegia and aphasia after oral ingestion of a single high dose of ammonium metavanadate.

**Case report**

A 22-year-old woman attempted suicide by oral intake of a spoonful (approximately 10–15 g) ammonium metavanadate (NH<sub>4</sub>VO<sub>3</sub>), which was available in her workshop place in the pharmaceutical industry (heparin production). After 2 h she developed gastrointestinal symptoms such as nausea, vomiting and diarrhoea. One hour later a right-sided brachiofacial paresis manifested, followed by a right hemihypesthesia and sensomotor paresis of the right lower limb as well as mixed amnesic and sensorimotor aphasia.

\*Corresponding author. Fax: (+49 931) 201 2635.

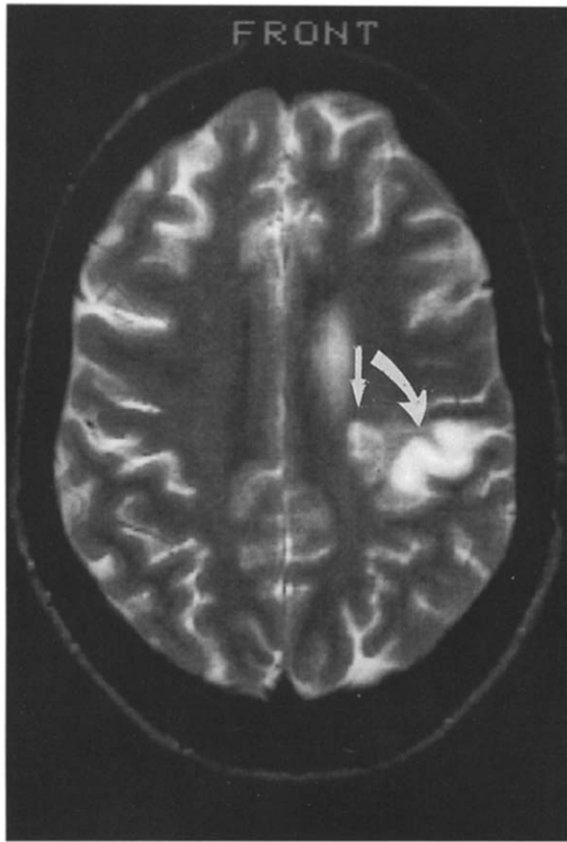


Fig. 1. T<sub>2</sub>-weighted axial MRI (T<sub>R</sub> = 2,800, T<sub>E</sub> = 90) showing a high-intensity signal lesion in the left parietal cortex (→) with slight edema (→) in the adjacent subcortical white matter (R = right, L = left).

Thirty-six hours after vanadate intake only a pronation and drop tendency in the right arm and a slight amnesic aphasia were detectable. Physical examination was normal except for a green discoloration of the tongue and gums.

Internal screening investigations such as ECG, chest X-ray and abdominal sonography were normal. Gastroscopy showed an acute erosive gastritis, which healed completely under antacid therapy.

All routine laboratory tests revealed normal values except some parameters of blood coagulation. There was a decrease of prothrombin time to 32% (normal value: 70–100%); the platelet count was 73 000/μl (n.v.: 150 000–350 000/μl). Fibrinogen plasma levels fell to 1.18 g/l (n.v.: 1.70–4.10 g/l) 72 h after intoxication. PTT (partial thromboplastin time), thrombin time and antithrombin III were within normal range.

After administration of 750 ml fresh frozen plasma all coagulation tests including platelet counts returned to normal values over the next 5 days. Urinalysis showed a

slight proteinuria, erythrocyturia and leucocyturia, which subsided spontaneously. CSF protein was increased (1070 mg/l) with normal cell counts.

Brain T<sub>2</sub>-weighted MRI (T<sub>R</sub> = 2800; T<sub>E</sub> 15/9) revealed a cortical and a subcortical area of increased signal intensity along the dorsal part of the sylvian fissure, the cortical lesions being more pronounced than those in the adjacent subcortical white matter (Fig. 1).

SPECT (370 MBq <sup>99m</sup>Tc-HMPAO) revealed localized hypoperfusion in the corresponding area.

Electroencephalography (EEG) revealed distinct focal delta activity in the left parieto-temporal region. Central latencies of somatosensory evoked potentials (SEP) after tibial nerve stimulation were asymmetrical, yielding delayed latencies over the left sensory cortex (P<sub>40</sub>: 43.9 msec) as compared to the right (P<sub>40</sub>: 38.0 msec). Visual and brainstem auditory evoked potentials as well as SEP from the median nerve and motor evoked potentials (recorded from m. abductor pollicis brevis and m. tibialis anterior) showed bilaterally normal latencies. Nerve conduction velocities of median, peroneal and sural nerve were normal.

Detoxification was based on data from animal experimental studies [13–17]. Treatment included i.v. administration of desferoxamine mesylate (Desferal<sup>®</sup>) at a daily single dose of 500 mg and high oral doses of ascorbic acid (3 × 1.5 g/day), in order to reduce V<sup>3+</sup> to less toxic V<sup>3+</sup> compounds, followed by plasmapheresis (plasma exchange 2100–2300 ml) at each of the following 3 days. Decadron phosphate (3 × 8 mg/day) was given to prevent lung edema.

Fig. 2 shows plasma and urine vanadium levels and

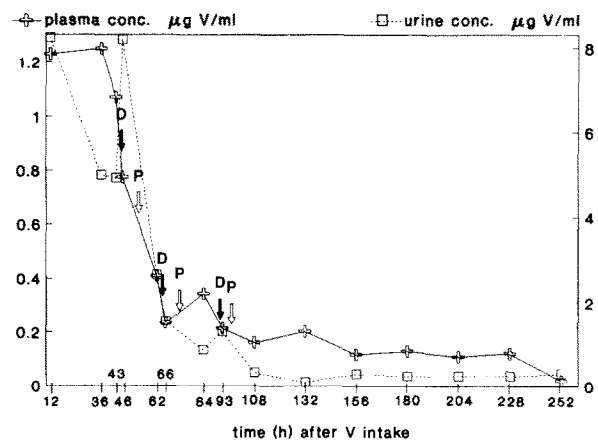


Fig. 2. Time course of vanadium (V) levels in plasma and urine in relation to detoxification therapy D = i.v. administration of a single dose of 500 mg desferoxamine mesylate (Desferal<sup>®</sup>) P = plasmapheresis.

their time course in relation to detoxification therapy, obtained by means of atomic emission spectroscopy; after 36 h the CSF vanadium level was  $<20 \mu \text{ V/l}$ . In non-exposed man normal values are  $0.016\text{--}0.939 \mu \text{g V/l}$  in plasma and  $<1 \mu \text{g V/l}$  in urine [4].

All clinical symptoms subsided within 10 days. Follow-up during one year confirmed the complete recovery.

Vanadium levels in plasma 3 and 9 months later showed normal values, whereas urinary vanadium content was still increased with 61.5 and  $12.3 \mu \text{g V/l}$ , respectively.

## Discussion

The present case is, to our awareness, the first of acute vanadate poisoning in man. The clinical symptoms were unlike those of human cases with chronic vanadium exposure, in whom renal and cardiac disturbances as well as a decrease of blood cholesterol have been described [5,6]. With concern to the central nervous system, only slight and rather unspecific complaints (i.e. tiredness, giddiness and tremor) were observed in a few industrial workers after chronic exposure to vanadium and its compounds [8–10].

Numerous animal experimental studies did not reveal any distinct neurological symptomatology after acute or chronic vanadate administration [1–6,15]. Yet, these investigations showed vanadium compounds to exert a variety of in vivo and in vitro effects on enzymes and biological membranes [2,4–7,13]. Vanadate ( $\text{VO}_3^-$ ) and vanadyl ( $\text{VO}_2^+$ ) are very potent inhibitors of  $\text{Na}^+, \text{K}^+$ -ATPase [1]. Low vanadate concentrations stimulate membrane-bound adenylate cyclase and NADH oxidase, whereas high concentrations lead to enzyme inhibition [2,4,5]. In rat cerebral cortex, both vanadate and vanadyl stimulate phosphorylation of proteins and synaptic membranes, but cause a dose-dependent inhibition of mitochondrial phosphorylation [3].

The clinical symptoms and their course of the present case resemble those of a prolonged reversible ischemia (PRIND) in the area of supply of left middle cerebral artery. The MRI finding of an increased  $T_2$ -weighted signal intensity in the corresponding cortical area is compatible with a vascular lesion. This view was supported by the detection of a focal hypoperfusion left-parietal in SPECT with the flow tracer  $^{99\text{m}}\text{Tc-HMPAO}$ .

Toxic substances usually produce acute bilateral cerebral and/or cerebellar symptoms. It is difficult to under-

stand, how this acute intoxication caused a unilateral lesion. On the other hand, the observed cerebrovascular manifestations occurred only few hours after vanadate ingestion. Except from a moderate nicotine abuse (about 5 cigarettes/day), there were no cerebrovascular risk factors perceptible in the patient's personal or familiar history, i.e. there was no use of oral contraceptives or any other drug treatment. Thus, an accidental coincidence of cerebral ischemia with vanadate poisoning is unlikely.

It seems possible, that the observed alterations of blood coagulation played a primary role in the pathogenesis of cerebrovascular ischemia – for instance, by stimulating fibrinogen activation and causing a disseminated intravascular coagulopathy. However, such effects have not been observed in animal experimental studies after acute or chronic exposure to vanadium compounds.

Altogether, the exact pathomechanisms of the observed cerebrovascular disturbances remain hypothetical. Considering the fact, that spontaneous course of acute vanadate poisoning in man is still unknown, it should be emphasized, that no distinct cause-and-effect relationship can be claimed for the detoxification treatment applied. As long as there are no further experiences, however, this detoxification regimen may serve as a therapeutical guideline.

## References

- 1 Cantley, L.C., Jr., Josephson, L., Warner, R., Yanagisawa, M., Lechene, C. and Guidotti, G. (1977) Vanadate is a potent ( $\text{Na}, \text{K}$ )-ATPase inhibitor found in ATP derived from muscle. *J. Biol. Pharmacol.*, 252: 7421–7423.
- 2 Erdmann, E., Werdan, K., Krawietz, W., Schmitz, W., Scholz, H. (1984) Vanadate and its significance in biochemistry and pharmacology. *Biochem. Pharmacol.*, 33: 945–950.
- 3 Krivánek, J. (1988) Do vanadium ions exert any specific effects on brain phosphorylation. *Neurochem. Res.*, 13: 395–401.
- 4 Nechay, B.R. (1984) Mechanisms of action of vanadium. *Annu. Rev. Pharmacol. Toxicol.*, 24: 501–524.
- 5 Ramasarma, T. and Crane, F.L. (1981) Does vanadium play a role in cellular regulation? In: Vaughan, M. and Moss, J. (Eds.), *Current Topics in Cellular Regulation*, Academic Press, New York, NY, pp. 247–301.
- 6 Faulkner Hudson, T.G. (1964) *Vanadium: Toxicology and biological significance*, Elsevier, Amsterdam.
- 7 Benabe, J.E., Echegoyen, L.A., Pastrana, B. and Martinez-Maldonado, M. (1987) Mechanism of inhibition of glycolysis by vanadate. *J. Biol. Chem.*, 262: 9555–9560.
- 8 Berling, S.-G. (1950) Vanadium pentoxide dust. A clinical

- and experimental investigation on its effects after inhalation. Esselte AB, Stockholm.
- 9 Usutani, S., Nishiyama, K., Sato, I. et al. (1979) Results of the special physical examination of workers in a vanadium plant. *Jap. J. Ind. Health*, 21: 21-28.
  - 10 Byrne, A.R. (1979) On the vanadium and tin contents of diet and human blood. *Sci. Tot. Environ.*, 13: 87-90.
  - 11 Dick, D.A.T., Dick, E.G. and Naylor, G.J. (1980) Plasma vanadium concentration in manic-depressive illness. *J. Physiol.*, 310: 31P.
  - 12 Naylor, G.J. and Smith, A.H.W. (1981) Vanadium: a possible aetiological factor in manic-depressive illness. *Psychol. Med.*, 11: 249-256.
  - 13 Domingo, J.L., Llobet, J.M. and Tomas, J.M. (1986) Influence of chelating agents on the toxicity, distribution and excretion of vanadium in mice. *J. Appl. Toxicol.*, 6: 337-341.
  - 14 Gómez, M., Domingo, J.L., Llobet, J.M. and Paternain, J.L. (1988) Effectiveness of chelation therapy with time after acute vanadium intoxication. *J. Appl. Toxicol.*, 8: 439-444.
  - 15 Hansen, T.V., Aaseth, J. and Alexander, J. (1982) The effect of chelating agents on vanadium distribution in the rat body and on uptake by human erythrocytes. *Arch. Toxicol.*, 50: 195-202.
  - 16 Jones, M.M. and Basinger, M.A. (1983) Chelate antidotes for sodium vanadate and vanadyl sulfate intoxication in mice. *J. Toxicol. Environ. Health*, 12: 749-756.
  - 17 Mitchell, W.G. and Floyd, E.P. (1954) Ascorbic acid and ethylene diamine tetraacetate as antidotes in experimental vanadium poisoning. *Proc. Soc. Exp. Biol. Med.*, 85: 206-208.