

CASE REPORTS

A Case of Paroxysmal Tonic Upward Gaze Associated with Psychomotor Retardation

*Hideo Sugie
Yoko Sugie
Masataka Ito
Satoshi Tsurui
Hiroyuki Kawamura
Hazumi Yamase
Makoto Ogasawara
Yukino Matsui*

Ouvrier and Billson (1988) were the first to report four cases with paroxysmal tonic upward gaze associated with benign clinical outcome. Several criteria were proposed by those authors: onset in infancy, tonic conjugate upward eye-deviation, downbeat saccades, normal horizontal eye-movement, relief after sleep and minor neurological symptoms, including ataxia or clumsiness. We report a patient presenting with frequent paroxysmal upward gaze which occurred in infancy, similar to Ouvrier and Billson's cases; however, our patient also showed moderate developmental retardation and abnormal neuroradiological features.

Case report

This patient was the product of a normal pregnancy and delivery. At the age of four months, she developed paroxysmal upward deviation of the eyes. She was diagnosed elsewhere as having epilepsy and placed on phenobarbitone, with no improvement. At six months, she was referred to us for further evaluation of her abnormal eye movement.

On examination, numerous upward eye-movements were observed. They were characterized by intermittent upward deviations of both eyes, appearing in clusters for 10 to 30 seconds, and lasting for hours. During each episode, she showed compensatory forward tilting of the head, as if to allow her to look at objects before her (Fig. 1), her facial expression was vacant, and she was quite still; she

also had downbeat nystagmus.

Despite the frequency of the episodes, her daily activities, temperament, appetite and sleep-wake cycles were undisturbed. Truncal ataxia was evident occasionally when she was in a sitting position. Her mother reported that the episodes appeared to be exacerbated by fatigue or febrile illness, and relieved by sleep or rest. In addition, when her body was moving at velocity, for example during a car journey, the frequency of her upward gaze seemed to increase.

Neurological examination revealed mild hypotonia and a dull facial expression. All deep tendon reflexes were decreased. No significant muscle weakness was demonstrated; however, observation of her voluntary movements and an asymmetric parachute reaction showed that she had mild left hemiparesis. Ophthalmological examination revealed internal strabismus, but was otherwise normal. MRI of the head showed bilateral periventricular leukomalacia and poor myelination, particularly in the subcortical frontal white matter (Fig. 2). Simultaneous EEG video-monitoring revealed no paroxysmal discharges during the episodes of eye deviation.

To exclude complex partial seizures from the differential diagnosis, we commenced treatment with carbamazepine; no significant improvement was noted. A trial with sodium valproate, phenobarbitone and zonisamide, successively, had no effect on the episodes, nor did treatment with 50mg levodopa and 5mg carbidopa. At one-year follow-up, her episodes of upward gaze had spontaneously decreased in number.

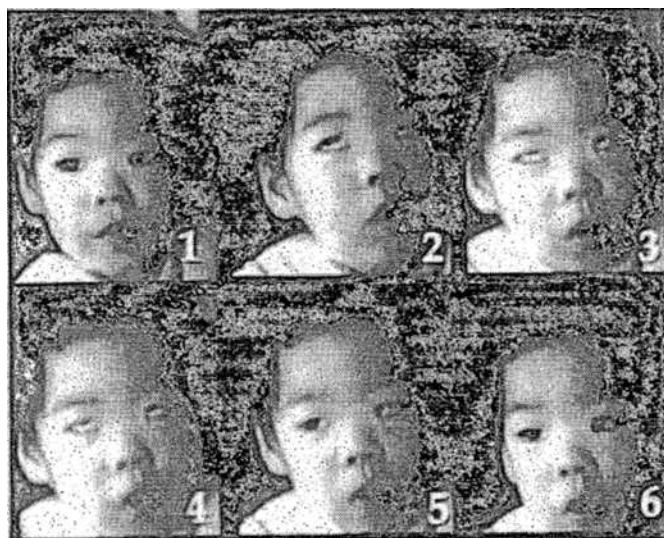


Fig 1. Single frame from video monitoring at approximately five-second intervals. Frame 1: normal eye positions. Frames 2, 3 and 4: upward gaze is apparent with vacant facial expression. Frames 5 and 6: eyes are returning to normal positions.

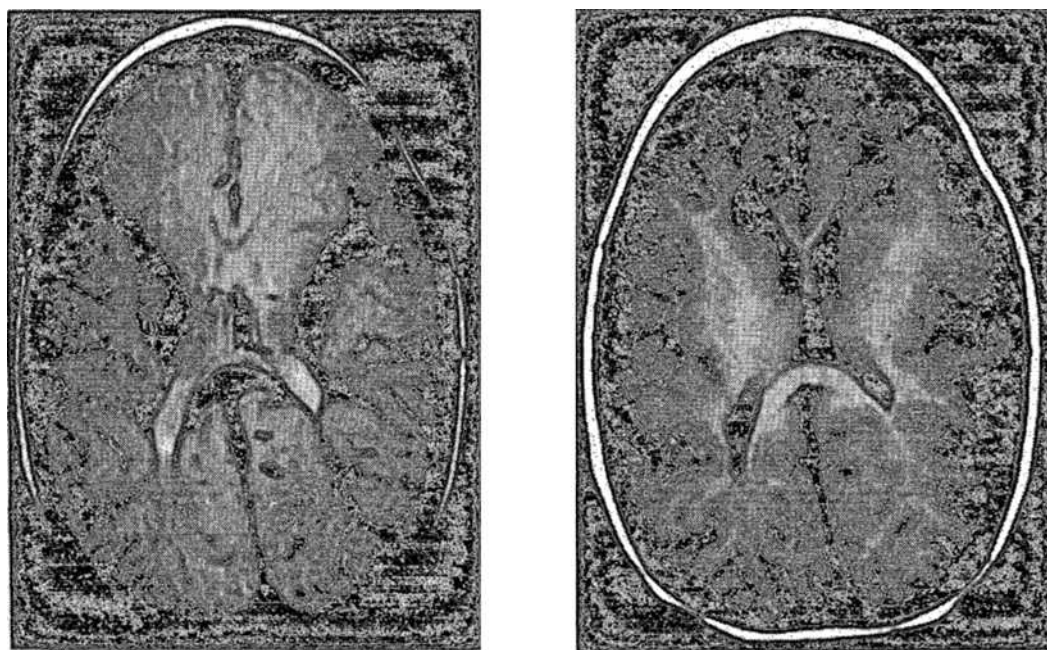


Fig 2. T_1 -weighted (left) and T_2 -weighted (right) MRI. Enlarged frontal horn of lateral ventricles and decreased volume of white matter, suggesting bilateral periventricular leukomalacia. Note poor myelination particularly in subfrontal white matter.

Discussion

Several case reports have been published since Ouvrier and Billson's paper in 1988 (Deonna *et al.* 1990, Echenne and Rivier 1992, Campistol *et al.* 1993 Gieron and Korthals 1993,) (Table I). The problem of whether our case can be considered to have the same disorder described by Ouvrier and Billson lies in the fact that

she had (1) apparent neurodevelopmental abnormalities, and (2) abnormal skull MRI.

As shown in Table I, neurological abnormalities—including mental retardation, motor retardation and seizures—have been demonstrated in the literature, so the association of these might not rule out the same diagnosis. Epileptic

TABLE I
Comparison of reported cases

Study	Age at onset	Sex	Associated symptoms/ development ¹	Drug effect Anticonvulsant L-dopa ²		MRI/CT	EEG
Ouvrier and Billson (1988)							
Case 1	7mths	F	Normal	2+	NG	Normal	Normal
Case 2	8mths	F	Ataxia	-	NG	Normal	Normal
Case 3	20mths	M	Ataxia	-	+	Normal	Normal
Case 4	10mths	M	I.D, tic, clumsiness	-	NG	Normal	Normal
Deonna <i>et al.</i> (1990)							
	10mths	M	Episode of cyanosis, Wide and unsteady gait		NG	Normal	Normal
Echenne and River (1992)							
	10mths	M	Ataxia, FC	-	NG	Normal	Normal
Gieron and Korthals (1993)							
	9mths	M	Cystic fibrosis, ataxia	-	-	Normal	Normal
Campistol <i>et al.</i> (1993)							
Case 1	9mths	M	Clumsiness	-	+	Normal	Normal
Case 2	6mths	M	Ataxia during febrile illness	-	+	Normal	Normal
Case 3	8mths	M	Mental retardation	-		Normal	Normal
Present case	6mths	F	Psychomotor retardation, ataxia	-	-	Abnormal	Normal

¹FC = febrile convulsions, LD = learning disability. ²+ = positive response, - = no response, NG = not given.

seizures, particularly complex partial seizures, were excluded in our case because MRI confirmed organic brain lesion. Simultaneous EEG video-monitoring revealed no paroxysmal discharges during the abnormal eye movements, and anticonvulsants were administered to no effect. Considering these results, together with the clinical features, we believe that our patient's abnormal eye movements can be regarded as a non-epileptic phenomenon, and therefore part of the same spectrum as the disorders documented by Ouvrier and Billson (1988).

The second point of difference was the abnormal MRI of our patient. Conjugate upward gaze in the conscious patient has generally been caused by lesions in the region of the rostral interstitial nuclei of the medial longitudinal fasciculus or the dorsolateral peri-aqueductal mesencephalic grey matter (Leigh and Zee 1983). However, patients with such lesions usually have sustained tonic upward deviation of the eyes, not relieved by sleep or exacerbated by febrile illness. Particular manifestations such as ataxia or clumsiness might suggest that brain-

stem cerebellopontine/cerebellovestibular connections are involved. The symptoms of our case and of the second case of Ouvrier and Billson (1988) were precipitated by rapid movement, suggesting that vestibular stimulation worsened them. Clinically, her episodes of tonic upward gaze spontaneously decreased in number, even though her lesional brain abnormalities showed no significant improvement. This would seem to suggest the co-occurrence of an unrelated neurological problem with benign paroxysmal tonic upward gaze.

The condition proposed by Ouvrier and Billson (1988) occurs at infancy, and seems to evolve into a unique disease entity with a benign clinical outcome, although minor modification of Ouvrier and Billson's criteria might be needed.

Accepted for publication 28th June 1994.

Authors' Appointments

*Hideo Sugie, MD;
Yoko Sugie, MD;
Masataka Ito, MD;
Satoshi Tsurui, MD;
Hiroyuki Kawamura, MD;
Hazumi Yamase, ORT;

Makoto Ogasawara, OT;
Yukino Matsui, PT;
Departments of Pediatric Neurology and
Ophthalmology, and Neuromuscular Laboratory,
Hamamatsu City Medical Center for Developmental
Medicine, Hamamatsu; and Departments of
Pediatrics and Ophthalmology, Hamamatsu

University School of Medicine, Hamamatsu.

*Correspondence to first author at Department of
Pediatric Neurology and Neuromuscular
Laboratory, Hamamatsu City Medical Center for
Developmental Medicine, 775-1 Takazono,
Hamakita City 434, Shizuoka, Japan.

SUMMARY

The authors report a female with paroxysmal tonic upward gaze similar to the cases reported by Ouvrier and Billson (1988). She developed abnormal eye-movements at the age of six months. Several anticonvulsants and levodopa were not effective in the control of the episodes; however, her upward eye-deviations spontaneously decreased during the one-year observation. Her clinical features were almost identical to those reported by Ouvrier and Billson, except that she had neurodevelopmental disorder and abnormal brain MRI. More data are required to clarify this unique phenomenon.

RÉSUMÉ

Un cas d'élévation paroxystique tonique du regard vers le haut associée à un retard mental

L'article décrit une fillette avec un regard paroxystique tonique vers le haut semblable aux descriptions rapportées par Ouvrier et Billson (1988). Elle développa des mouvements anormaux des yeux à l'âge de six mois. Plusieurs anticonvulsifs et la L-dopa se montrèrent inefficaces dans le contrôle des épisodes; en revanche, la tendance au regard vers le haut diminua spontanément durant l'observation d'un an. Les caractéristiques cliniques étaient pratiquement identiques à celles rapportées par Ouvrier et Billson, à l'exception d'un trouble neurodéveloppemental et d'un cerveau anormal à l'IRM. Des données supplémentaires seront nécessaires pour clarifier ce phénomène unique.

ZUSAMMENFASSUNG

Ein Fall mit paroxysmalem, tonischem Blick nach oben im Zusammenhang mit geistiger Retardierung

Die Autoren berichten über eine Patientin mit paroxysmalem tonischem Blick nach oben, ähnlich wie bei den von Ouvrier und Billson (1988) beschriebenen Fällen. Sie entwickelte abnorme Augenbewegungen im Alter von sechs Monaten. Mehrere Antikonvulsiva und Levodopa konnten die Episoden nicht unter Kontrolle bringen; innerhalb des einjährigen Beobachtungszeitraumes wurden ihre nach oben abweichenden Augenbewegungen jedoch spontan geringer. Ihre klinischen Befunde entsprachen denen, die von Ouvrier und Billson beschrieben wurden, außer daß sie noch eine entwicklungsneurologische Störung und ein abnormes Hirn-MRI hatte. Es sind weitere Daten zur Klärung dieses einzigartigen Phänomens erforderlich.

RESUMEN

Un caso de desviación paroxística de la mirada hacia arriba, asociada a retraso psicomotor

Los autores aportan el caso de una niña con accesos paroxísticos de desviación de la mirada hacia arriba, semejantes a los referidos por Ouvrier y Billson en 1988. Inició los movimientos oculares anormales a los seis meses de edad. Diversos anticonvulsivantes y levodopa fueron ineficaces para controlar estos episodios. Sin embargo las desviaciones de la mirada hacia arriba disminuyeron espontáneamente a lo largo del año de observación. La clínica era casi idéntica a la aportada por Ouvrier y Billson, excepto que tenía una alteración del neurodesarrollo y una IRM anómala. Hacen falta más datos para esclarecer este fenómeno único.

References

- Campistol, J., Orats, J. M., Garaizar, C. (1993) 'Benign paroxysmal tonic upgaze of childhood with ataxia. A neuro-ophthalmological syndrome of familial origin?' *Developmental Medicine and Child Neurology*, **35**, 436-439.
- Deonna, Th., Roulet, E., Meyer, H. U. (1990) 'Benign paroxysmal tonic upgaze of childhood. A new syndrome.' *Neuropediatrics*, **21**, 213-214.
- Echenne, B., Rivier, F. (1992) 'Benign paroxysmal tonic upward gaze.' *Pediatric Neurology*, **8**, 154-155.
- Gieron, M. A., Korthals, J. K. (1993) 'Benign paroxysmal tonic upward gaze.' *Pediatric Neurology*, **9**, 159.
- Leigh, R. J., Zee, D. S. (1983) *The Neurology of Eye Movements*. Philadelphia: F. A. Davis, pp. 95-98.
- Ouvrier, R. A., Billson, F. (1988) 'Benign paroxysmal tonic upgaze of childhood.' *Journal of Child Neurology*, **3**, 177-180.