

Crossed aphasia. An update

Luciano Mastronardi, Luigi Ferrante, Alberto Maleci, Fabrizio Puzzilli,
Pierpaolo Lunardi, and Giuseppe Schettini

Department of Neurological Sciences, Neurosurgery, University of Rome “La Sapienza”, Italy

Abstract

The aim of this article is to present an update of a rare but interesting problem: “crossed aphasia”. This term indicates the presence of aphasia after unilateral cerebral lesion of the hemisphere ipsilateral to the patient’s dominant hand. We report two cases, review the most relevant literature, and analyze clinical, neuroanatomical, and neurophysiological aspects, taking in consideration the various interpretations proposed to explain this unusual language disorder.

Keywords: Aphasia, crossed aphasia, hemispheric dominance, language disorders.

1 Introduction

The term “crossed aphasia”, introduced by BRAMWELL in 1899 [9], indicates the presence of aphasia after unilateral cerebral involvement of the hemisphere ipsilateral to the patient’s dominant hand. BRAMWELL [9] maintained that crossed aphasia in a dextral could verify only in a “genetically” left-handed man, who has become right-handed as result of practice (constitutional sinistrality), JACKSON [26], however, affirmed that not in every case of aphasia associated with left hemiplegia was the patient indisputably left-handed. Progressively the concept of crossed aphasia has been confined to aphasia accompanying lesions of right hemisphere in surely right-handed patients [5], without familiarity for left-handedness, even if the left hemisphere seems to be dominant for language in both right- and left-handed subjects [17].

Thus, a reliable diagnosis of crossed aphasia should be based on: A) neuropsychological assessment of dominant hemisphere; B) lack of familiarity for left-handedness; C) lack of lesions on left hemisphere, proved by CT or MRI or by pathological examination [18, 25, 41].

Crossed aphasia can be a source of detailed information about the functional and anatomical organization of the cognitive system [8]. Reporting two cases of crossed aphasia in two dextral subjects, we analyze the clinical aspects of this particular speech disorder, with the aim of examining the possible neuro-anatomical and neurophysiological correlations.

2 Case reports

Case 1. M. C., 69-year-old, monolingual, right-handed man (tested by the Edinburgh Handedness Inventory), without family history of left-handedness. Since three months before admission, he had suffered from motor Jacksonian seizures on left-hemisoma. A cerebral CT scan showed an intraparenchymal, homogeneous, right-sided temporal-parietal tumor, with irregular contrast enhancement (Figure 1). A subtotal removal of tumor was performed and the neoplasm pathological examination showed a WHO Grade 3 astrocytoma [9]. Few weeks later the patient underwent radiotherapy and chemotherapy, with marked reduction of the deep tumoral residue.

Six months after operation he again suffered Jacksonian seizures on the left limbs, followed by

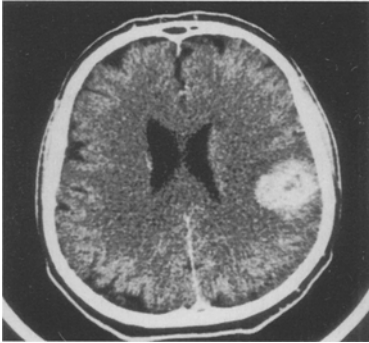

Figure 1. Cerebral CT scan: right temporal-parietal tumor (high-grade astrocytoma), with irregular contrast enhancement.

a transient motor disphasia. A cerebral CT scan showed a growth of residual tumor, with posterior and deep extension; the left hemisphere appeared undamaged. A further radio- and chemotherapy cycle was performed and seizures were controlled with drugs.

About one year after operation, the patient began to present a progressive left sided hemiparesis and expressive disphasia: he formulated sentences with no more than 6–8 words, committing about 50% of syntactic and semantic errors, with acceptable phonetic expression. Paraphasias, neologisms and persevering errors were frequent. Verbal learning, short sentence repetition and memory were impaired. A slight dysgraphia was also present; comprehension of read sentences was preserved. Visuo-spatial and calculation abilities were moderately impaired.

A cerebral MRI showed a further increase of the dimensions of tumor and the appearance of a small right frontal mass; no lesions were present on the left hemisphere. After a further chemotherapy cycle the neurological conditions remain substantially unchanged. The patients died few months later for progression of tumor.

Case 2. M.M., 45-year-old, monolingual right-handed woman (Edinburgh Handedness Inventory), without family history of left-handedness. Six years ago she was operated on for a right temporal WHO Grade 2 fibrillary astrocytoma [39] and subsequently treated with radiotherapy.

A cerebral CT scan performed sixteen months later because of reappearance of seizures revealed a recurrence of the tumor, with deep extension (Figure 2). A subtotal excision of the mass was performed, leaving the deepest part of tumor in situ, in relation to the slight preoperative neurological picture. Histological examination showed a malignant transformation of neoplasm (WHO Grade 4 glioma) [39]. Three days after operation the patient presented progressive left hemiparesis and mixed disphasia, caused by a severe edematous reaction. She formulated only short sentences, with frequent syntactic, phonemic and semantic errors; paraphasias were also very common. The ability to comprehend verbal and written orders was partially impaired, with severe agraphia. Visuo-spatial, calculation, praxis and constructional abilities were moderately impaired. With the help of cortisonics and osmotics the clinical symptoms disappeared. Fifteen days after operation intraarterial chemotherapy (Carboplatin 600 mg/m² in right common carotid artery) was attempted: 10 minutes after the onset of infusion severe left hemiparesis appeared, accompanied by complete aphasia. The injection of radioopaque contrast medium revealed a marked vasospasm of the right middle cerebral artery, forcing us to interrupt the procedure. A few hours later neurological deficits improved, hemiparesis disappearing in 48 hours and aphasia in one week (the verbal expression was the last to recover). Four months later the patient presented an acute

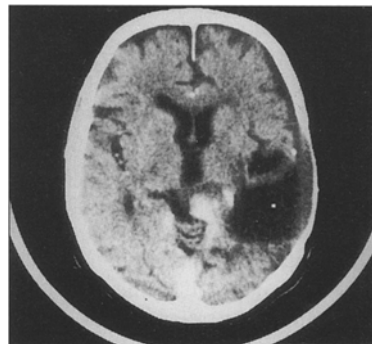


Figure 2. Cerebral CT scan: recurrence of a right temporal glioma, with deep extension (sixteen months later the first operation).

and severe deterioration of neurological condition with drowsiness, left hemiparesis, and global aphasia. A cerebral CT scan showed a deep recurrence of tumor, without involvement of left hemisphere. The relatives refused the hospitalization and three weeks later the woman died.

3 Discussion

The incidence of crossed aphasia in monolingual subjects after unilateral cerebral lesion is rather uncommon, ranging from 0.38% to 2% of all dextral aphasics [2, 6, 21, 24, 32, 38, 41, 49], and extremely rare in children [17]. Even if some authors reported a higher incidence (4.6%–15%) [20, 29, 42], these differences probably express a lack of pathologic confirmation of the location of lesions as well as different criteria of evaluation [44]. The incidence of crossed aphasia seems to be higher in multiracial [4] and in bi- or multilingual populations [20, 29], especially in those bilingual people whose language is not written [29], the most affected people seeming to be the Indians [16]. Even if some authors maintain that the incidence of crossed aphasia is the same in multi- and mono-linguals [16, 23], KARANTH et al. [20] report a clear difference between the two groups (25% versus zero, respectively), supporting that multilingualism could result from a bilateral representation of language [1, 33, 46]. Moreover, the incidence seems to be higher in left-handed people (from 25% to 33%) [20, 21, 42], perhaps because of more than two thirds of these people have left-hemisphere dominance for language [17].

Some authors [3, 12, 45, 47] describe crossed aphasia as a generally non-fluent speech disorder, whereas others [25] observe that these patients are frequently fluent. Of 26 crossed aphasics reviewed by FAGLIA et al. [18] 10 had Broca's, 6 Wernicke's, 1 global, 1 transcortical sensory, and 1 mixed transcortical aphasia, whereas 4 were not clearly classifiable. In some cases there was not the same involvement of the spoken and the written language, suggesting that a possible dissociation of cognitive disturbances were present (visuo-spatial disorders and left spatial neglect), whereas apraxia was less frequent [18]. In the cases reviewed by ALEXANDER et al. [2] ideomotor apraxia was present in 11 of 24 cases, whereas

14 of 30 had visuo-spatial impairment. Therefore, in about 50% of patients the right hemisphere controlled both visuo-spatial functions and language [2, 18]. Limb praxis seems to be more strongly related to handedness than to language, being spared in about $\frac{2}{3}$ of crossed aphasics, whereas buccofacial praxis seems to be more closely related to language [2].

Phonological and semantic levels of language could be lateralized differently, supporting the concept of dissociation of functions [2, 8]. In the case reported by NAGARAJA et al. [32] the presence of Gerstmann's syndrome seems to be indicative of a complete cross-over of hemispheric functions, even if the lack of apraxia suggests that praxis is controlled by the left hemisphere.

On the basis of several neuroanatomical, neurophysiological, and clinical discordances some authors [7, 41] suggested that there may be more than one "crossed aphasia" syndrome. In 23 cases reviewed by ALEXANDER et al. [2], 22 had an aphasia profile typical of intrahemispheric localization. In these cases the aphasic profile might be considered a "mirror image" [2, 25, 41], since the language centers should be localized on the non-dominant hemisphere, without lateralization of other functions ("crossed aphasia type 1"). In 12 cases the aphasia was fluent, in 11 with jargon-agraphia too, despite suprasylvian, prerolandic, or perirolandic injuries [2]. These 12 patients had an "anomalous" aphasia pattern [2, 41], recognizable as the "crossed aphasia type 2".

In type 1 in which all language seems to be lateralized on right hemisphere, the injury is generally severe, the recovery is usually slow and incomplete, and writing and reading are equally affected [2, 6, 15, 40, 44, 48]. The possible presence of Gerstmann's syndrome [32] would indicate the complete cross-over of parietal functions [28]. In type 2, among which we could include our two cases, aphasia is generally slight and transient, speech and writing are differentially affected, praxis and other dominant parietal lobe functions are rarely impaired [2, 22, 41, 47, 49]. This dissociated lateralization of cerebral functions should support the hypothesis of anomalous hemispheric dominance [30], with independent lateralization of language, praxis, and visuo-spa-

tial functions. In "anomalous" crossed aphasia the lesion of the right central perirolandic regions could have a role in the phonemic alteration of language, accounting for the unexpected fluent conduction of patients who frequently present phonemic substitution in spoken and written language [2, 17]. Analyzing short-term memory in relation to sentence comprehension in a crossed aphasic, BERNDT et al. [8] affirmed that in right-handed people a close left hemisphere representation of auditory and phonological processing could exist, whereas the right hemisphere could be involved in semantic and lexical analysis. Therefore, it is possible that the corpus callosum works, at least in some subjects, as a "phonological transformer" of visual and auditory informations [23], also explaining the possible appearance of mutism as consequence of callosotomy [43].

The site of lesions causing crossed aphasia is variable and often in disagree with the clinical picture. The damage might be cortical, subcortical (as in our two cases) or both [18], against the hypothesis of a preferred right basal ganglia involvement [7, 15]. There would be no relationships between the crossed aphasia and the pattern of cerebral asymmetries [25], even if we have only a few CT and MRI information. SPECT and PET studies can be undoubtedly useful, revealing rCBF and metabolism of involved right cortical regions [34, 41]. With the help of the PET, RAICHLÉ [36] identified cerebral areas active when hearing words different from those when seeing words, and again from those areas concerned with the motor output of speaking the words and finally from those involved in generating the meaning of words. Viewing and hearing words areas were identified by PET in the motor cortex over the sylvian cortex (supplementary motor area) and in the cerebellum: during the generation of a word the areas of greatest activity were the left frontal cortex, the anterior circulate cortex and the right cerebellum [36]. Therefore, the cognitive implications of cerebellar hemispheres are profound, especially when it comes to learning new tasks [36].

Crossed aphasia has been attributed to ambilaterality, familial sinistrality, earlier brain damage, epilepsy, bilateral representation of language [2, 11, 18, 27, 35, 47, 49], as well as partial or complete cross-over of left hemisphere functions to the right side [28]. According to some authors [3, 43] crossed aphasia could be similar to aphasia observed in children in whom language dominance is not yet firmly established. Others [13, 31, 37] support the hypothesis of a weak correlation between handedness and speech lateralization (also supported by dysphasia evocation after unilateral non-dominant electroconvulsive therapy), stressing the importance of the sodium amytal test in determining the hemisphere responsible for language [13, 31]. More recently, JOANNETTE et al. [27] proposed several etiopathogenetic hypotheses to explain crossed aphasia: anatomical aberration, genetic factors, arrest of the trial of lateralization, early functional reorganization after a brain damage during childhood, essential functional aberration, and lesion of subcortical gray matter, even if none seems to be fully satisfactory [27].

To these factors we might add the possible role placed by the congenital deafness (or decreased hearing) in the right ear during the hemispherical functional specialization [35]. In spite of the complex mixture of afferent acoustic fibers, the majority of inputs reach the primary auditory cortex of the contralateral hemisphere, especially of the dominant one [10, 35]. In right-handed people a decrease in hearing from birth or early childhood could provoke a lower auditory stimulation of the dominant hemisphere, probably encouraging a greater or complete contralateral development of language centers [35]. This could be possible also for a congenital and subclinical impairment of the right acoustic pathway and/or of the relative interposed nuclei. Thus the right hemisphere would decode a larger number of verbal messages than the contralateral and than physiological standard levels [35]. If neuroanatomical and neurophysiological studies prove this interpretation, the use of brain stem evoked potentials could result useful in routine preoperative examinations for determining the lateralization of language.

References

- [1] ALBERT ML, LK OBLER: The bilingual brain. New York, Academic Press, 1978
- [2] ALEXANDER MP, MR FISCHETTE, RS FISCHER: Crossed aphasias can be mirror image or anomalous. Case report, review and hypothesis. *Brain* 113 (1989) 953–973
- [3] ANGELERGUES R, H HECAEN, R DJINDJIAN, N JARRIE-HAZAN: Un cas d'aphasie croisée (thrombose de l'artère sylvienne droite chez une droitère). *Revue Neurol* 143 (1987) 294–297
- [4] APRIL RS, M HAN: Crossed aphasia in a right-handed bilingual chinese man. *Arch Neurol* 37 (1980) 342–346
- [5] ARDIN-DELTEIL F, A LEVI-VALENSI, G. DERRIEU: Aphasie de Broca par lésion de l'hémisphère droit chez une droitère. *Rev Neurol* 1 (1923) 14–21
- [6] ASSAL G, E PERENTES, JP DERUAZ: Crossed aphasia in a right-handed patient. *Arch Neurol* 38 (1981) 455–458
- [7] BASSO A, E CAPITANI, M LAIACONA, ME ZANOBIO: Crossed aphasia: one or more syndromes? *Cortex* 21 (1985) 25–45
- [8] BERNDT SR, CC MITCHUM, TR PRICE: Short-term memory sentence comprehension. An investigation of a patient with crossed aphasia. *Brain* 114 (1991) 263–280
- [9] BRAMWELL B: On "crossed aphasia". *Lancet* 1 (1899) 1473–1479
- [10] BRODAL A: Neurological anatomy, in relation to clinical medicine. New York, Oxford University Press, 3rd edition, 1981
- [11] BROWN JW, FR WILSON: Crossed aphasia in a dextral. A case report. *Neurology* 23 (1973) 907–911
- [12] BRUST JCM, C PLANK, A BURKE, MMJ GUBADIA, EB HEALTON: Language disorder in a right hander after occlusion of the right anterior cerebral artery. *Neurology* 32 (1982) 492–497
- [13] BRYDEN MP: Laterality – Functional asymmetry in the intact brain. New York, Academic Press, 1982
- [14] BURD L, G GASCON, R SWENSON, R HANKEY: Crossed aphasia in early childhood. *Develop Med Child Neurol* 32 (1990) 528–546
- [15] CARR RS, T JACOBSON, F BOLLER: Crossed aphasia: analysis of four cases. *Brain Lang* 14 (1981) 190–202
- [16] CHARY P: Aphasia in multilingual society: a preliminary study. In: VAID J (ed): Language processing in bilinguals: psycholinguistic and neuropsychological perspectives. Hillsdale, New Jersey Lawrence Erlbaum Associates, 1986
- [17] DAMASIO AR: Aphasia. *N Engl J Med* 326 (1992) 531–539
- [18] FAGLIA L, MR ROTTOLI, LA VIGNOLO: Aphasia due to lesion confined to the right hemisphere in right handed patients: a review of the literature including the Italian cases. *Ital J Neurol Sci* 11 (1990) 131–144
- [19] FAGLIA L, LA VIGNOLO: A case of "crossed aphasia" in which the integrity of the left hemisphere is assessed by MRI. *It J Neurol Sci* 11 (1990) 51–55
- [20] GALLOWAY L: Towards a neuropsychological model of bilingualism and second language performance: a theoretical article with a critical review of current research and some new hypotheses. In: LONG M, S PECK, K BAILEY (eds): Research in second language acquisition. Rowley, MA, Newbury House, 1980
- [21] GLONING L, K GLONING, G HAUB, R QUATEMBER: Comparison of verbal behavior in right-handed and non-right-handed patients with anatomically verified lesions of one hemisphere. *Cortex* 5 (1969) 43–52
- [22] HAALAND KY, F MIRANDA: Psychometric and CT scan measurement in a case of crossed aphasia in a dextral. *Brain Lang* 17 (1982) 240–260
- [23] HAMASAKI T, K SUZUKI, K HIRAKAWA, Y IMAHORI, S NAKAJIMA: Un cas japonais d'aphasie croisée chez un droitier. *Revue Neurol* 143 (1987) 47–54
- [24] HECAEN H, G MAZARS, AM RAMIER, MC GOLDBLUM, L MERIENNE: Aphasie croisée chez un sujet droitier bilingue (vietnamien-français). *Revue Neurol* 124 (1971) 319–323
- [25] HENDERSON VW: Speech fluency in crossed aphasia. *Brain* 106 (1983) 837–857
- [26] JACKSON JH: On aphasia with left hemiplegia. *Lancet* (1880) 637–638
- [27] JOANETTE Y, M PUEL, JL NESPOULOUS, A RASCOL, A ROCH LECOURS: Aphasie croisée chez les droitiers. *Revue de la littérature. Revue Neurol* 138 (1982) 575–586
- [28] KAPUR N, B DUNKLEY: Neuropsychological analysis of a case of crossed aphasia verified at post-mortem. *Brain Lang* 23 (1984) 134–147
- [29] KARANTH P, GM RANGAMANI: Crossed aphasia in multilinguals. *Brain Lang* 34 (1988) 169–180
- [30] KREINDLER A, FRADIS A, N SEVASTOPOL: La répartition des dominances hémisphériques. *Neuropsychologia* 4 (1966) 143–149
- [31] MILNER B, C BRANCH, TH RASMUSSEN: Evidence for bilateral speech representation in some non-right handers. *Trans Am Neurol Assoc* 91 (1966) 306–308
- [32] NAGARAJA D, AB TALY, G HERLEKAR, GM RANGAMANI, N SHIVASHANKAR, CR MUKUNDAN: Crossed aphasia in a dextral. *Clin Neurol Neurosurg* 91 (1989) 153–156[41] SAKURAI Y, H KUR-

- ISAKI, K TAKEDA et al: Japanese crossed Wernicke's aphasia. *Neurology* 42 (1992) 144–148
- [33] PARADIS M: The assessment of bilingual aphasia. Hillsdale, New Jersey Lawrence Erlbaum Associates, 1987
- [34] PETERSEN SE, PT FOX, MI POSNER, M MINTUN, ME RAICHLER: Positron emission tomographic studies of the cortical anatomy of single-word processing. *Nature* 331 (1988) 585–589
- [35] PUEL M, Y JOANETTE, M LEVRAT et al: Aphasie croisée chez les droitiers. *Revue Neurol* 138 (1982) 578–600
- [36] RAICHLER M: Visual language imaging research. *AANS Bulletin*, Summer 1992
- [37] RASMUSSEN R, B MILNER: The role of early left-brain injury in determining lateralization of cerebral functions. *Ann NY Acad Sci* 299 (1977) 355–369
- [38] RUSSEL WR, MLE ESPIR: Traumatic aphasia. Oxford, England, Oxford University Press, 1961
- [39] RUSSEL DS, LJ RUBINSTEIN: Pathology of Tumours of the Nervous System. Edinburgh, Edward Arnold, ed 4, 1977
- [40] SADASIVAM PB, V JAGANNATHAN: Crossed aphasia in a dextral. *J Assoc Phys Ind* 25 (1977) 167–170
- [41] SAKURAI Y, H KURISAKI, K TAKEDA et al: Japanese crossed Wernicke's aphasia. *Neurology* 42 (1992) 144–148
- [42] SEGALOWITZ SJ, MP BRYDEN: Individual differences in hemispheric representation of language. In: SEGALOWITZ SJ (ed): Language function and brain organization. New York, Academy Press, 1983
- [43] SUSSMAN NM; RC GUR, RE GUR, MJ O'CONNOR: Mutism is a consequence of callosotomy. *J Neurosurg* 59 (1983) 514–519
- [44] TROJANOWSKI JQ, RC GREEN, DN LEVINE: Crossed aphasia in a dextral: a clinicopathological study. *Neurology* 30 (1980) 709–713
- [45] URBAIN E, X SERON, A REMITS, A COBBEN, M VAN DER LINDEN, R MOUCHETTE: Aphasie croisée chez une droitière. A propos d'une observation. *Revue Neurol* 134 (1978) 751–759
- [46] VAID J: Bilingualism and brain lateralization. In: SEGALOWITZ SJ (ed): Language functions and brain organization. New York, Academic Press, 1981
- [47] VAID J, Brown JW, H Hecaen: Lateralization of language representation. Observations on aphasia in children left handers and anomalous dextrals. *Neurology* 26 (1976) 183–189
- [48] YARNELL PR: Crossed dextral aphasia: a clinical radiological correlation. *Brain Lang* 12 (1981) 128–139
- [49] ZANGWILL OL: Two cases of crossed aphasia in dextrals. *Neuropsychologia* 17 (1979) 167–172

Submitted February 17, 1993. Accepted November 30, 1993.

Luciano Mastronardi, M. D.
Neurochirurgia
Università "La Sapienza"
Viale dell'Università 30/A
I-00185 Rome
Italy