

RIGHT-LEFT CONFUSION IN GERSTMANN'S SYNDROME: A MODEL OF BODY CENTERED SPATIAL ORIENTATION

Michael Gold, John C. Adair, Daniel H. Jacobs and Kenneth M. Heilman

(Department of Neurology, University of Florida College of Medicine, Gainesville, FL;
Neurology Service, Veterans Affairs Medical Center, Gainesville, FL)

ABSTRACT

Gerstmann's syndrome encompasses the tetrad of finger agnosia, agraphia, acalculia and right-left confusion and is associated with lesions of the dominant angular gyrus. The localizing value of this syndrome has been questioned because multiple mechanisms can account for each of the components of the syndrome. We present the case of a man who developed Gerstmann's syndrome following a focal infarct of the left angular gyrus. The patient's right-left confusion could not be accounted for by either an aphasia or a degraded body schema. A series of experiments that investigated the patient's spatial mapping system by progressively restricting the degrees of freedom for spatial rotation revealed an isolated defect in deriving the relative position of an object along the horizontal axis. Defective horizontal mapping can account for the other components of Gerstmann's syndrome because they all share a common dependency on relative horizontal positioning.

INTRODUCTION

Joseph Gerstmann reported a patient with finger agnosia, agraphia and acalculia following a left-sided parieto-occipital lesion in 1924 (Gerstmann, 1924). Although right-left confusion was not part of the initial description of the left parieto-occipital syndrome, by 1930 Gerstmann (1930) had included it. Subsequent reports of similar collections of deficits in association with lesions of the left parieto-occipital junction led to the designation of this tetrad of clinical finding as Gerstmann's syndrome. An active debate has followed for many years regarding the localizing value or the clinical constancy of this syndrome. Reports of isolated deficits or of partial combinations of the components of Gerstmann's syndrome have raised question about its value as a unitary clinical syndrome (Benton, 1961; Critcheley, 1966; Heimburger, 1964).

One of the major criticism regarding Gerstmann's syndrome is that each of the defects in the classical tetrad might be multi-factorial in origin (Benton, 1977). Since the underlying defects in Gerstmann's syndrome have not been fully explored, the mechanisms that may be common to some if not all of the components of this syndrome remain to be defined.

Multiple theories have been invoked to explain the right-left confusion frequently noted in cases labelled as having Gerstmann's syndrome. According to Head (1926), right-left confusion may be due to a defect in symbolic thought. Therefore, patients may have problems applying the verbal labels "right" and

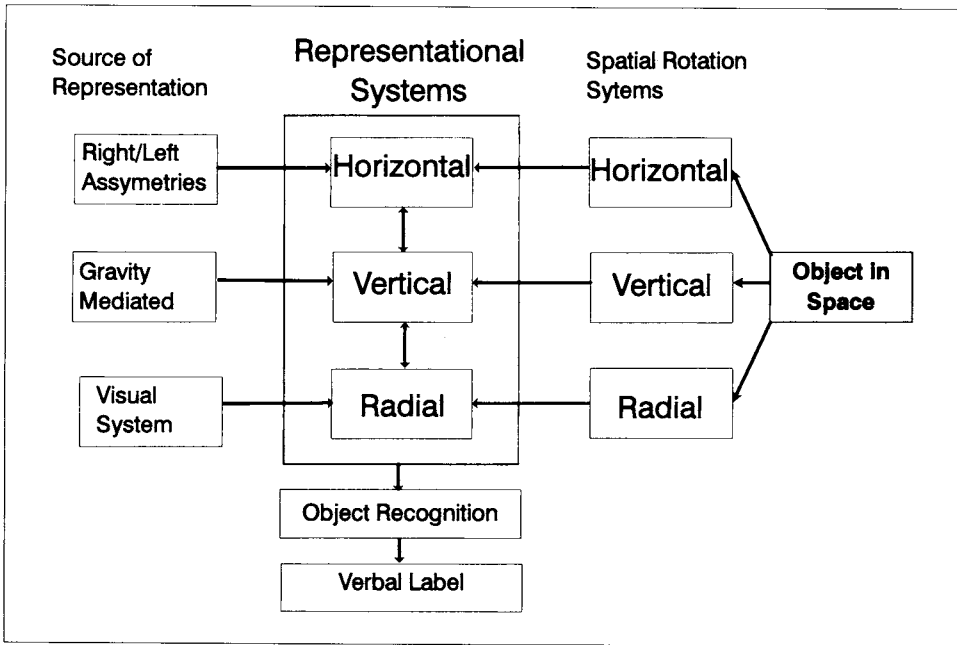


Fig. 1 – A model of body-centered spatial orientation.

“left” to part of a body or to a part of an object. A second theory (Benton, 1959) posits a defect in a body schema such that one’s knowledge about body parts, including lateralization, is defective. Patients with a defective body schema would have problems identifying certain body parts in addition to making right-left errors when asked to identify lateralized body parts. A final theory (Benton and Sivan, 1993) posits that there is a defect in spatial mapping. Spatial mapping is thought to be necessary for the identification of the relative position of an object confronting the patient or in the performance of cross-body commands. Defects in both tasks are commonly found in patients with Gerstmann’s syndrome.

PROPOSED MODEL

We propose a model (see Figure 1) that can be used to explain the features of the right-left confusion seen in some patients with Gerstmann’s syndrome. The existence of mental representations of body-centered right/left (horizontal), up/down (vertical) and near/far (radial) knowledge is central to our model. Spatial representations, as suggested by Stengel (1944), incorporate complex knowledge relating the position of external objects in space to one’s body.

These representations may be present to some extent at birth, but as in the case of horizontal representations, they may develop with experience. Because changing a patient’s orientation in respect to gravity has an effect on their vertical spatial neglect (Mennemeier et al., 1995), we infer that vertical representations

(knowledge about what is above/below one's own body) are referenced to gravity.

We also posit that one's radial representations (knowledge of what is near/far to one's own body) use the horizon as a reference. Finally, we agree that self-body horizontal representations (knowledge of what is right/left on one's own body) are acquired by integration of asymmetrical somatosensory signals received from both sides of the body (Benton, 1959) or by the development of hemispheric asymmetry and dominance superimposed onto a pre-existing body schema.

In contrast to self-body orientation, the determination of other-body right/left orientation depends on the development of spatial rotation systems that allow other-body information to be integrated with previously established horizontal representations, which now serve as a reference. According to a body-centered model of spatial orientation, in order to label the sides of an object in space one must have the ability to rotate the image of an object in three dimensions to derive a body-centered view, which is then compared to the body-centered representation. Once the comparison occurs and a laterality decision is made, the appropriate verbal label or motor response is activated.

Spatial rotation involves the visualization of movement of an object or of the viewer through three-dimensional space. This movement can be interpreted as linear translation along one, two or three orthogonal axes and can be described as movement along an axis, movement in a plane or movement in space, respectively.

We report a case of a patient with an angular gyrus lesion who had all the features of Gerstmann's syndrome. We performed a series of experiments on this patient designed to explore some of the previously mentioned theories of right-left disorientation and to provide data for an integrated model of right-left confusion based on a defect in spatial mapping. We investigated the patient's spatial rotational abilities by presenting tasks that progressively restricted the number of axes available for spatial mapping tasks in order to determine if faulty spatial mapping could be limited to a single axis or a combination of axes.

CASE REPORT

A 79-year-old, right-handed man was admitted after the onset of right-sided weakness. The patient reported four similar, but transient (<30 min) episodes during the month preceding hospitalization. The patient denied previous focal neurological deficits, head trauma or seizures. The patient's past medical history was significant for ischemic heart disease and coronary bypass surgery in 1990.

Neurological examination on admission revealed an alert and cooperative patient whose spontaneous speech appeared to be normal. The patient was anosodiaphoric in relation to his right-sided weakness, but there was no evidence of Gerstmann's syndrome. The day after admission the patient experienced a worsening of his symptoms, developing right-sided hemiplegia, finger agnosia, right-left confusion, apractic agraphia and acalculia. The right-left confusion noted during our clinical evaluation was notable for the increased difficulty the patient experienced when asked to name or point to body parts of an examiner facing him as compared to milder problems naming or pointing to parts of his own body. Magnetic resonance imaging performed on the third day of hospitalization revealed a hyperintense

signal on T2-weighted images that corresponded to the left angular gyrus and its underlying white matter.

STANDARDIZED NEUROPSYCHOLOGICAL TESTS

The patient was given a battery of standardized tests including the Western Aphasia Battery (Kertesz, 1979), Boston Naming Test (Kaplan, Goodglass and Weintraub, 1978), Letter Fluency (Benton and Hamsher, 1976) and Category Fluency (Chertkow and Bub, 1990), Wisconsin Card Sorting Test (Berg, 1948), Trail-Marking Test (Army Individual Test Battery, 1944), California Verbal Learning Test (Delis, Kramer, Kaplan et al., 1983), Continuous Visual Memory Test (Trahan and Larrabee, 1983), digit-span subtest from the Wechsler Adult Intelligence Scale-Revised (Wechsler, 1981), Money Road Map Test (Money, 1976) and line bisection and target cancellation tests for hemispatial neglect (Heilman, Watson and Valenstein, 1993). The patient's performance on these tests was compared to published norms for each specific test. The patient achieved a normal aphasia quotient of 81 on the Western Aphasia Battery; however, the test revealed mild problems with reading comprehension and severe problems with calculations (chance performance level). The performance on the Boston Naming Test was normal (56/60).

Letter and Category fluency tasks were both defective. Executive function as assessed by the Wisconsin Card Sorting Test and by the Trail-Making Test was defective. Verbal memory assessed by the California Verbal Learning Test was defective, however, non-verbal memory as assessed by the Continuous Visual Memory Test was normal. The patient was only able to achieve a digit span of four, which is considered defective. Line bisection and target cancellation tests failed to reveal any hemispatial neglect. Directional sense as assessed by the Money Road Map Test was absent. The number of errors committed by the patient (15/32) matched the performance of normal seven- to eight-year-old children.

Although multiple domains of cognition are affected, the type of cognitive defects and the natural history of the patient's illness fit in quite well with the description of patients with dominant angular gyrus lesion (Benson, Cummings and Tsai, 1982). We also concluded from this standardized testing that neither our patient's comprehension defects nor his language output were affected enough to interfere with the investigation of his right/left confusion.

STATISTICAL METHOD

Statistical comparisons were performed using a two-sided Pearson Chi-square test for homogeneity with one degree of freedom unless stated otherwise. Following Daniel's (Daniel, 1990) recommendations, Yate's correction is not used and data from normal controls are pooled.

EXPERIMENT 1

Is Right-Left Confusion a Problem with the Misapplication of Verbal Labels?

In this experiment, we compared the accuracy in a task that required the patient to name body parts or to point to a named body part. According to the theory of verbal mislabelling, when asked to name a lateralized (right/left) body part, he should perform abnormally. However, when asked to point to a body part, he should perform normally. We compared the patient's accuracy in naming and pointing to lateralized body parts to a group of four age-, sex- and handedness-matched normal controls.

Materials and Methods

The examiner pointed to lateralized body parts (e.g. right hand) and asked the patient or control subject to name that lateralized body part. The examiner then named the same body parts (e.g. left foot) in a different order and asked the patient to point to the named part. Seven different parts were chosen from each side of the body for a total of 14 test items.

Results

The patient correctly named 10/14 body parts and correctly pointed to 12/14 body parts. Chi-square analysis did not reveal a significant difference between naming and pointing ($\chi^2=0.212$, $p=0.648$). Normal controls correctly named a body part in 56/56 total trials and correctly pointed to a body part in 55/56 trials. Chi-square analysis revealed that the patient's accuracy in naming body parts was worse than the normal controls ($\chi^2=16.9$, $p < 0.001$), and that his ability to point to body parts was worse than normal ($\chi^2=4.27$, $p=0.04$). An analysis of the errors shows that the patient made four body part errors and two right-left errors.

Discussion

The results of this experiment need to be interpreted carefully. Normal controls perform almost perfectly so one or two errors on the patient's part can lead to statistically significant differences, whereas a single error on the part of a control subject can lead to non-significant results. With this caveat in mind, the results indicate that our patient's accuracy when naming lateralized (right-left) body parts or pointing to lateralized (right-left) body parts was not the same as normal controls. The patient's accuracy when naming body parts was equivalent to his accuracy when pointing to lateralized body parts. Our patient appears to have more difficulty naming body parts and pointing to named body parts than do normal controls. If our subject's defect was primarily one of verbal labeling, we would have expected naming errors, but no pointing errors. These results suggest that a defect in verbal labeling cannot fully account for the patient's right-left confusion. Although the patient's error rate was less than 10%, he made errors in both naming and pointing to lateralized body parts, suggesting a mildly degraded body schema. The patient's performance, although not perfect, indicates that he has relatively well preserved knowledge about his own right/left orientation.

EXPERIMENT 2

Is Right-Left Confusion Due to a Problem with a Degraded Body Schema?

In experiment 1, the patient made four body part errors and two right-left errors. Since these errors could not be attributed to a defect in verbal labelling, the possibility of a degraded body schema contributing to our patient's right-

left confusion needed to be explored further. According to the body schema theory, the brain contains a representation of the body upon which right/left knowledge is superimposed. Damage to the brain degrades this body schema, resulting in a loss of knowledge about the body. Loss of body knowledge can lead not only to the mislabelling of body parts, but also to right-left errors.

When asked to name parts of our own bodies, we might rely on unique features or landmarks such as scars, moles, or freckles or afferent asymmetries (self cues) to identify a body part without referencing the body schema. Since one cannot use these alternate methods when identifying parts of another person's body, there must be increased reliance on the body schema. Thus, a subject with a degraded body schema should have more problems identifying body parts on another person's body than on his/her own body.

Materials and Methods

The patient was asked to name or point to lateralized body parts on a person standing in front and facing away from him (congruous position). In this position, there is no need for any spatial mapping or rotation in order to identify a body part. By having the patient identify body parts in a physically separate subject, self cuing is avoided. The body parts used in this experiment were the same ones as in Experiment 1. The sequences of body parts were presented in a randomized fashion.

Results

The patient correctly named 12/14 body parts on another person (one body part error and one right/left error) and correctly pointed to 14/14 body parts on another person. Chi-square analyses comparing the patient's ability to name his own body parts and those of a control subject as well as his ability to point out body parts on himself and on a control subject did not reveal any differences (naming: $\chi^2 = 0.848$, $p = 0.36$; pointing: $\chi^2 = 2.15$, $p = 0.142$). Lastly, there was no difference between the patient's ability to name or point to body parts on a control subject ($\chi^2 = 2.15$, $p = 0.142$). Chi-square analysis comparing the patient's accuracy in identifying parts of his own body or those of a control subject by either naming or pointing also failed to demonstrate a difference ($\chi^2 = 2.33$, $p = 0.127$).

Discussion

The performance on this and the prior task suggests that our patient correctly applies knowledge about body parts to someone else's body. The paucity of errors provides further evidence that our patient's body schema is not severely degraded.

EXPERIMENT 3

Does Spatial Rotation Affect Right-Left Orientation?

The patient appeared to have a particularly difficult time when asked to make right-left body part decisions on a subject facing him. According to the body-

centered orientation hypothesis, when one is confronted with an object that has lateralized parts, but is not isomorphic, a spatial transformation is required to bring the object into a body-centered view. This transformation allows the person to make a right/left decision. If the patient failed to spatially rotate an object, we predicted that he would make more errors when presented with an object that required spatial rotation in order to be brought into a body-centered view than when no spatial rotation was required.

Materials and Methods

Using the same technique as the previous experiments, we positioned a control subject in front of and facing our patient (incongruous position). The patient was now asked to name and point to the same 14 body parts as in the previous experiments. His performance in the incongruous position was compared to his performance in the congruous position.

Results

The patient correctly named 5/14 lateralized (right/left) body parts and correctly pointed to 6/14 lateralized (right/left) body parts on the control subject in the incongruous position. An analysis of the errors indicated that they all consisted in right/left or left/right errors, and that there were no body part errors. Chi-square analysis of combined naming and pointing comparing the control-in-congruous position and the control-in-incongruous position demonstrated a significant difference in accuracy ($\chi^2 = 17.9$, $p < 0.001$).

Discussion

The patient demonstrated significant problems identifying and naming lateralized body parts in a task that required spatial mapping and rotation. In the absence of a seriously degraded body schema or a verbal labeling defect, this experiment suggests that our patient has a problem transforming other-body spatial information to a body-centered view. This problem may reflect a general problem with spatial transformations or may indicate a case of defective spatial transformation limited to a particular axis or plane. If a generalized defect in the rotation of mental images were the basis of the patient's problem, we would predict that he would misidentify objects presented in a spatially rotated form.

EXPERIMENT 4

Is Non-canonical Object Recognition Impaired in Right-Left Confusion?

Warrington and Taylor (1973) studied several patients who could identify objects presented in their canonical form (e.g. a length-wise view of an iron), but were unable to identify objects presented in a non-canonical view (e.g. a head-on view of an iron). Since focal brain damage can impair systems involved in the spatial rotation of an object's image, the possibility of just such an impairment in our patient had to be excluded.

Materials and Methods

We presented the patient with black and white pictures of nine common household items in their canonical form. For five of the nine objects, two additional pictures of these items, after rotation within a plane, were also shown. For the remaining four items, a single rotated picture was displayed for a total of nine canonical presentations and 14 non-canonical presentations.

The pictures were presented in a pseudorandomized fashion such that pictures of the same item were never consecutive.

Results

The patient correctly identified 9/9 (100%) canonically presented objects and 12/14 (85.7%) of the non-canonical pictures. Chi-square analysis did not reveal any differences between the items used and their presentation (rotated/canonical) in this task ($\chi^2=0.184$, $p=0.67$). Normal controls (Warrington and James, 1988) can identify 90%-95% of objects presented canonically and 65%-80% of objects presented non-canonically.

Discussion

The patient had no difficulty identifying objects that were presented in a spatially rotated (non-canonical) form. This suggests that the spatial rotation systems that map an object to its canonical form are independent of systems for object-to-body-centered mapping. Although both object- and body-centered rotations may share a common core of functions in spatial mapping systems, the results of this experiment suggest that labeling the lateralized (right-left) portions of an object goes beyond the ability to derive its canonical view.

EXPERIMENT 5

Is Defective Spatial Mapping or Rotation Limited to a Single Axis?

To this point we have determined that our patient has right-left confusion that cannot be accounted for by defective verbal labelling, a degraded body schema or a general mental rotation deficit. The patient's problem seems to be a deficit in mapping lateralized stimuli onto a body-centered view. To learn if his body-centered mapping defect is due to defective rotation through a single axis or occurs on more than one axis, we devised an experimental technique patterned after the one used by Stengel (1944) involving spatial mapping on a limited number of axes.

The technique (see Figure 2) involves the use of three coins, each of which could be moved independently, placed in a straight line, and presented along each axis of space (horizontal, radial and vertical). The initial task required the patient to determine the relative position of one coin (the target coin) to a second coin (the reference coin). For example, along the horizontal axis, the patient would be asked: "Is the nickel to the right or to the left of the quarter?". This

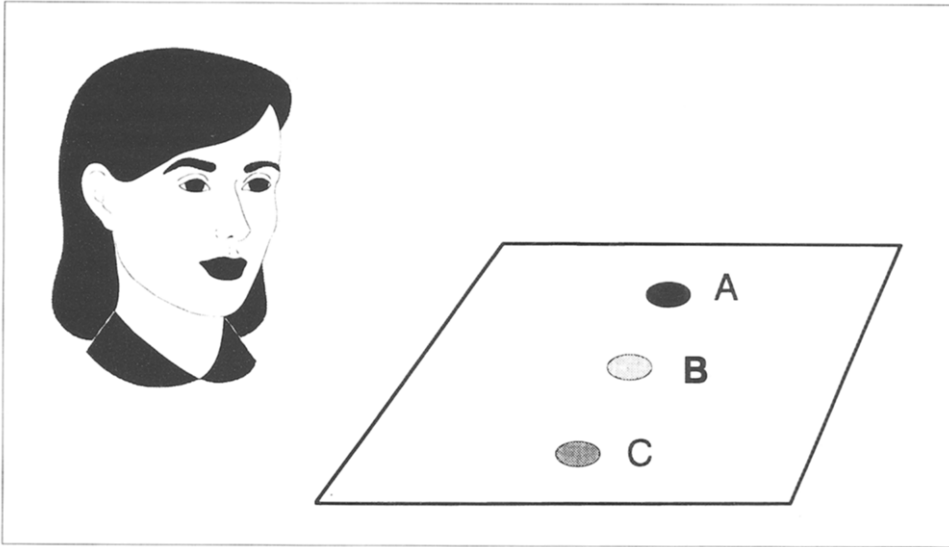


Fig. 2 – The coin task used for spatial rotation. Is coin A to the left or right of coin B?

task was repeated in the radial axis by asking the patient if a coin was closer or farther away from his body than another coin and in the vertical axis by asking the patient if a coin was above or below another coin. If the patient's problem involves multiple axes, then he should have difficulty with a task that requires him to map objects in all axes. Conversely, if the problem is limited to a given axis, then we should see a difference in performance between tasks that involve the affected axis and those that spare the affected axis.

Materials and Methods

A set of three coins (dime, nickel and quarter), placed 5 cm apart on a cardboard were aligned with the patient's horizontal, vertical or radial axis. All combinations of coin positions were presented for a total of 36 trials in each axis. The patient correctly identified the denomination of each coin visually.

Results

The patient correctly named the relative position of the target coin in 31/36 trials along the radial axis, in 27/36 trials along the vertical axis and in 19/36 trials along the horizontal axis. There was a statistically significant difference in the accuracy between the horizontal, radial, and vertical axes ($\chi^2=10.135$, d.f. = 2, $p=0.006$). The accuracy of responses along the radial and the vertical axes were comparable ($\chi^2=1.42$, $p=0.234$). The accuracy of responses along the horizontal axis was significantly worse than along the radial and the vertical axes combined ($\chi^2=9.05$, d.f. = 2, $p < 0.025$).

Discussion

The results of this task indicate that our patient had the most difficulty with tasks that require the discrimination of right-left versus near-far or up-down.

The results indicate a relatively selective difficulty with this task on the horizontal axis compared to either the vertical or the radial axis.

According to the model proposed previously, a defect in this task can arise from three possible sources: horizontal (right-left) spatial representations are defective, leading to a loss of knowledge relating the relative horizontal position of an object to the body. The loss of these representations precludes a comparison between spatially rotated information and a body-centered reference frame. Defective spatial translation or mapping along the horizontal axis would lead to an erroneous comparison to a body-centered reference and cause the mislabelling of parts.

Alternatively, the module that computes this spatially translated information may not be able to access spatial representations and a reliable comparison between spatially translated information and a body-centered reference cannot be made, causing the mislabeling of parts.

EXPERIMENT 6

Does Defective Translation along the Horizontal Axis Contribute to Right-Left Confusion?

In the previous experiment the patient demonstrated a problem deriving the relative position of two coins along the horizontal axis. The task required translating the position of the reference coin to a body-centered view and then determining the direction to the target coin. In an attempt to isolate our patient's spatial mapping defect, our patient was given a simplified version of the coin task.

Materials and Methods

The patient was now given the name of the reference coin and the direction to the target coin. The patient was asked to name the coin in a specific direction from the reference coin ("What is the coin to the right of the quarter?"). This task was carried out for a total of 36 trials. In one third of the trials the reference coin lay along the midsagittal plane, in another third it was to the left and in the last third it was to the right of the midsagittal plane. If the patient has a problem with translation along the horizontal axis, he should do better when the reference coin is in the midsagittal position (no spatial translation required) than when it is to either side.

Results

The patient correctly identified the target coin in 10/12 trials when it was in the midsagittal position, in 4/12 trials when the reference coin was left of center, and in 7/12 trials when it was right of center. Chi-square analysis demonstrates a significant difference among the three conditions ($\chi^2 = 6.17$, d.f. = 2, $p = 0.046$), but cannot identify a difference between the right-of-center and the left-of-center conditions ($\chi^2 = 1.51$, $p = 0.219$). There is a significant difference between the midline and left-of-center condition ($\chi^2 = 6.171$, $p = 0.013$), but not between the midline and right-of-center conditions ($\chi^2 = 1.82$, $p = 0.18$).

Discussion

The patient identified the target coins more accurately when no translation along the horizontal axis was needed than when the reference coin was out of the midsagittal plane and a translation to a body-centered view was required. The results of this experiment suggest that our patient has a deficit in establishing the relative position of an object along the horizontal axis and that our patient's ability to translate the position of an object initially placed left of center is more impaired than when an object is initially placed right of center.

Since the neural computation of the spatial relationship between an object and a person's body is not necessarily based on an Euclidean model of space, the two previous tasks may not have required an explicit mental mapping of an object in a plane. We used a variation of the coin tasks in which the subject was asked to make a radial distance (nearer/further) decision in relation to a non-self reference point. This task forced the patient to perform a mental spatial rotation in order to make a radial distance judgement.

EXPERIMENT 7

Is Impaired Translation Along the Horizontal Axis Associated with Impaired Rotation on the Axial Plane?

If mental spatial rotation in the axial plane involves translation along the horizontal axis, then we would predict that our patient would have difficulty with tasks that involve rotation in the axial plane. However, if our patient used an alternative non-metric approach (Poucet, 1993) for spatial mapping or an alternate plane for mental spatial rotation, then tasks requiring a rotation in the axial plane would be spared.

Materials and Methods

The patient was presented with the same coins as in experiment 5 along the radial axis. In one condition a subject stood opposite the patient and the patient was told to make the near-far decision relative to the control subject's position (eg "Is the nickel closer or further away from the subject than the dime?"). The patient was presented with a total of 18 trials in this condition. In the next condition, the control subject was removed and the patient was told to imagine himself standing opposite himself and to make a near-far decision relative to that imagined position. The patient was presented with 18 trials in this condition.

Results

The patient correctly identified the coin's position in 18/18 trials with the other person's body as the reference position and correctly identified 16/18 target coins when using his imaginary body position as the reference point. The performances on this task were statistically equivalent ($\chi^2=0.53$, $p=0.47$). Furthermore, when the patient's performance using his imaged position as the reference point (16/18) was compared to his performance using his actual

position (31/36), no difference was detected ($\chi^2 = 0.08$, $p = 0.78$).

Discussion

The ability of our patient to accurately make a radial distance decision in a task that was designed to emphasize a spatial rotation in the axial plane was unexpected. However, had our patient rotated the position of the coins through the sagittal plane, he could have avoided the axial plane and its component horizontal axis. Because our patient has problems with spatial mapping along the horizontal axis, we posited that if given the choice between rotating an object in a axial plane or the sagittal plane, our patient would avoid the axial plane.

EXPERIMENT 8

Does the Patient Prefer Rotation in the Sagittal Plane over Rotation in the Axial Plane?

In this task we presented the patient with models of letters that were placed in a position such that their correct orientation could be achieved through either axial or sagittal plane rotations (anagram letter task). We posited that our patient would depend on rotations involving the sagittal plane and in those cases where he used the axial plane, he would make mistakes.

Materials and Methods

The patient was presented with models of letters made from pipe cleaners. The models were presented in a rotated fashion (e.g. ∇ , \wedge , \perp) such that the correct configuration of the letter could be derived by rotation in either the axial or sagittal planes.

Results

The patient was given a total of 12 trials and derived the correct orientation in 11/12 trials. The patient used a sagittal rotation in 7/11 trials, an axial rotation in 3/11 trials and a combination of rotations in 2/11. The single error was made during an attempt to use an axial rotation. Three age-, sex-, handedness- and education-matched controls were given the same task and derived the correct orientation of the letter using an axial rotation in 32/44 trials and using a sagittal rotation in 12/44 trials. Chi-square analysis comparing the number of trials using sagittal rotations revealed a significant difference between the patient and normal controls ($\chi^2 = 5.146$, $p = 0.023$).

Discussion

The patient rotated objects in the sagittal plane more frequently than normal controls. The data in this and the previous experiment suggest that the patient avoids using the axial plane for spatial rotations by using alternate planes of rotation. Since the data also suggest that our patient's right-left confusion

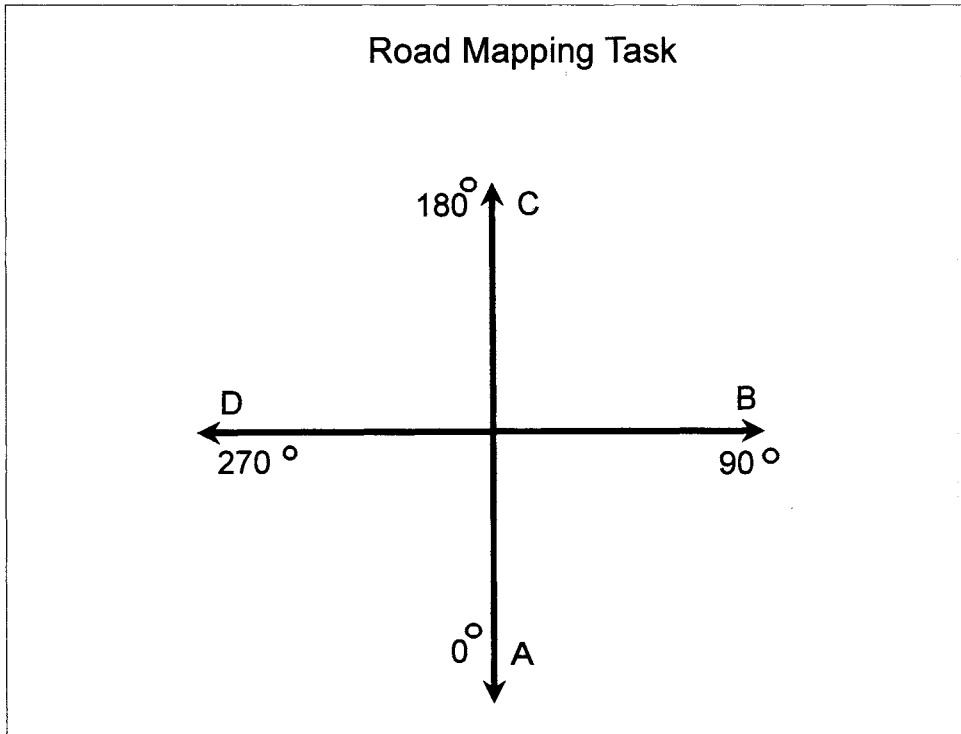


Fig. 3 -- The road mapping task used for spatial rotation. If you are travelling along road B→D, which way should you turn to get to point C?

involves a defect establishing the relative position of an object along the horizontal axis, we devised a task that required a rotation in the axial plane while also constraining the patient from using alternate planes of rotation.

EXPERIMENT 9

Is Mental Rotation in the Axial Plane Defective?

The technique in this experiment uses an idealized four-way 90° intersection created by printing two perpendicular lines on an 8 1/2" × 11" piece of paper (see Figure 3). The end of each line segment was labelled with a letter (A-B, C-D). The paper was placed on the axial plane such that, from a body-centered view, one line lay along the mid-sagittal plane and the second line lay along the coronal plane. For each trial the patient was told to imagine himself "travelling" along a road (eg point A to point B). He was then asked which way he should turn (right or left) to reach point (B or D) when he reached the crossroads. By selecting different starting points, the patient was presented with trials that had 0, 90, 180 and 270 degrees of counter-clockwise rotation from a body-centered point of view. The intersection was presented in the same

perspective in each trial. This task allowed us to measure the effect of different degrees of rotation on our patient's ability to make a right-left decision. The intersecting figure precluded the patient from using a rotation in the sagittal plane to solve this task. If spatial mapping in the axial plane is defective then conditions with any degree of rotation (90, 180, 270) should be defective when compared to a condition with no rotation (0). If the effort required for mental rotation is related to the degree of rotation (Shepard and Metzler, 1971), then our patient's accuracy should decrease as conditions increase in their degrees of rotation.

Materials and Methods

The patient was presented with all possible combinations of road and end-points for a total of 36 trials. This task presented him with conditions with 0, 90, 180 and 270 degrees of counter-clockwise rotation from a body-centered point of view. The patient was told along which line segment he was to imagine himself travelling. He was then asked to name the direction (right/left) he should turn to reach a given target point when he reached the intersection of the two line segments.

Results

The patient chose the correct direction of movement 11/12 times with 0° of rotation (body centered view), 6/12 times with a rotation of 90°, 4/12 times with a 180° rotation and 2/12 times with a rotation of 270°. Chi-square analysis comparing the number of correct decisions between the three conditions with spatial rotation (non-body centered) failed to reveal a significant difference between conditions with rotation of 90, 180 and 270 degrees ($\chi^2 = 3.00$, d.f. = 2, $p = 0.223$). A second Chi-square analysis comparing the number of correct decisions in the body-centered condition with non-body-centered conditions revealed a significant difference ($\chi^2 = 12.75$, $p < 0.001$).

Discussion

When our patient was given a task that emphasized spatial mapping or rotation in the axial plane, he performed significantly better when no rotation was required when compared to the three conditions requiring rotation. A comparison between various degrees of rotation (90, 180, 270) failed to reveal a significant difference; however, our patient's performance consistently deteriorated as more clockwise rotation was required to bring the intersection into a body-centered view. The combination of a clear effect of any rotation along the axial plane and the implied effect of the degree of rotation suggest that either spatial rotations systems responsible for mapping positions along the horizontal axis or its output are defective.

GENERAL DISCUSSION

We systematically approached the analysis of right-left confusion in a patient with Gerstmann's syndrome. A comparison of his ability to name or point to

a lateralized body part indicates that the use of verbal labels such as "left" and "right" or "east" and "west" is not defective. A comparison of his ability to name body parts on his own body versus that of another person without requiring any spatial rotation indicates that the patient does not have a severely degraded body schema. However, when a task requires the patient to name body parts on a person facing him, his poor performance indicates that he has a problem with the mental operations required to deal with the relative nature of right/left, such as spatial mappings or rotations.

The nature of this clinical defect was further investigated by carrying out a task that tested the patient's ability to establish a body-centered view and derive the relative position of two objects along different axes of space. The results of this task demonstrate that our patient has a problem limited to translation along the horizontal axis. A simpler form of this task in which the patient needed to establish the relative position of a single object confirmed the problem with translation along the horizontal axis.

The isolated deficit in horizontal translation suggests that the systems mediating translation along the horizontal axis may be especially vulnerable to brain damage. Some of the features of the neural systems that embody horizontal representations or horizontal spatial transformations that might make them more susceptible to brain damage include late development and the lack of a constant physical reference such as gravity. Lateral orientation for one's own body (self-body right/left knowledge) appears to be reasonably well established in children by age eight, identification of crossed-over body parts by age nine and complete right-left orientation by age eleven (Clark and Klonoff, 1990; Benton and Sivan, 1993). Since the acquisition of right-left orientation appears after children are able to use propositional language, right-left confusion in children cannot be accounted for by language deficits. The hypothesis that the neural systems involved in determining other-body knowledge, which is dependent on spatial rotation, may be more susceptible to brain damage is supported by the fact that patients with Alzheimer's disease have more difficulty identifying the lateralized parts when they have to make a spatial rotation (Marterer and Danielczyk, 1990). Additional evidence for this hypothesis comes from Stengel's (1994) report of a patient with Gerstmann's syndrome whose right-left orientation was profoundly impaired but had relative sparing of vertical orientation.

We gave our patient a task that seemed to require a rotation along the axial plane. However, when our patient performed normally, we realized that an alternate plane of rotation (sagittal plane) could have led to a normal performance. To test our patient's use of alternate planes of rotation, we gave our patient an anagram letter task in which a letter was presented in a rotated form and could be corrected by rotation through either the axial or the sagittal plane. The patient opted for sagittal plane rotations more frequently than normal control subjects and avoided rotations that involved the horizontal axis.

To prevent the subject from using alternative planes of rotation, we gave our patient a road mapping task that required him to make a right/left decision after having to perform an axial rotation of 0, 90, 180 or 270 degrees of clockwise or counter-clockwise rotation. The results of this task indicate that under any condition requiring an axial rotation, our patients' performance was

defective. The application of our model to the other components of Gerstmann's syndrome may elucidate a common mechanism. Stengel (1944) suggested that finger agnosia was due to an inability to identify the position of a finger among its fellows. Critchley (1966) reported that the index and middle fingers are the most commonly misnamed fingers in patients with Gerstmann's syndrome. Dinsbourne and Warrington's (1962) detailed study of finger agnosia in a group of patients with Gerstmann's syndrome demonstrated that all the patients had problems with tasks that required the determination of the relative position of one finger to another one. Identifying a finger may involve determining its relative horizontal position within the hand. A defect in horizontal translation could affect all the fingers, but would be predicted to affect the middle digits more.

We conclude that a defect in horizontal translation accounted for the right-left disorientation in our patient. Although we did not test our hypothesis on the other features of the syndrome, the spatial features of mathematical operations and the fact that these operations are defective in Gerstmann's syndrome (Levin, Goldstein and Spiers, 1993; Critchley, 1953) invites the application of our model to a patient with Gerstmann's syndrome.

REFERENCES

- ARMY INDIVIDUAL TEST BATTERY. *Manual of Directions and Scoring*. Washington, D.C.: War Department, Adjutant General's Office, 1944.
- BENSON, D.F., CUMMINGS, J.L., and TSAI, S.Y. Angular Gyrus syndrome simulating Alzheimer's Disease. *Archives of Neurology*, 20: 616-620, 1982.
- BENTON, A.L. *Right-left Discrimination and Finger Localization: Development and Pathology*. New York: Hoeber-Harper, 1959.
- BENTON, A.L. The Fiction of the Gerstmann Syndrome. *Journal of Neurology, Neurosurgery and Psychiatry*, 24: 176-181, 1961.
- BENTON, A.L. Reflections on the Gerstmann's Syndrome. *Brain and Language*, 4: 45-62, 1977.
- BENTON, A.L., and HAMSHER, K. DE S. *Multilingual Aphasia Examination*. Iowa City: University of Iowa, 1976 (revised 1878).
- BENTON, A.L., and SIVAN, A.B. Disturbances of the body schema. In K.M. Heilman and E. Valenstein (Eds.), *Clinical Neuropsychology*, 3rd ed. New York: Oxford University Press, 1933, Ch. 6, pp. 123-140.
- BERG, E.A. A simple objective test for measuring flexibility in thinking. *Journal of General Psychology*, 39: 15-22, 1948.
- CHERTKOW, H., and BUB, D. Semantic memory loss in dementia of Alzheimer's type. What do the various measures measure? *Brain*, 113: 397-417, 1990.
- CLARK, C.M., and KLONOFF, H. Right and left orientation in children aged 5 to 13 years. *Journal of Clinical and Experimental Neuropsychology*, 12: 459-466, 1990.
- CRITCHLEY, M. *The Parietal Lobes*. London: Arnold, 1953.
- CRITCHLEY, M. The enigma of Gerstmann's Syndrome. *Brain*, 89: 186-198, 1966.
- DANIEL, W.W. *Applied Nonparametric Statistics: Second Edition*. Boston: PWS-Kent Publishing Company, 1990.
- DELIS, D.C., KRAMER, J.H., KAPLAN, E., and OBER, B.A. *California Verbal Learning Test: Research Edition*. New York: The Psychological Corporation, 1983.
- FISHER, P., MARTERER, A., and DANIELCZYK, W. Right-left disorientation in dementia of the Alzheimer's type. *Neurology*, 40: 1619-1620, 1990.
- GERSTMANN, J. Fingeragnosie eine umschriebene Störung der Orientierung am eigener Körper. *Wiener klinische Wochenschrift*, 37: 1010-1012, 1924.
- GERSTMANN, J. Zur Symptomatologie der Hirnlesionen im Uebergangsgebiet der unteren Parietal- und mittlerem Occipitalwindung. *Nervenarzt*, 3: 691-695, 1930.
- GRAFMAN, J., PASSAFIUME, D., FAGLIONI, P., and BOLLER, F. Calculation disturbances in adults with focal hemispheric damage. *Cortex*, 18: 37-50, 1982.

- HEAD, H. *Aphasia and Kindred Disorders and Speech*. Cambridge, England: The University Press, 1926.
- HÉCAEN, H. *Introduction à la Neuropsychologie*. Paris: Larousse, 1972.
- HEILMAN, K.M., WATSON, R.T., and VALENSTEIN, E. Neglect and related disorders. In K.M. Heilman and E. Valenstein (Eds.), *Clinical Neuropsychology*, 3rd edition. New York: Oxford University Press, 1993, Ch. 10, pp. 279-336.
- HEIMBURGER, R.F., DEMYER, W.C., and REITAN, R.M. Implications of Gertsman's syndrome. *Journal of Neurology, Neurosurgery and Psychiatry*, 27: 52-57, 1964.
- KAPLAN, E., GOODGLASS, H., and WEINTRAUB, S. *The Boston Naming Test*. Lea and Febiger, Philadelphia, 1983.
- KERTESZ A. *Aphasia and Associated Disorders*. New York: Grune and Stratton, 1979.
- KINSBOURNE, M., and WARRINGTON, E.K. A study of finger agnosia. *Brain*, 85: 47-66, 1962.
- LEVIN, H.S., GOLDSTEIN, F.C., and SPIERS, P.A. Acaculia. In K.M. Heilman and E. Valenstein (Eds.), *Clinical Neuropsychology*, 3rd ed. New York: Oxford University Press, 1993, Ch. 5, pp. 95-122.
- MENNEMEIER, M., CHATTERJEE, A., and HEILMAN, K.M. A comparison of the influences of body and environment centered reference frames on neglect. *Brain*, 117: 1013-1021, 1994.
- MONEY, J. *A Standardized Road Map of Direction Sense*. San Rafael, CA: Academic Therapy Publications, 1976.
- POUCET, B. Spatial cognitive maps in animals: New hypotheses on their structure and neural mechanisms. *Psychological Review*, 100: 163-182, 1993.
- SHEPARD, R.N., and METZLER, J. Mental rotation of three-dimensional objects. *Science*, 171: 701-703, 1971.
- STENGEL, E. Loss of spatial orientation, constructional apraxia and Gerstmann's Syndrome. *Journal of Mental Sciences*, 90: 753-760, 1944.
- TRAHAN, D.E., and LARRABEE, G.J. *Continuous Visual Memory Test*. Odessa, FL: Psychological Assessment Resources Inc., 1983.
- WARRINGTON, E.K., and JAMES, M. Visual apperceptive agnosia: A clinico-anatomical study of three cases. *Cortex*, 24: 13-32, 1988.
- WARRINGTON, E.K., and TAYLOR, A.M. The contribution of the right parietal lobe to object recognition. *Cortex*, 9: 152-165, 1973.
- WECHSLER, D. *Wechsler Adult Intelligence Scale - Revised. Manual*. New York: The Psychological Corporation, 1981.
- WEISKRANTZ, L., and SAUNDERS, R.C. Impairments of visual object transforms in monkeys. *Brain*, 107: 1033-1072, 1984.