

curriculum" (that perfidious vehicle of current undergraduate and continuing medical education programs). Moreover, as the antics of recent world championship chess matches have vividly displayed, the royal game is far from "clean, elegant, intellectual, and knowable." Rather it is dirty, political, chaotic, and unpredictable. In other words, like life, war, and medicine, chess is a mess.

CHARLES L. WITTE, MD
University of Arizona
College of Medicine
Tucson

To the Editor.—I read with great interest the letter on "Chess and the Computer." How ironic that Dr Diosy was not aware that David Levy, the international chess master from Scotland, recently defeated a computer programmed by American experts and that he won his wagers of \$1,000 and £500 on this issue.¹

I cannot but agree with William H. Crosby, MD, that "the algorithm, like chess, is clean, elegant, intellectual, and knowable. On the other hand, life is a mess and so is the practice of medicine."

MARSHALL E. DEUTSCH, PhD
Thyroid Diagnostics Inc
Bedford, Mass

1. Levy beats chess-playing computer. *New Scientist* 79:751, 1978.

Syndrome of Inappropriate Antidiuretic Hormone Secretion Associated With Amitriptyline Administration

To the Editor.—Hyponatremia and the syndrome of inappropriate antidiuretic secretion (SIADH) have been associated with the administration of a number of medications. We would like to add our case report to that of Luzecky et al,¹ who first reported the association of SIADH with the administration of amitriptyline.

Report of a Case.—A 51-year-old woman was treated for depression with amitriptyline hydrochloride, 50 mg three times per day. She was otherwise in good health and was receiving no other medications. Six weeks after starting the amitriptyline treatment, she was found in her home in a comatose state. Shortly after admission to the hospital, she had a generalized tonic-clonic seizure. There had been no history of excessive water intake noted by the family. The patient was said to have behaved normally on the morning of her admission. Physical examination was unremarkable, except for conspicuous lethargy. There was no evidence of dehydration. She was treated for possible amitriptyline intoxication with endotracheal intubation, gastric lavage, and intravenous physostigmine.

Admission laboratory workup disclosed the following values: serum sodium, 114 mEq/L; potassium, 2.9 mEq/L; chloride, 81 mEq/L; creatinine, 0.7 mg/dL; and serum osmolality, 220 mOsm/L. Urinary studies showed the following values: sodium, 79 mEq/L; potassium, 25 mEq/L; and osmolality, 339 mOsm/L. The patient was treated with fluid restriction, withdrawal of amitriptyline, and intravenous potassium supplementation; she had an uneventful recovery, regaining full consciousness by 24 hours. During the first 24-hour period, there was a net diuresis of 2.7 L. When the patient became alert, she recalled drinking a little more than usual on the day of admission and estimated the amount to be approximately 2 L. Within 24 hours after admission, her serum sodium level had risen to 128 mEq/L, with a serum osmolality value of 252 mOsm/L. At 72 hours after admission, her serum sodium level had risen to 141 mEq/L, with a serum osmolality value of 286 mOsm/L.

Amitriptyline levels were determined at the time of admission and the morning following admission and were within the therapeutic range. Neurological evaluation was normal. The patient was not rechallenged with amitriptyline.

Comment.—We think this patient fulfills the criteria for the diagnosis of SIADH in that she had hypotonicity of the extracellular fluid with low serum sodium level, inappropriately elevated urine osmolality and sodium values, and no evidence of dehydration, liver disease, renal disease, or cardiovascular disorder.

Medications containing the tricyclic structure, including antidepressants, phenothiazines, and carbamazepine (a tricyclic anticonvulsant), have been associated with hyponatremia. In the severely psychotic person, hyponatremia associated with the administration of medications does not necessarily mean that SIADH is the underlying cause. Thioridazine has been frequently associated with hyponatremia secondary to excessive water consumption and dilutional hyponatremia. Thioridazine may cause excessive thirst by two mechanisms, and this may contribute to excessive water consumption. First, thioridazine has an anticholinergic effect, common to most tricyclic compounds, which causes a dry mouth. Second, thioridazine may stimulate CNS thirst centers. More recently thioridazine has been associated with SIADH in at least two case reports.^{2,3} Fluphenazine has also been reported to be associated with SIADH.⁴

To our knowledge, amitriptyline is the only tricyclic antidepressant that has been associated with SIADH. Carbamazepine, the structure of which closely resembles imipramine, has been frequently associated with

SIADH, but no reports of an association of SIADH with imipramine exist.⁵ The mechanism by which tricyclic compounds affect antidiuretic hormone secretion and action is unknown.

Because of the increasing frequency with which SIADH has been reported to be associated with the administration of tricyclic compounds, it is incumbent on the physician who cares for patients receiving these medications to be aware that changes in mental status and neurological symptoms such as seizures and coma may be due to hyponatremia.

DWIGHT BECKSTROM, MD
RICK REDING, MD
JAMES CERLETTY, MD
Medical College of Wisconsin
Milwaukee County Medical Complex
Milwaukee

1. Luzecky MH, Berman KD, Schultz ER: The syndrome of inappropriate secretion of antidiuretic hormone associated with amitriptyline administration. *South Med J* 67:495-497, 1974.

2. Matuk F, Kalyanaraman K: Syndrome of inappropriate secretion of antidiuretic hormone in patients treated with psychotherapeutic drugs. *Arch Neurol* 34:374-375, 1977.

3. Vincent FM, Emery S: Antidiuretic hormone syndrome and thioridazine. *Ann Intern Med* 89:147-148, 1978.

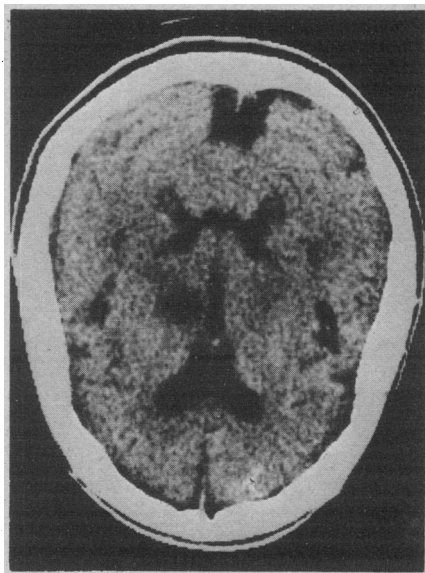
4. DeRivera JLG: Inappropriate secretion of antidiuretic hormone from fluphenazine therapy. *Ann Intern Med* 82:811-812, 1975.

5. Flegel KM, Cole CH: Inappropriate antidiuresis during carbamazepine treatment. *Ann Intern Med* 87:722-723, 1977.

Unilateral Asterixis

To the Editor.—Ericson et al (240:671, 1978) described a dialysis patient with unilateral internal carotid artery stenosis manifested by contralateral hemiparesis, plantar extensor response, and, most remarkably, contralateral asterixis fluctuating in intensity with systemic blood pres-

Radiolucent area in anterior portion of posterior limb of internal capsule on right.



sure and abating with endarterectomy. They pointed out that bilateral asterixis may be a sign of global encephalopathy whereas unilateral asterixis indicates contralateral hemispheric dysfunction. We would like to contribute a case of subcortical infarction manifested by unilateral asterixis coupled with mild hemiparesis.

Report of a Case.—An 83-year-old woman was in good health until 24 hours before admission when she noted sudden light-headedness and left-sided weakness. She was brought to the hospital where neurological examination showed normal mental status, fluent speech, and mild left-sided face and arm weakness. Sensory examination was normal. Reflexes were increased on the left, and asterixis was present as well.

A blood chemistry study using an automated multiple analysis system was normal. Computerized tomography showed an infarct involving the genu and anterior part of the posterior limb of the internal capsule and surrounding thalamus on the right (Figure).

Comment.—In this case a discrete capsular lesion gave rise to unilateral asterixis and mild hemiparesis. This certainly supports the concept of unilateral asterixis suggesting focal disease.^{1,3}

E. WAYNE MASSEY, MD
J. CLAY GOODMAN, MD
National Naval Medical Center
Bethesda, Md

1. Young RR, Shahani BT: A new sign of minimal motor dysfunction. *J Postgrad Med* 21:18, 1975.
2. Young RR, Shahani BT, Kjellberg RJ: Unilateral asterixis produced by a discrete CNS lesion. *Trans Am Neurol Assoc* 101:306-307, 1976.
3. Tarsy D, Lieberman B, Chirico-Post J, et al: Unilateral asterixis associated with a mesencephalic syndrome. *Arch Neurol* 34:446-447, 1977.

Management of Spontaneous Esophageal Rupture

To the Editor.—In addition to provoking less fanciful observations, THE JOURNAL article "Nonsurgical Management of Spontaneous Esophageal Perforation" (240:140, 1978) conjures up a vision of George Santayana strolling the Elysian fields with Hermann Boerhaave and consoling him because the lessons of history¹ are so often ignored. Although this is a defect of the human condition to which I too am prone, nevertheless the article raises substantive questions about patient care that warrant discussion.

In the first place—a trap for those who have time only to scan titles—the crux of this patient's successful management was closed thoracotomy with tube drainage of the empyema, a procedure that hardly qualifies as nonsurgical. Furthermore, unex-

plained bilateral pleural effusion in a patient who vomited after a big meal and then had development of chest pain, dyspnea, and fever might reasonably suggest ruptured esophagus. The various laboratory studies done on both effusions would cost \$66 in my hospital and did not prove helpful. On the other hand, simple measurement of the pleural fluid pH with test paper might have established the diagnosis more promptly and for a pittance.² Again, abdominal pain and the absence of shock and of mediastinal air were considered to obscure the diagnosis. In point of fact—as I have learned (and relearned) to my personal chagrin—this situation is not uncommon except with the classic catastrophic ruptures. And the hazards attending the uncritical use of numbers are clearly shown in the survival data cited: 45% of patients treated with esophageal repair survived compared with 52% of those treated with chest drainage alone. Does this mean that drainage is preferable to repair? Finally, the Celestin tube has proved a valuable tool in the management of tardily diagnosed esophageal rupture,³ and its use might well have been considered in the present instance.

EUGENE G. LAFORET, MD
Newton-Wellesley Hospital
Newton Lower Falls, Mass

1. Derbes VJ, Mitchell RE Jr: Hermann Boerhaave's *Atrocis, nec Descripti Prius, Morbi Historia*: The first translation of the classic case report of rupture of the esophagus, with annotations. *Bull Med Libr Assoc* 43:217-240, 1955.
2. Dye RA, Laforet EG: Esophageal rupture: Diagnosis by pleural fluid pH. *Chest* 66:454-456, 1974.
3. Berger RL, Donato AT: Treatment of esophageal disruption by intubation: A new method of management. *Ann Thorac Surg* 13:27-35, 1972.

In Reply.—We offer the following response to Dr Laforet. First, the literature pertaining to Boerhaave's syndrome is often confusing with respect to the term "surgical." Many authors define this as operative repair of the esophagus, while others define it as chest-tube drainage even without surgery. As indicated in our first paragraph, we think that chest-tube drainage is, in the broadest sense, "surgical," although our title was worded specifically to emphasize the nonoperative aspect of management in this case. Second, we agree that pleural fluid pH measurement may be useful. However, it certainly would not have obviated the other pleural fluid studies. Third, as stated, an important source of confusion in the diagnosis in this case was the variability of the location of the patient's pain, possibly attributable to the patient's behavioral disorder. The absence of shock and mediastinal

air and the presence of intermittent complaints of right lower quadrant pain diverted our attention from the correct diagnosis for four days. Finally, the data in question were chosen to demonstrate that chest drainage, with or without esophageal repair, is unequivocally beneficial. As we note, drainage without repair is preferable only when esophageal rupture is diagnosed late in a stable patient.

ROBERT H. BROWN, JR, MD, DPHIL
PAUL S. COHEN, MD
Boston

Venipuncture and Cardiac Arrest

To the Editor.—I endorse all of the comments of Reuben Tizes, MD, on the subject of cardiac arrest occurring during venipuncture (240:213, 1978), as I had the misfortune of witnessing one myself recently. The patient was one of our own laboratory technicians who had given blood on several occasions as a control in various studies in our department. He insisted that he give the blood lying on a couch, since he is extremely prone to fainting. While drawing blood he said to me that he was "fainting" and that I should terminate the phlebotomy. I did not withdraw the needle but stopped drawing on the plunger in the hope that the fainting episode would subside in a few seconds and I would be able to resume the procedure. However, as he looked extremely pale, I felt his pulse and detected extreme bradycardia (approximately 20 beats per minute, although an exact counting was not done as things evolved rather rapidly). Within a few seconds, he turned his head to the side and stared vacantly toward the right side and was nonresponsive. At this point he had no pulse, and I immediately withdrew the needle. I gave him two successive thumps over the precordium. When this did not revert the rhythm, I started external cardiac massage, after which measure the pulse resumed at a slow pace. At this point he was also apneic, and I proceeded with mouth-to-mouth breathing. Shortly afterward his breathing also resumed. Urinary incontinence was also noted.

My impression was that this subject had sustained a Adams-Stokes attack in view of the facts that he exhibited signs of cerebral anoxia and had been pulseless for a brief period. As I had no means of monitoring his heart rate, I can only assume that he had either a cardiac asystole or an