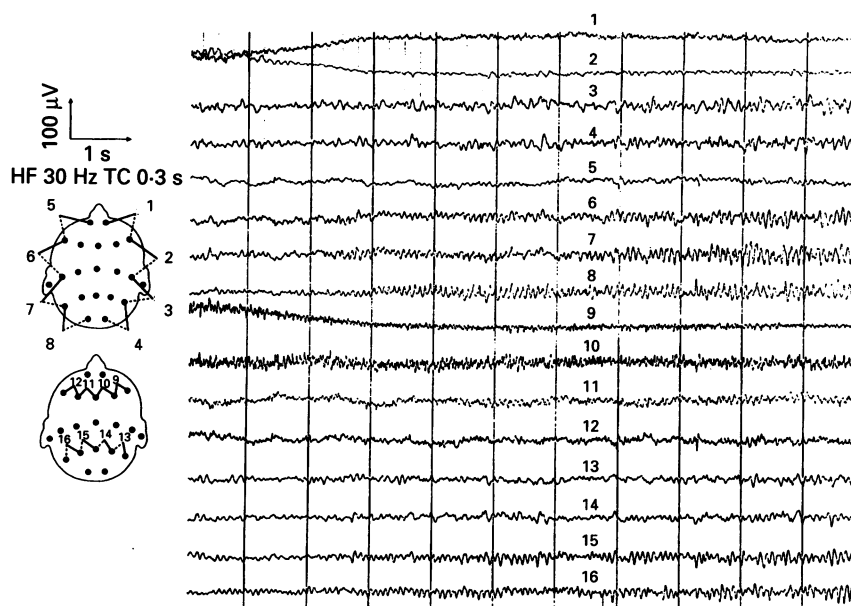

EEG showing seizure discharge evolving over a wide distribution over the left hemisphere with rhythmic activity at 12 Hz and up to 70 µV. The right hemisphere shows alpha rhythm with superimposed slower rhythms and no seizure activity.

Initially these were subtle; nystagmus to the right and twitching of his right index finger but more gross movements of his arm supervened. At no stage was there a generalised convulsion. Addition of other anticonvulsants caused increasing drowsiness without clear benefit and these were subsequently withdrawn. Five weeks after the onset, his speech started to return and within seven days he was coherent with good short and long term memory. Epilepsy and diabetes were well controlled six months later with phenytoin and oral hypoglycaemic agents and repeat SPECT showed resolution of the blood flow abnormalities.

The EEG findings, absence of a structural lesion or markers of encephalitis, and ultimate recovery suggest his clinical state was due to recurrent focal seizure activity. When focal status epilepticus presents with motor symptoms, the diagnosis is straightforward. In this case, the initial lack of motor accompaniment, the focal nature of the deficit without obvious global confusion, and its progressive course without fluctuation, were all unusual. The progressive clinical picture, with intermittent scalp EEG seizure activity, may have been due to more continuous seizure activity in deeper structures, not manifest at the scalp, or else an increasingly severe Todd's phenomenon, affecting speech, from frequent seizures.

We have found only seven previous reports of aphasic status epilepticus in adults.^{1,2} Two had recognised epileptogenic focal lesions of the left hemisphere and two others were diabetic. In one of these, blood sugar was 23 mmol/l at the time of presentation,² although this association was not emphasised in the report and the patient, who was aphasic for 12 days, also had no other identifiable cause.

Focal motor seizures and epilepsy partialis continua may occur in up to 25% of patients with non-ketotic hyperglycaemia, unlike the generalised seizures associated with most metabolic derangements. In the

largest series, this was the first presentation of diabetes in nine of 21 patients; seizures occurred at glucose concentrations as low as 15 mmol/l.³ An appropriately sited lesion was seen in 13 of these cases, by contrast with the generalised atrophy without focal change seen on CT in our patient. In these cases too, the seizures lasted for one to four weeks, then remitted, without any clear relation to glycaemic control or anticonvulsants. The reason for this lag of clinical resolution behind metabolic correction is not clear; it seems to exceed the usual delay in dysequilibrium syndromes.

The hyperosmolarity of hyperglycaemia can itself cause infarction and regional reduction of cerebral blood flow in rats.⁴ The SPECT findings in this case would be consistent with this, although the confounding effect of the seizures themselves on cerebral blood flow cannot be excluded. Seizures may be triggered by hyperglycaemia in the cat's occipital cortex rendered irritable by local penicillin treatment.⁵ A potential mechanism is, therefore, the hyperosmolar irritation of neurons rendered ischaemic by an enhanced tendency to vascular disease and by an acute reduction in cerebral blood flow secondary to hyperglycaemia and dehydration.

We thank Dr Rudolph for his help in interpretation of the EEG recordings, and Dr Z Zhang and Dr K Nijram for interpreting the SPECT studies.

M MANFORD
Wessex Neurological Centre,
Southampton General Hospital,
Tremona Road,
Southampton SO16 6YD, UK
G N FULLER
Gloucestershire Royal Hospital,
Great Western Road,
Gloucester GL1 3NN, UK
J P H WADE
Academic department of Neuroscience,
Charing Cross Hospital,
Fulham Palace Road,
London
W6 8RF, UK

Correspondence to: Dr M Manford

- 1 Knight RT, Cooper J. Status epilepticus manifesting as Wernicke's aphasia. *Epilepsia* 1986;27:301-3.
- 2 Dinner DS, Lueders H, Lederman R, Gretter TE. Aphasic status epilepticus: a case report. *Neurology* 1981;31:888-90.
- 3 Singh BM, Strobos RJ. Epilepsia partialis continua associated with nonketotic hyperglycemia: clinical and biochemical profile of 21 patients. *Ann Neurol* 1980;8:155-60.
- 4 Duckrow RB, Beard DC, Brennan RW. Regional cerebral blood flow decreases during hyperglycemia. *Ann Neurol* 1985;17:267-72.
- 5 Vastola EF, Maccario M, Homan R. Activation of epileptogenic foci by hyperosmolality. *Neurology* 1967;17:520-6.

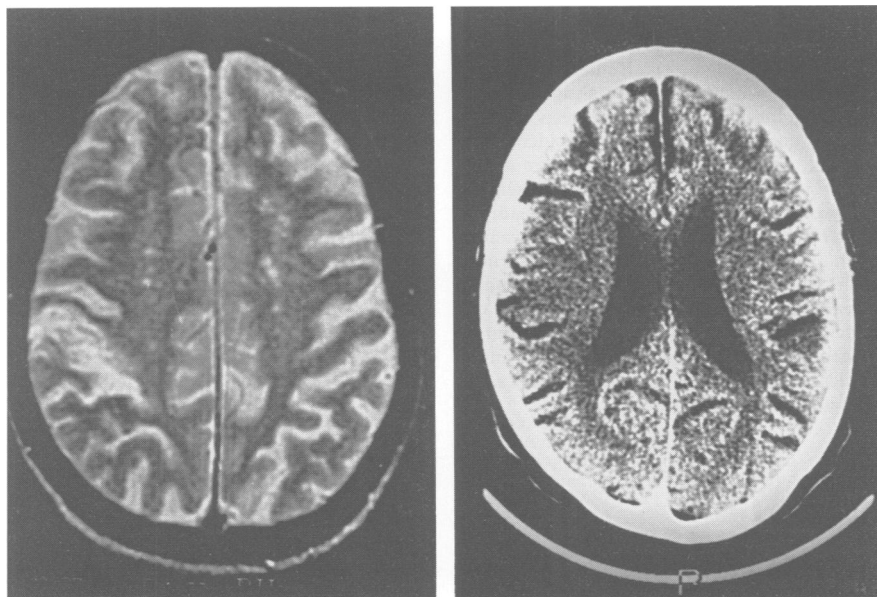
Alien hand sign or alien hand syndrome?

A precise definition of the alien hand syndrome does not yet exist. Classic descriptions comprise three or four hallmarks: (a) a feeling of foreignness of the limb, (b) failure to recognise ownership of it when visual clues are removed, (c) autonomous motor activities that are perceived as involuntary and are different from other identifiable movement disorders, and (d) personification of the affected body part.^{1,2}

The combination of lesions necessary to produce this phenomenon is not certain. Traditional studies showed that damage to the bifrontal cortex, lesions of the anterior corpus callosum alone, or combinations of frontal and callosal lesions were most often involved.^{3,4} Nevertheless, several cases of alien hand syndrome with different neuropathological findings are raising new hypotheses.^{1,5,6}

Our patient had an alien hand syndrome after a lesion in an unusual site. An 80 year old, right handed man complained of strange involuntary movements of his left hand. He was a retired pianist with a history of chronic obstructive pulmonary disease, hypertrophic cardiomyopathy, and acute myocardial infarction 17 years previously. He did not complain of any past neurological condition. He was well until the morning of admission when he was suddenly woken by "insistent touching of his neck and face". As he was living alone, he was frightened by the thought of "someone breaking into the house", and was puzzled when he realised that it was his own left hand that was scratching him. When attempting to wash and dress himself, he had serious difficulties due to the interference of his left hand, which could not be restrained from grasping his razor or unbuttoning his clothing.

The patient was fully alert and oriented, and general physical examination was unremarkable. There was no disturbance of language. He was unable to reach objects with his left hand under visual control. The cranial nerves were otherwise intact. Motor function was normal although there was a mild left hypaesthesia, and tactile neglect. He was unable to distinguish his limb from the examiner's or to recognise objects with his left hand when visual clues were absent. He was unaware of the location of his left arm. He displayed some non-goal directed activities such as scratching and raising his left hand, which he perceived as imposed and uncontrollable. These autonomous movements were sometimes triggered by movement of the right hand. There was also enormous difficulty in bimanual coordination tasks, such as taking off his glasses.



(A) Sagittal T2 MRI showing a cortical infarct in the right parietal region; (B) CT showing an old cortical infarct in the left parietal region.

Brain CT without contrast showed an old cortical infarct in the left parietal region. Magnetic resonance imaging on the 12th day showed a recent cortical infarct in the high right parietal region, and cortical atrophy localised in the left parietal region, without evidence of callosal lesions. A SPECT examination performed on the 10th day showed a left parietal perfusion deficit with hyperperfusion on the right parietal region. The patient was treated with ticlopidine from the first day; the abnormal motor behaviour as well as the foreign limb sensation gradually disappeared after the first week, but the loss of visual guidance of the affected limb and loss of sensation still persisted on discharge.

The phenomenon that one hand behaves independently of the patient's will was first described by Goldstein³ in 1908, while studying patients with callosal lesions. Since that initial report, several authors have described similar sensorimotor behaviour in association with lesions involving the corpus callosum, the mesial frontal lobes (cingulate gyrus and supplementary motor areas), combinations of both, or bifrontal lesions.⁴ Despite all these clinical descriptions, no unifying criteria were set for the "alien hand syndrome" or "alien hand sign" (depending on the authors). Aetiological theories all have in common some notion of disconnection (right from left, or sensory from motor) and some notion of released inhibition affecting activities of the alien hand.² Feinberg *et al.*⁵ suggested that alien hand syndrome was in fact two different entities, both from a clinical and anatomical perspective: a frontal alien hand syndrome and a callosal alien hand syndrome. The first type would result from damage in the supplementary motor areas, anterior cingulate gyrus and medial prefrontal cortex of the dominant hemisphere, and anterior corpus callosum, and would be clinically related to reflexive grasping and compulsive manipulation. The callosal type would be characterised primarily by intermanual conflict and requires only an anterior corpus callosum lesion.

More recently, alien limbs have also been described with other underlying pathology, such as corticobasal degeneration, and central sensory nuclei (thalamic), occipitoparietal, and internal capsule lesions.^{1,6} In all the described cases, callosal, thalamic, or internal capsule lesions, added to cortical lesions were required. Doody *et al.*¹ suggest that, alternatively, a large posterior infarct alone may be sufficient to give an alien hand syndrome, although this has never been reported. The clinical picture of these cases also fulfilled the criteria of the feeling of foreignness and autonomous movements seen in classic descriptions. Nevertheless, they also displayed other associated features such as cortical myoclonus, abnormal sensory functions, loss of visual guidance of the affected limb (optic ataxia), or movement disorders.

In our patient, the feeling of strangeness and imposed involuntary movements, together with the inability to recognise his hand without visual clues, gave the picture of alien hand syndrome. There was no evidence of any frontal, callosal, thalamic or internal capsule lesions. We think that in our case, bilateral dorsoparieto-occipital lesions interfere with peristriate outflow pathways toward parietal zones, where visual-somatosensory interactions are likely to occur. When bilateral, and in this specific case, synchronous, these lesions could explain the right parietal syndrome together with the loss of visual guidance of the affected limb, that can also result in an alien hand syndrome. Epidemiological studies of alien hand syndrome, then, will be difficult until a clear cut syndrome is defined or there is a consensus about whether there are one or more syndromes and what the relation is between each syndrome and the underlying process.²

Our patient shows the multiple anatomical substrates underlying potential alien hand syndrome and the clinical variability (associated cortical symptoms, accompanying movements, duration) of this syndrome. Given the difficulties in a homogeneous assessment and consensus definition, we

prefer alien hand sign instead of alien hand syndrome, so that more flexibility in anatomical correlations and associated features can be permitted.

A MARCOS DOLADO
C CASTRILLO
D G URRA
E VARELA DE SEIJAS
Department of Neurology,
Hospital Universitario San Carlos,
Madrid, Spain.

Correspondence to: Dr A Marcos Dolado, Department of Neurology, Hospital Universitario San Carlos, C/Martin Lagos, s/n, 28040, Madrid, Spain.

- 1 Doody RS, Jankovic J. The alien hand and related signs. *J Neurol Neurosurg Psychiatry* 1992;55:806-10.
- 2 Doody RS. The alien hand. In: Molgaard G, ed. *Neuroepidemiology, theory and method*, Orlando: Academic Press, 1993:181-93.
- 3 Goldstein K. Zur Lehre der motorischen Apraxia. *Z Psychol Neurol* 1908;11:169-87.
- 4 Banks G, Short P, Martinez AJ, Latchaw R, Ratcliff G, Boller F. The alien hand syndrome: clinical and postmortem findings. *Arch Neurol* 1989;46:456-9.
- 5 Feinberg TE, Schindler RJ, Flanagan NG, Haber LD. Two alien hand syndromes. *Neurology* 1992;42:19-24.
- 6 Leiguarda R, Starkstein S, Nogués M, Berthier M, Arbelaz R. Paroxysmal alien hand syndrome. *J Neurol Neurosurg Psychiatry* 1993;56:788-92.

Antiganglioside antibodies in toxic oil syndrome

Toxic oil syndrome emerged in Spain in 1981, affecting 20 000 people after ingestion of rapeseed oil that was denatured with aniline for industrial use, subsequently refined in an attempt to detoxify it, and fraudulently directed to human consumption.¹ It caused an acute flu-like illness with interstitial pneumonitis that progressed in 15% of the patients to a chronic syndrome, characterised by scleroderma-like skin manifestations, sicca syndrome, arthritis, and various neurological disorders.² These were acute encephalopathy, stroke-like episodes, and peripheral nerve lesions with acute or chronic axonal or, less often, demyelinating polyneuropathy. The neuropathy ranged from mild impairment to severe cases, wheel chair bound for months. Around 10% of these patients are still under medical surveillance, due to cardiorespiratory and neurological sequelae. The clinical features and proposed pathogenic mechanism of toxic oil syndrome are similar to the eosinophilia-myalgia syndrome. So far, the toxic substance has not been identified and the mechanisms of lesion of the peripheral nerves has not been established. An autoimmune mechanism has been proposed, but the role of autoimmunity is not clear. We have evaluated the presence of antiganglioside antibodies in patients with toxic oil syndrome and peripheral neuropathy.

Serum samples from 12 patients (two men and 10 women, age range 20-60; mean 43.9 (SD 16.7) years) with toxic oil syndrome and peripheral neuropathy were studied. Neuropathy was not progressive, except in one patient, in whom progression was established by repeated conduction studies. Two patients also had CNS disorders (myoclonia and hyperreflexia). Serum electrophoresis, erythrocyte sedimentation rate, complement study, latex fixation, and