

SHORT REPORT

## Bilateral lesions of CA1 and CA2 fields of the hippocampus are sufficient to cause a severe amnesic syndrome in humans

L D Kartsounis, P Rudge, J M Stevens

### Abstract

**A patient is reported in whom a classic amnesic syndrome developed as a result of repeated episodes of cerebral ischaemia, accompanied by seizures. The amnesia was very severe for both old and newly acquired memories and the critical lesions defined by MRI were circumscribed areas confined to CA1 and CA2 fields of both hippocampi.**

(*J Neurol Neurosurg Psychiatry* 1995;59:95-98)

Keywords: amnesic syndrome; lesions of CA1 and CA1 hippocampal fields

In its classic manifestation the amnesic syndrome includes severe anterograde amnesia and variable degrees of retrograde amnesia. The study of its anatomical correlates has been problematical due to different brain areas being reported as damaged and the variation in the ways neurobehavioural data, often inadequate, had been obtained, in different case reports. Neuropathological studies have generally suggested, however, that the critical lesions are in the medial temporal structures, particularly in the hippocampus and amygdala, in diencephalic regions—that is, the dorsal medial thalamic nuclei and the mamillary bodies. As the hippocampus and the amygdala have rich connections with the diencephalon, it has been suggested that in diencephalic amnesia, pathways to and from the medial temporal areas are affected.<sup>1,2</sup> That the hippocampus plays a critical part in the acquisition of memories is supported by findings suggesting that the severity of memory impairment correlates with the extent of hippocampal resection in patients undergoing surgery for intractable epilepsy.<sup>3</sup> Magnetic resonance imaging techniques now provide direct *in vivo* evidence on critical brain structures in human amnesia and an earlier report identified hippocampal abnormalities in three amnesic patients.<sup>4</sup> These data, however, merely showed a reduction in the total size of the hippocampus and did not precisely define the areas involved. It remains unclear what parts of the hippocampus are crucial to memory. Furthermore, there is no consensus in the neurophysiological literature as to whether both anterograde

and retrograde amnesia may result from hippocampal damage or only anterograde memories are affected.

We report a patient in whom a classic amnesic syndrome developed and show that the critical lesions defined by MRI were specific, circumscribed areas of both hippocampi.

### Case report

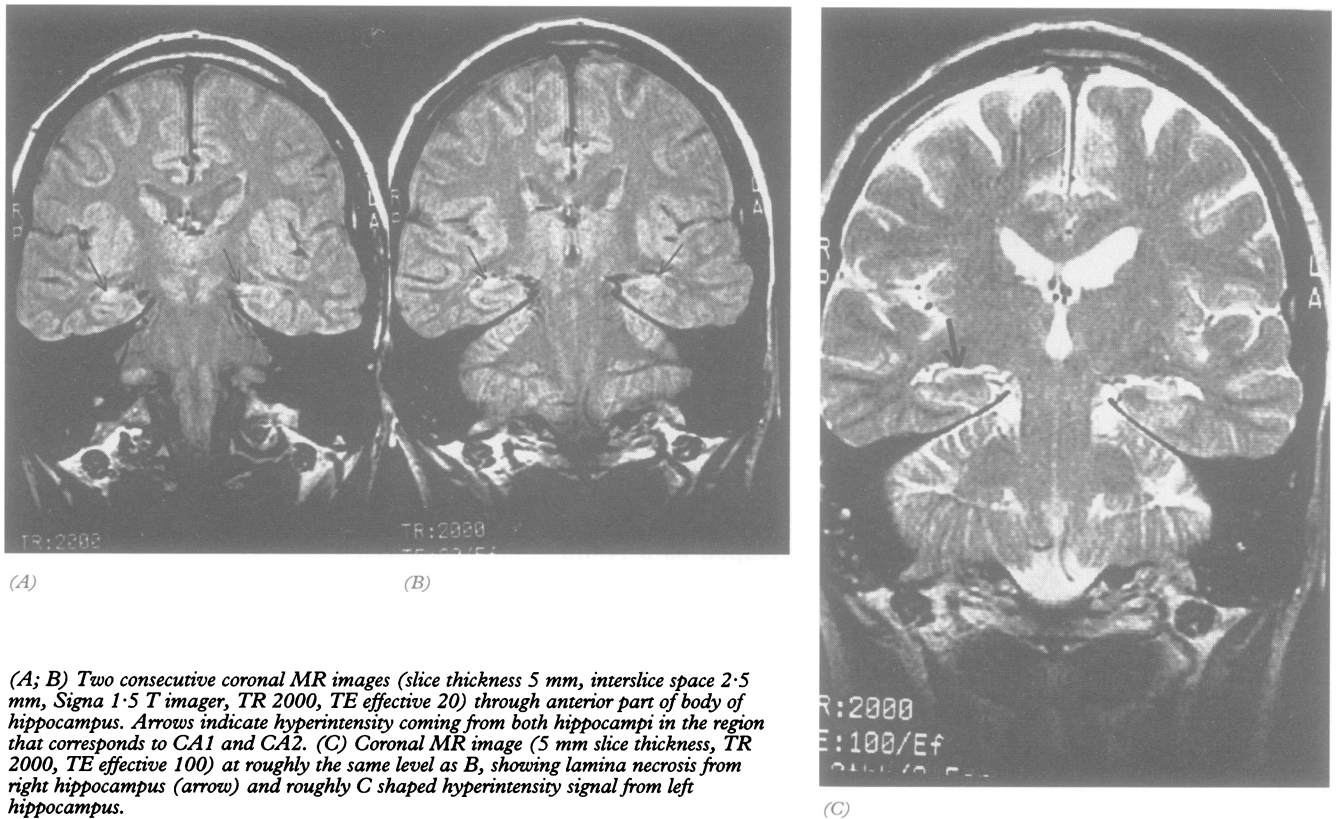
The patient is a 67 year old retired seaman with chronic obstructive airways disease. He has a 30 year history of migraine. He used to drink fairly large amounts of alcohol but not in recent years, confirmed by his wife. In September 1993, after two similar episodes, he developed an apparent migraine attack, had a major convulsion, and was noted to have a supraventricular tachycardia that required DC conversion. Two days later he was alert and cooperative but he had a profound memory disturbance. At no time before this illness had he had amnesic episodes. Laboratory investigations, including liver function tests, full blood count, venereal disease research laboratory tests, and serum B12, as well as angiography and CT, were normal. Brain MRI in the sagittal and horizontal planes was normal, but coronal sections through the temporal lobes showed abnormal signals from the hippocampi, confined to CA1 and CA2 fields, more so on the left. Some of the nuclei of the left amygdala were also involved (figure). The mamillary bodies and the thalamus were not involved. The abnormalities on MRI were interpreted as lamina necrosis.

The patient's verbal IQ on the Wechsler adult intelligence scale (WAIS-R)<sup>5</sup> was 99 and performance IQ 111, the first being only slightly below his estimated optimal level of functioning. His language and visual perceptual skills were normal and he performed well on tests of frontal lobe executive function. His scores on recognition memory tests<sup>6</sup> were at a defective level. His immediate recall of a short story<sup>7</sup> and of designs<sup>7,8</sup> were below normal limits and, on a 10 minute delayed recall he failed to reproduce a single idea. It has been shown that amnesic patients can perform well on perceptual learning tasks involving verbal or pictorial material<sup>9,10</sup> and, as expected, his performance was competent. Thus on a variety of anterograde memory

The National Hospital  
for Neurology and  
Neurosurgery, Queen  
Square, London  
WC1N 3BG, UK  
L D Kartsounis  
P Rudge  
J M Stevens

Correspondence to:  
Dr P Rudge.

Received 22 August 1994  
and in revised form  
7 March 1995  
Accepted 10 March 1995



(A; B) Two consecutive coronal MR images (slice thickness 5 mm, interslice space 2.5 mm, Signa 1.5 T imager, TR 2000, TE effective 20) through anterior part of body of hippocampus. Arrows indicate hyperintensity coming from both hippocampi in the region that corresponds to CA1 and CA2. (C) Coronal MR image (5 mm slice thickness, TR 2000, TE effective 100) at roughly the same level as B, showing lamina necrosis from right hippocampus (arrow) and roughly C shaped hyperintensity signal from left hippocampus.

tasks he performed as a typical amnesic patient. The table gives a summary of his performance on memory tests.

In response to questions about his background, he consistently referred to events of his distant past. In particular, he talked of his service in the navy several decades ago and his youth. He was able to give a good account of how he met his wife when he was aged 20. For the most part he described well his wedding in his early 20s but transposed to it inaccurate details that related to his sister's wedding in the 1950s. He was reported to

have been very close to his stepfather and his uncle, who had both died in the 1970s. When asked to talk of the death of his closest relative, however, he referred to the death of a friend of the same age as himself at the age of 14. To the question about his last holiday with his wife, which took place in 1989, he referred to a holiday they had taken 40 years previously. On various other structured questionnaires of retrograde memory, probing both autobiographical and public remote memory, his performance was similarly very poor (table). There was no suggestion of

#### Summary of memory test results

##### Anterograde memory:

Recognition tests—Words: 33/50; faces: 32/50  
( $< 5$ th percentile)

Recall tests—Story: immediate recall: below normal limits  
Delayed recall: 0  
Designs: as for story

##### Retrograde memory:

###### Autobiographical memory interview

Personal Semantic: 31 (max 63)  
Incidents: 12 (max 27)

Galton-Crovitz technique—Poor performance (see text)

Family photographs— Recognition of faces in: 7/17  
Content identification in: 1/17

###### Public remote memory:

Naming current famous faces (n = 15)	Patient	2	Controls	13.5 (1.1)
Identifying world famous people by their names (n = 15)		1		13.8 (0.8)
Identifying major events of the past 30 years by name (n = 10)		1		9.5 (0.5)
Famous faces (1970s, 1980s)—Triplets (3 × n = 15)				

	Naming		Familiarity	
	Patient	Controls	Patient	Controls
1970s	0	10.2 (1.3)	10	13.2 (2.0)
1980s (i)	2	11.8 (2.9)	14	(13.7 (2.2))
1980s (ii)	2	8.5 (3.2)	15	12.8 (1.9)

Values in parentheses are SD; controls (n = 4) were matched to patients for age (mean 68.5 (SD 2.9)) and NART IQ (mean 112.5 (SD 5.5)).

“temporal gradient” in his answers. On an autobiographical questionnaire of semantic memory and incidents since childhood autobiographical memory interview<sup>11</sup> his responses were unsatisfactory in both aspects of the test. Using the Galton-Crovitz technique<sup>12</sup> he was asked to describe unique episodes of his life relating to each of 10 high frequency nouns such as “plant”, “pen”, and “camera”. In response to eight of these words he referred to episodes of his childhood or youth; he seemed unable to retrieve any event relating to the remaining two words. His ability to identify people and events in family photographs was severely impaired. He had great difficulty in identifying or naming contemporary famous people including politicians, royalty, and entertainers. When provided with the forename and the first letter of the surname of each of these faces, he was able to name about half of them. In a different session the same cueing method was used without showing him the photographs of these famous people and he again named about half but could hardly provide any other identifying information. He was gravely impaired in identifying world famous people (for example, Nelson Mandela, Saddam Hussein) by their names; given a choice of three alternative occupations for each of these people he recognised more than half of them but was unable to provide any further correct identifying information. In a further task each of 45 famous faces of the 1970s and 1980s (EK Warrington, personal communication) was presented together with two non-famous distractor faces and he was able to select the famous from each triplet in most cases (familiarity responses). He was unable to name any face from the 1970s, however, and only very few from the triplets of the 1980s. He could provide only limited identifying information for three or four famous faces of each set of triplets (for controls, about 12 faces were identified from each set). He could say little about and often produced inaccurate information about major world events of the past few decades such as the Vietnam war. Except for one, he was unable to give any accurate information regarding 10 major events of the past two decades with British interest (for example, the Falklands war and the Lockerbie disaster).

Finally he was assessed on a test of new vocabulary by asking him to name photographs of 15 “modern” items such as a video camera and a compact disc; he was able to name only two (controls named 13.7 (SD) 0.8). By contrast, he was able to name pictures depicting historical figures or major world landmarks such as King Canute and the Parthenon<sup>13</sup>; he named 21 out of 30 items correctly (controls named 20.32 (SD 5.8)). Thus whereas his ability to recall factual knowledge with which he had become familiar at a young age (semantic memory) was well preserved, he could retrieve few new concepts or new vocabulary (in a sense “new semantic memory”).

## Discussion

Our patient failed on a comprehensive series of verbal and non-verbal, anterograde, and retrograde memory tests, in the context of well preserved intellectual skills. In common with other severely amnesic patients<sup>14</sup> apart from benefiting to a certain degree by cueing effects and in doing so showing “implicit learning”, no dissociations or fractionations in his memory skills were seen.

The localised hippocampal damage after repeated cardiac arrest could be the result of ischaemia coupled with a high energy requirement due to concurrent epilepsy. It is known that CA1 and CA2 fields are especially vulnerable to ischaemic damage<sup>15</sup> and it is tempting to speculate that this is due to the high concentration of glutamine and excitatory glutaminergic synapses in this area. Ischaemia might cause glutamine release as a result of energy failure in cells containing glutamine; stimulation of glutaminergic synapses could then cause the epileptic discharge, thus enhancing the energy requirements of the tissue and ultimately cytotoxicity due to excessive excitation.<sup>16,17</sup> The notion that stimulation of glutamate receptors can cause hippocampal damage, especially in CA1, is supported by postmortem data from patients in whom an amnesic state was induced by domoic acid.<sup>18</sup>

Our study shows that both severe anterograde and retrograde amnesia may occur with isolated bilateral CA1 and CA2 damage (see later discussion on left amygdalar involvement). There has been a previous report of selective bilateral damage to CA1 areas of the hippocampus on postmortem examination.<sup>19</sup> The patient in that report, however, was significantly impaired on anterograde memory tasks but showed little, if any, retrograde amnesia. More generally, in all published relevant neuropathological and surgical, individual, or group studies, good evidence for both anterograde and retrograde memory impairment is lacking, or there are fairly extensive lesions outside the hippocampi, or the precise hippocampal areas involved are not defined.<sup>4,19,20</sup>

Apart from the hippocampus, in our patient the basal nuclei of the left amygdala were damaged but this damage is unlikely to be relevant for at least three reasons. Firstly, lesions of the amygdala that spare adjacent cortical regions do not impair memory or exacerbate the impairment after lesions of the hippocampal formation in monkeys.<sup>21</sup> Such findings indicate that the hippocampal structures comprise the critical component of the medial temporal memory system. Secondly, with regard to human amnesia, Scoville and Milner<sup>22</sup> found that, if the resections in epileptic patients spared the hippocampus and included only the uncus and amygdala, no discernible impairment of memory occurred. Thirdly, the right amygdala in our patient was not damaged and yet his visual memory was as impaired as his verbal memory, visual memory being subserved by the right hemisphere. It thus seems unlikely that

the amygdalar lesion was relevant to the impairment of memory in this patient.

A note of caution in interpreting our findings should be added. Detailed MRI showed damage limited to the hippocampi and left amygdala. Subtle histological changes in other areas or remote hypoactivation effects of the hippocampal infarcts, particularly with regard to adjacent cortical areas and the mamillothalamic system, cannot, however, be excluded. Nevertheless, this case study provides strong evidence of severe memory impairment due to circumscribed structural damage of the hippocampi and this finding has not been previously reported.

We thank Professors E K Warrington and J O'Keefe for helpful discussion.

- 1 Graff-Radford NR, Tranel D, Van Hoesen GW, Brandt JP. Diencephalic amnesia. *Brain* 1990;113:1-25.
- 2 Aggleton JP, Mishkin M. Memory impairments following restricted medial thalamic lesions in monkeys. *Exp Brain Res* 1983;52:199-209.
- 3 Rausch R, Babb TL. Hippocampal neuron loss and memory scores before and after temporal lobe surgery for epilepsy. *Arch Neurol* 1993;50:812-7.
- 4 Press GA, Amaral DG, Squire LR. Hippocampal abnormalities in amnesic patients revealed by high-resolution magnetic resonance. *Nature* 1989;341:54-7.
- 5 Wechsler D. Wechsler adult intelligence scale revised (WAIS-R). San Antonio, Texas: The Psychological Corporation, 1981.
- 6 Warrington EK. *Recognition memory test*. Windsor: NFER-Nelson, 1984.
- 7 Coughlan AK, Hollows SE. *The adult memory and information processing battery (AMIPB)*. Leeds: Coughlan and Hollows, 1985.
- 8 Wechsler D, Stone CP. *Wechsler Memory Scale*. New York: Psychological Corporation, 1955.
- 9 Gollin ES. Developmental studies of visual recognition of incomplete objects. *Percept Mot Skills* 1960;11:289-98.
- 10 Warrington EK, Weiskrantz L. New method of testing long-term retention with special reference to amnesic patients. *Nature* 1968;277:972-4.
- 11 Kopelman MD, Wilson BA, Baddeley AD. *The autobiographical memory interview*. Bury St Edmunds: Thames Valley Test Co, 1990.
- 12 Sagar HJ, Cohen NJ, Sullivan EV, Corkin S, Growdon JH. Remote memory function in Alzheimer's disease and Parkinson's disease. *Brain* 1988;111:185-206.
- 13 McKenna P, Warrington EK. Testing for nominal dysphasia. *J Neurol Neurosurg Psychiatry* 1980;43:781-8.
- 14 Warrington EK, McCarthy RA. The fractionation of retrograde amnesia *Brain Cogn* 1988;7:184-200.
- 15 Schmidt-Kastner R, Freund RA. Selective vulnerability of the hippocampus in brain ischaemia. *Neuroscience* 1991;40:599-636.
- 16 Lipton SA, Rosenberg PA. Mechanisms of disease: excitatory amino acids as a final common pathway for neurologic disorders. *N Engl J Med* 1994;330:613-22.
- 17 Sloviter RS. The functional organisation of the hippocampus dentate gyrus and its relevance to the pathogenesis of temporal lobe epilepsy. *Ann Neurol* 1994;35:640-54.
- 18 Teitelbaum JS, Zatorre RJ, Carpenter S, et al. Neurologic sequelae of domoic acid intoxication due to the ingestion of contaminated mussels. *N Engl J Med* 1990;322:1781-7.
- 19 Zola-Morgan S, Squire LR, Amaral DG. Human amnesia and the medial temporal region: enduring memory impairment following a bilateral lesion limited to field CA1 of the hippocampus. *J Neurosci* 1986;6:2950-7.
- 20 Horel JA. The neuroanatomy of amnesia. A critique of the hippocampal memory hypothesis. *Brain* 1978;101:403-45.
- 21 Zola-Morgan S, Squire LR, Amaral DG. Lesions of the amygdala that spare adjacent cortical regions do not impair memory or exacerbate the impairment following lesions of the hippocampal formation. *J Neurosci* 1989;9:1922-36.
- 22 Scoville WB, Miller B. Loss of recent memory after bilateral hippocampal lesions. *J Neurol Neurosurg Psychiatry* 1957;20:11-21.