

Nobuyuki Sodeyama
Mitsuyuki Tamaki
Morihiro Sugishita

Persistent pure verbal amnesia and transient aphasia after left thalamic infarction

Received: 25 April 1994
Received in revised form: 22 July 1994
Accepted: 5 August 1994

N. Sodeyama (✉)
Department of Neurology,
School of Medicine,
Tokyo Medical and Dental University,
Yushima 1-5-45, Bunkyo-ku,
Tokyo 113, Japan

M. Tamaki
Department of Neurology,
Kanto Teishin Hospital, Tokyo, Japan

M. Sugishita
Department of Rehabilitation,
Tokyo Metropolitan Institute
for Neurosciences, Tokyo, Japan

Abstract A 57-year-old right-handed man suffered persistent pure verbal amnesia (PPVA) and transient aphasia after left thalamic infarction. A neuroanatomical study with magnetic resonance imaging to identify the site of the lesion showed destruction of the internal medullary lamina (IML), mammillothalamic tract (MTT), the ventrolateral nucleus (VL) and the lower one-third of the medial nucleus. As regions critical

for PPVA are unknown, we reviewed the cases of PPVA after left thalamic infarction reported in the literature. These suggest that confined destruction of the IML, MTT and VL in the left thalamus can produce PPVA.

Key words Thalamus · Internal medullary lamina · Mammillothalamic tract · Ventrolateral nucleus · Persistent pure verbal amnesia

Introduction

Left anterior temporal lobectomy causes verbal amnesia, and transient aphasia occurs when lobectomy is extended posteriorly [16, 17]. The same disturbances have been reported in association with confined left thalamic infarction [6, 18]. The regions critical for verbal amnesia in the left thalamus are, however, a matter of controversy. Examination of the affected structures in persistent pure verbal amnesia (PPVA) is necessary to identify the integral lesion that produces verbal amnesia. We present a case of PPVA after left thalamic infarction and review other cases reported in the literature.

Case report

A 57-year-old right-handed man who had suffered hypertension for 15 years was admitted to our hospital after his speech was found to be incoherent and decreased. On admission, he was alert and cooperative. He had difficulty in recalling what had happened after the onset of his speech disturbance. His speech was decreased

and difficult to understand, being filled with circumlocutions, word-finding difficulty, and frequent semantic paraphasias, but fluent in terms of normal prosody and grammatical form. Visual naming was severely impaired, only one of ten objects presented being correctly named. Verbal repetition was normal. Aural and reading comprehension were slightly impaired. He could recall four digits backward, but could not recall any of five objects after 1 min. Physical examinations revealed no abnormality except for hypaesthesia of the right lower limb. Magnetic resonance imaging (MRI) of the brain on admission revealed left thalamic infarction.

Neuropsychological study

Results of the Standard Language Test of Aphasia (STLA) given on the 10th day after admission indicated that his auditory comprehension (90% correct), naming (65% correct), writing (75% correct), calculation (55% correct) and reading (95% correct) were impaired.

His aphasia gradually lessened, his scores on the STLA 2 months after the stroke being almost normal. On the Wechsler Adult Intelligence Scale Revised (WAIS-R, Japanese version) 3 months after admission, he had a verbal IQ of 120 and a performance IQ of 109; a total IQ score of 116. The indexes of the Western Aphasia Battery (Japanese version) at 3 months were normal (fluency, 10; auditory comprehension, 9.95; repetition, 10; naming, 9.4; aphasia quotient, 98.7). Results of the Wechsler Memory

Table 1 Scores on the Wechsler Memory Scale Revised (Japanese version) 3, 5 and 10 months after our patient's stroke

Subject	3 months		5 months		10 months	
	Index score	Raw score	Index score	Raw score	Index score	Raw score
Information and orientation questions		13		13		14
Attention and concentration	114		124		114	
Mental control		4		4		4
Digit span		16		19		15
Visual memory span		17		20		20
Verbal memory	78		75		94	
Logical memory I		16		15		21
Verbal paired associates I		10		9		16
Visual memory	93		104		123	
Figural memory		6		6		8
Visual paired associates I		5		4		16
Visual reproduction I		32		39		35
General memory	81		84		104	
Delayed memory	79		89		103	
Logical memory II		6		10		14
Visual paired associates II		1		2		6
Verbal paired associates II		3		3		5
Visual reproduction II		32		35		35

Scale Revised (WMS-R, Japanese version) at 3 months indicated amnesia for verbal material, which was accompanied by mild visual memory impairment (Table 1). He could recall his birthday, birthplace, his two wedding days, all the recent prime ministers of Japan, and the date of the end of the Second World War. He correctly reported his personal history, which indicated no gross deficit in remote memory function. Index scores of the WMS-R at 5 months showed no change of his verbal amnesia, despite improvement of visual memory (Table 1). Seven months after the stroke, he returned to work. Although his wife felt that he was closer to his usual activity, he often complained of his memory deficits. Index scores of the WMS-R at 10 months showed that his memory deficit was clearly confined to verbal material (Table 1). Neuropsychological findings at this stage reflected PPVA.

Neuroradiological study

We identified the site of the lesion in our patient by the method of Mori et al. [18], and MRI was performed 4 months after the stroke. Coronal sections, perpendicular to the foramen of the Monro-posterior commissure line, were made at thickness of 3 mm with no slice gap (Fig. 1). Projection of each MRI plane on the appropriate Andrew and Watkins atlas [1] showed that the structures involved were the internal medullary lamina (IML), mammillothalamic tract (MTT), ventrolateral nucleus (VL) and the lower one-third of the medial nucleus (MN) (Fig. 2).

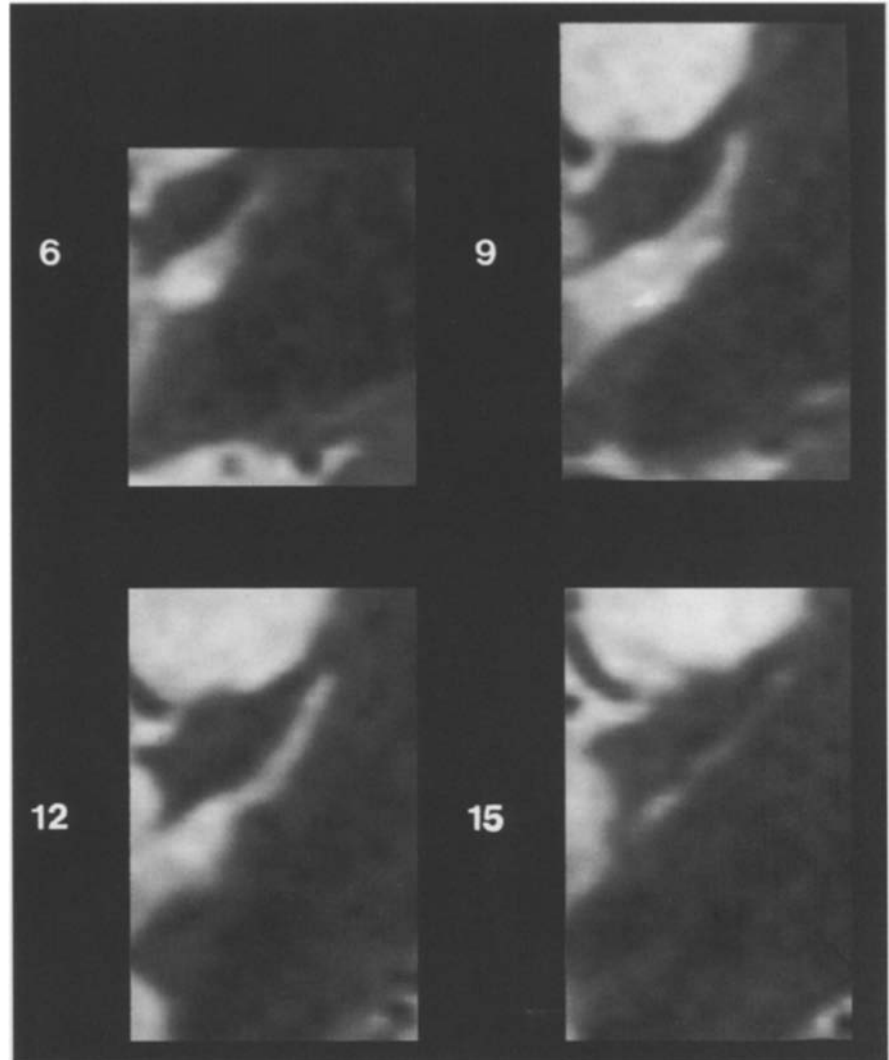
Discussion

Although our patient experienced thalamic aphasia immediately after his stroke, isolated verbal memory loss persisted in the absence of consciousness disturbance, aphasia and dementia in the chronic stage, as his index score of

verbal memory (94) on the WMS-R at 10 months was markedly decreased in contrast to his scores for visual memory (123) on the WMS-R and total IQ (116) on the WAIS-R. His condition at 10 months therefore was categorized as PPVA.

To ascertain the minimal lesion that produces PPVA, we evaluated the patient's neuroradiological findings and those reported in the literature for five cases of PPVA with confined left thalamic infarction, in which at least PPVA had been proved by neuropsychological examinations and for which detailed topographical analyses were provided. These were case 1 reported by Ino et al. [11], cases 1 and 3 reported by Pepin and Auray-Pepin [22], the case reported by Goldenberg et al. [6] (handedness not shown), the case reported by Mori et al. [18], and our case. [We excluded the case reported by Mennemeier et al. [15] because their patient was left-handed and her memory quotient (100) was not markedly decreased in comparison with her verbal IQ (102)]. The common structures in which there were lesions in these six cases were the IML, MTT and VL. There was wide variation in the degree of damage to the anterior nucleus (AN) and MN. The AN was spared in four cases (those reported by Mori et al., Ino et al., Goldenberg et al., and our case), and was partially involved in two cases (cases 1 and 3 reported by Pepin and Auray-Pepin). The MN was affected only minimally in one case (that reported by Mori et al.), partially in five cases (those reported by Ino et al., Goldenberg et al., cases 1 and 3 reported by Pepin and Auray-Pepin, and our case). The term "global amnesia" implies memory im-

Fig. 1 Left coronal MRI sections showing the lesion in our patient. Numbers at the left of each section are the distance in millimetres from the foramen of Monro (1.5 T, TR: 3500, TE: 102)



pairment for both verbal and visual materials, and “amnesia” for either verbal or visual material, or both in the following.

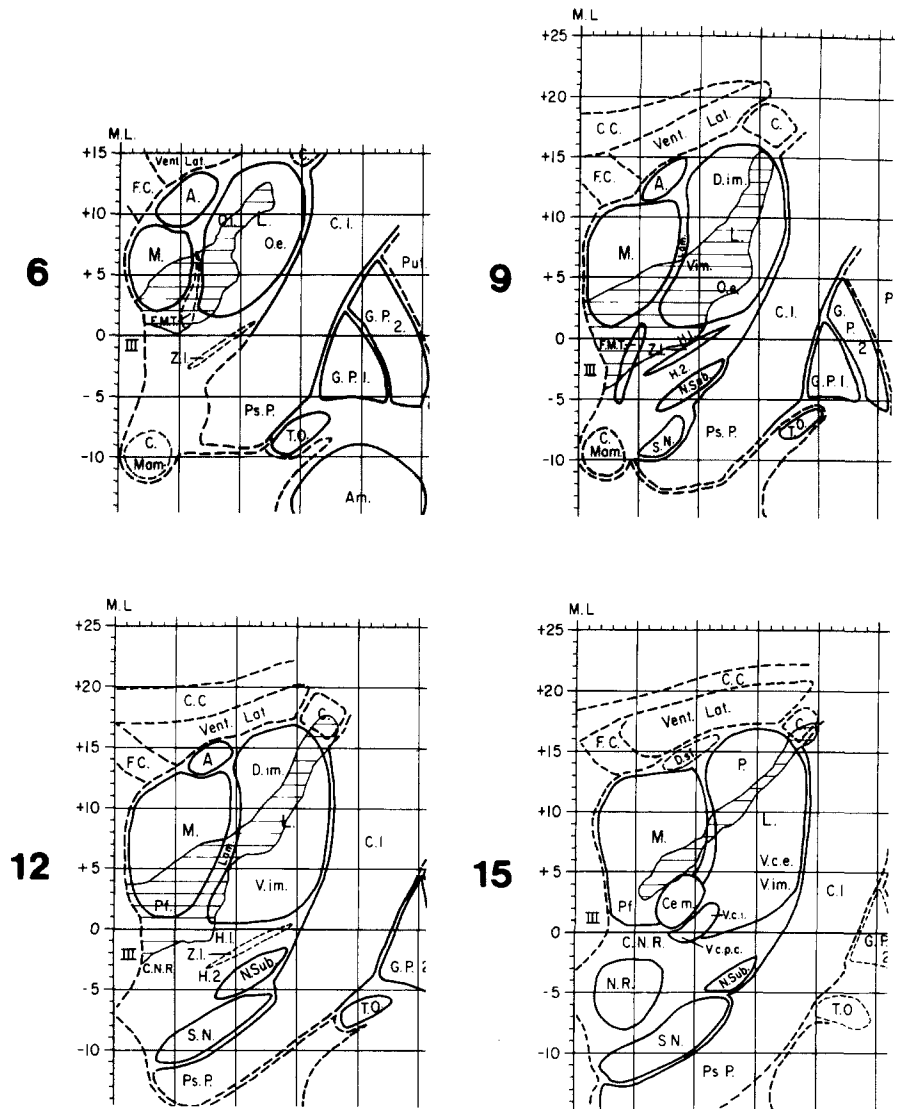
The IML is the pathway presumed to be closely related to amnesia [5, 9, 13, 22], and the existence of the IML has been confirmed in the monkey, but not in humans [9, 11]. The fibres which connect with the dorsomedial nucleus (DM) or intralaminar nuclei pass through the IML [5, 9, 13, 18, 22]. The DM has extensive connections with the hippocampus, the insula cortex and the temporal cortex, as well as bidirectional ones with the prefrontal cortex, the amygdala, the cingular cortex and the orbitofrontal cortex [5, 9, 13, 18, 19, 22, 24]. The intralaminar nuclei have afferent connections with the superior colliculus, the limbic system and the mesencephalic reticular formation, as well as efferent connections with the striatum and neocortex, and bidirectional ones with the cortex diffusely. These connections may be important for activating the verbal memory process, as suggested by previous reports

[18, 22]. Damage to the IML should disrupt these connections and interactions. Nichelli et al. [19] considered thalamic amnesia to be a disconnection syndrome between the frontal and temporal lobes. Unlike the IML, the DM is not a probable critical region in thalamic amnesia as a number of reports have shown [5, 11–13, 18, 22]

The MTT is a component of Papez’s circuit which connects the mammillary body with the AN, and disruption of this circuit produces persistent amnesia [5, 9, 11–13, 18, 19, 22]. As reported in the literature, thalamic infarction without involvement of the MTT does not produce significant amnesia [5, 9, 12]. Because the degree of damage to the AN in the six cases reviewed varied and there has been no report of an isolated AN lesion producing persistent amnesia [13], the AN is not the likely critical structure [5]. In thalamic amnesia, the fibres (IML, MTT) appear to be more important than the nuclear mass (DM, AN) [5, 11, 13].

The VL is connected reciprocally with the motor and premotor cortexes [5, 14]. Efferent projections from the

Fig. 2 Projections of the lesion on the atlas of Andrew and Watkins [1]. Numbers are the same as in Fig. 1 A. anterior nucleus, *Am.* amygdalum, *C.* caudate nucleus, *C.C.* corpus callosum, *Ce.m.*, centro-medianum, *C.I.* capsula interna, *C.Mam.* corpus mammillare, *C.N.R.* capsular nuclei rubri, *D.im.* dorso-intermedius, *D.sf.* dorsalis superficialis, *F.C.* fornix body, *F.M.T.* fasciculus mamillo-thalamicus, *G.P.1* globus pallidus, crus 1, *G.P.2* globus pallidus, crus 2, *H.1* dorsal tegmental area, *H.2* ventral tegmental area, *L.* lateral mass of thalamus, *Lam.* internal medullary lamina of thalamus, *M.* medial mass of thalamus, *N.R.* nucleus ruber, *N.Sub.* nucleus subthalamicus of Luys, *O.e.* oralis externus, *O.i.* oralis internus, *P.* pulvinar, *Pf.* parafascicularis, *Ps.P* pes pedunculi, *Put.* putamen, *S.N.* substantia nigra, *T.O.* tractus opticus, *V.c.e.* ventro-caudalis externus, *V.c.i.* ventro-caudalis internus, *V.c.p.c.* ventro-caudalis parvo-cellularis, *V.im.* ventro-intermedius, *Vent.Lat.* ventriculus lateralis, *Z.I.* zona incerta, *III* third ventricle



VL to these cortexes are mediated by the mesencephalic reticular formation and medial thalamic frontocortical system, the latter receiving projections from the frontal cortex [14]. The VL also receives afferent projections from the globus pallidus and cerebellum [14]. Because of this complicated network, the VL is considered to be the relay nucleus between the motor control system and the neocortex [14]. The importance of the role of the VL in thalamic aphasia and amnesia has been well discussed [2, 4, 11, 14, 18, 20]. Ojemann et al. [20, 21] found that electric stimulation of the VL facilitated recording of verbal information, caused deterioration of retrieval of verbal memories, and disturbed object naming. Thalamic aphasia is often accompanied by amnesia [2, 6, 18, 22], suggesting that the VL may be involved in both aphasia and amnesia.

Although Mennemeier et al. [15] insisted that inattention contributes to thalamic amnesia to some degree, ordi-

nary neuropsychological examinations of PPVA cases have shown no disturbance of attention, which suggests that inattention is not the main factor in PPVA [18, 22, 26].

Mori et al. [18] regarded thalamic aphasia as a part of defective memory processing of verbal material. PPVA, however, is characterized primarily by a learning difficulty for verbal material with mild disturbances of retention and few retrieval problems; therefore the main PPVA disturbance is in registration [11, 13, 18, 22]. In contrast, thalamic aphasia is constituted mainly of word-finding difficulty, which is commonly recognized as a defect in retrieval [4, 6, 10, 18]. Moreover, verbal amnesia tends to persist even when thalamic aphasia has been considerably reduced [6, 10, 18]. The discrepancies in the characteristics of and recovery from thalamic aphasia and thalamic amnesia suggest that neither are solely of neuropsychological origin.

Graff-Radford et al. [9] considered that simultaneous damage to isolated structures does not produce significant amnesia because certain memory systems compensate for each other; they concluded that damage to particular structures is required to produce amnesia. Our clinicoanatomical analysis of the cases reported in the literature suggests that the IML, MTT and VL are the basic structures which, when damaged, produce PPVA. We speculate that the mechanism that produces PPVA is one in which disruptions of the connections between the IML, MTT and VL, and the extensive cerebral regions lead to the interception of signals for the interactions and activation of the verbal memory process. This must be distinguished from nonspecific attention. That extensive cerebral regions are connected to each other through the thalamus suggests that the left thalamus may be the relay station of signals for verbal memory rather than the centre playing a very direct role in verbal memory.

The structures involved in global amnesia cases after confined left thalamic infarction have been examined in detail by Hirono et al. [10] (accompanied by minimal thalamic aphasia) and Gorelick et al. [7]. (We excluded the case reported by Bogousslavsky et al. [4] because it involved haemorrhagic infarction that may have affected the MTT and there were many metastases in the liver due to breast cancer.) The area of overlap in two cases also was the IML, MTT and VL. In the case reported by Hirono et al. there was damage to the IML, MTT and VL but the MN was scarcely affected. In the case reported by Gorelick et al. the involved structures were the IML, MTT, VL, AN and a part of the MN. We could not pinpoint the differences in the affected structures in verbal and global amnesia. In the cases of global amnesia, the patients (both aged 71 years) were significantly older than those with verbal amnesia (aged 40, 41, 47, 51, and 68 years). In addition to the disparity in age, MRI showed moderate to severe cerebral atrophy in the cases reported by Hirono et al. and Gorelick et al., and multiple cerebral

infarction in the case reported by Hirono et al. In none of the reported cases have detailed neuropsychological examinations shown PPVA after right or bilateral thalamic infarction [8, 9, 22, 24].

Of the cases reviewed here, the complication of aphasia was noted in the acute stage in the cases reported by Mori et al., Goldenberg et al., and Hirono et al. and in our case. In the cases reported by Sandson et al. [23] and Stuss et al. [25] there was persistent verbal amnesia, word-finding difficulty and mild attentional impairment, but no disturbance of general intelligence and visual memory after left thalamic infarction. In the case reported by Sandson et al., the IML, MTT, and parts of the VL and DM were affected, and in the case reported by Stuss et al., the AN was involved along with the aforementioned affected structures. We could not find a sharp distinction between the structures affected in the patients with and without aphasia. Although involvement of the VL is known to contribute to thalamic aphasia [2, 4, 14], obvious destruction of the VL did not produce aphasia in the cases reported by Ino et al. and by Gorelick et al., or in case I reported by Pepin et al. Results of our analysis of thalamic amnesia cases do not show a marked correlation between transient aphasia and VL.

We conclude that confined destruction of the IML, MTT and VL in the left thalamus can produce PPVA and that the complications of advanced age, multiple cerebral infarction, and/or cerebral atrophy in addition to the IML, MTT and VL, or more extensive lesions than those in the cases reviewed may cause global amnesia, dementia, inattention and cognitive disturbances [2, 5, 8, 11]. Recently Baron et al. [3] reported a correlation between neuropsychological impairment after unilateral thalamic lesion and cortical hypometabolism. Thalamic aphasia may be correlated with cortical hypometabolism rather than the extent of the lesion. Further analysis of the relationships of the structures affected to neuropsychological impairment and cortical metabolism is necessary to elucidate the mechanism of PPVA after left thalamic infarction.

References

- Andrew J, Watkins ES (1969) A stereotaxic atlas of the human thalamus and adjacent structures. Williams & Wilkins, Baltimore
- Archer CR, Illinsky IA, Goldfader PR, Smith KR Jr (1981) Aphasia in thalamic stroke; CT stereotactic localization. *J Comput Assist Tomogr* 5: 427-432
- Baron JC, Levasseur M, Mazoyer B, Legault-Demare F, Mauguière F, Pappata S, Jedynak P, Derome P, Cambier J, Tran-Dinh S, Cambon H (1992) Thalamocortical diaschisis: positron emission tomography in humans. *J Neurol Neurosurg Psychiatry* 55: 935-942
- Bogousslavsky J, Miklossy J, Deruaz JP, Regli F, Assal G (1986) Unilateral left paramedian infarction of thalamus and midbrain: a clinico-pathological study. *J Neurol Neurosurg Psychiatry* 49: 686-694
- Cramon DY von, Hebel N, Schuri U (1985) A contribution to the anatomical basis of thalamic amnesia. *Brain* 108: 993-1008
- Goldenberg G, Wimmer A, Maly J (1983) Amnesic syndrome with a unilateral thalamic lesion: a case report. *J Neurol* 229: 79-86
- Gorelick PB, Amico LL, Ganellen R, Benevento LA (1988) Transient global amnesia and thalamic infarction. *Neurology* 38: 496-499
- Graff-Radford NR, Damasio H, Yamada T, Eslinger PJ, Damasio AR (1985) Nonhaemorrhagic thalamic infarction: clinical, neuropsychological and electrophysiological findings in four anatomical groups defined by computerized tomography. *Brain* 108: 485-516
- Graff-Radford NR, Tranel D, Van Hoesen GW, Brandt JP (1990) Diencephalic amnesia. *Brain* 113: 1-25

10. Hirono N, Yamadori A, Miyai I, Kitahara Y, Fujita M (1987) A case of left thalamic infarction developing verbal and visual memory disturbance with mild aphasia (in Japanese). *Clin Neurol (Tokyo)* 27: 1170–1179
11. Ino T, Akiguchi I, Nabatame H, Kameyama M (1989) Left antero-medial thalamic infarction and symptoms of amnesia, aphasia, and dementia (in Japanese). *Clin Neurol (Tokyo)* 29: 693–700
12. Kritchevsky M, Graff-Radford NR, Damasio AR (1987) Normal memory after damage to medial thalamus. *Arch Neurol* 44: 959–962
13. Markowitsch HJ (1988) Diencephalic amnesia: a reorientation towards tracts? *Brain Res Rev* 13: 351–370
14. McFarling D, Rothi LJ, Heilman KM (1982) Transcortical aphasia from ischaemic infarcts of the thalamus: a report of two cases. *J Neurol Neurosurg Psychiatry* 45: 107–112
15. Mennemeier M, Fennell E, Valenstein E, Heilman KM (1992) Contributions of the left intralaminar and medial thalamic nuclei to memory: comparisons and report of a case. *Arch Neurol* 49: 1050–1058
16. Meyer V, Yates AJ (1955) Intellectual changes following temporal lobectomy for psychomotor epilepsy; preliminary communication. *J Neurol Neurosurg Psychiatry* 18: 44–52
17. Milner B (1954) Intellectual function of the temporal lobes. *Psychol Bull* 51: 42–62
18. Mori E, Yamadori A, Mitani Y (1986) Left thalamic infarction and disturbance of verbal memory: a clinicoanatomical study with a new method of computed tomographic stereotaxic lesion localization. *Ann Neurol* 20: 671–676
19. Nichelli P, Bahmanian-Behbahani G, Gentilini M, Vecchi A (1988) Preserved memory abilities in thalamic amnesia. *Brain* 111: 1337–1353
20. Ojemann GA, Ward AA Jr (1971) Speech representation in ventrolateral thalamus. *Brain* 94: 669–680
21. Ojemann GA, Blick KI, Ward AA Jr (1971) Improvement and disturbance of short-term verbal memory with human ventrolateral thalamic stimulation. *Brain* 94: 225–240
22. Pepin EP, Auray-Pepin L (1993) Selective dorsolateral frontal lobe dysfunction associated with diencephalic amnesia. *Neurology* 43: 733–741
23. Sandson TA, Daffner KR, Carvalho PA, Mesulam MM (1991) Frontal lobe dysfunction following infarction of the left-sided medial thalamus. *Arch Neurol* 48: 1300–1303
24. Speedie LJ, Heilman KM (1983) Anterograde memory deficits for visuospatial material after infarction of the right thalamus. *Arch Neurol* 40: 183–186
25. Stuss DT, Guberman A, Nelson R, Laroche S (1988) The neuropsychology of paramedian thalamic infarction. *Brain Cogn* 8: 348–378
26. Watson RT, Heilman KM (1979) Thalamic neglect. *Neurology* 29: 690–694