

Neurosurgery 1992-98

June 1995, Volume 36, Number 6

1185 Rosai-Dorfman Disease Mimicking Multiple Meningioma: Case Report Case Report

AUTHOR(S): Kim, Miriam, M.D.;
Provias, John, M.D.; Bernstein, Mark, M.D.

Division of Neurosurgery, Department of Pathology,
The Toronto Hospital, University of Toronto,
Toronto, Ontario, Canada

Neurosurgery 36; 1185-1187, 1995

ABSTRACT: ROSAI-DORFMAN DISEASE IS a rare idiopathic histioproliferative disease affecting the lymph nodes. Extranodal involvement has also been recognized, but central nervous system manifestations are extremely rare. Only 12 patients with intracranial involvement have been reported previously, and they all presented with clinical and radiological findings suggestive of meningioma. We report multiple meningeal nodules in a patient presenting with seizures whose pathological findings at surgery confirmed the diagnosis of Rosai-Dorfman disease. A review of all previously reported intracranial lesions is presented.

KEY WORDS: Lymphadenopathy; Meningioma; Rosai-Dorfman disease; Sinus histiocytosis

In 1969, Rosai and Dorfman⁽¹¹⁾ described a newly recognized benign histioproliferative disease characterized clinically by massive cervical lymphadenopathy, fever, and leukocytosis and characterized pathologically by enlarged lymph node sinuses containing large histiocytes with phagocytosed lymphocytes. They named the entity *sinus histiocytosis with massive lymphadenopathy* (SHML or Rosai-Dorfman disease). Since its original description, Rosai-Dorfman disease has become a well-established clinicopathological entity whose registry now numbers more than 400 cases⁽⁵⁾. The patients tend to be young at onset, tend to have painless, bilateral, massive lymphadenopathy, and usually tend to have a protracted uncomplicated clinical course, despite various therapeutic interventions^(4,11-13). Approximately one-third have concurrent extra nodal involvement, most commonly in the skin, salivary glands, and upper respiratory tract⁽¹³⁾. Only 12 cases of intracranial involvement have been described previously^(1-3,5-7,9,14-16). They are all dural-based lesions presenting clinically and radiologically as meningioma. We present a patient with multiple extra-axial convexity lesions, confirmed to be Rosai-Dorfman disease at surgery by pathological examination. A review of the previously reported intracranial manifestations is also presented.

CASE REPORT

A 50-year-old pesticide controller born in Trinidad presented after suffering from a first-time tonicoclonic seizure. He had been healthy previously,

had not been receiving medications, and had no drug allergies or significant family history. He denied having a recent fever or chills. His physical examination revealed a left homonymous hemianopia and a left hemisensory inattention in the arm. The rest of his neurological examination was normal. He was afebrile with no lymphadenopathy. Routine laboratory investigations, including a complete blood count, were normal. A computed tomographic scan with contrast showed two lesions in the right parietal convexity. A magnetic resonance imaging scan better defined these lesions to be dural based, gadolinium enhancing nodules with some mass effect (*Fig. 1*).

The patient was diagnosed preoperatively with multiple meningioma and began receiving Decadron and Dilantin. He underwent a parietal craniotomy for the complete removal of both lesions. Postoperatively, his neurological deficits gradually improved. At 6 months, he is neurologically intact and the follow-up magnetic resonance imaging scan was negative for a residual or recurrent lesion.

Pathological findings

Grossly, the tumors were firm and xanthochromic with some adherence of the anterior lesion to the underlying brain, but there was a good plane between the posterior lesion and the brain. Microscopic examination showed predominant histiocytes with abundant pale pink cytoplasm and vesicular nuclei, some plasma cells, and lymphocytes. The histiocytes stained strongly for S-100, and many showed emperipolesis, i.e., phagocytosed but intact lymphocytes (*Fig. 2*). Ultrastructural examination by electron microscopy confirmed the predominant tumor cells to be single or multinucleated histiocytes, often with prominent vacuoles of lipid accumulation in the cytoplasm (*Fig. 3*). There were no microorganisms, necrosis, or granuloma formation.

DISCUSSION

Since the original description, Rosai-Dorfman disease has become a definite clinicopathological entity. All ages are affected, but 80% of patients are 20 years old or younger at onset. Ninety percent of the patients have cervical adenopathy that is painless, bilateral, and massive⁽¹²⁾. Anemia, leukocytosis, polyclonal hypergammaglobulinemia, and raised erythrocyte sedimentation rate are common but are not always present. One-third of the patients have extra nodal involvement, such as the eyes and its appendages, skin, upper respiratory tract, bone salivary gland, testis, and meninges of the cranium and spine^(5,13). Occasionally, only extra nodal disease has been found, and for these patients, the lack of lymphadenopathy makes the term *sinus histiocytosis with massive lymphadenopathy* inappropriate.

The origin and pathogenesis of this disease are still unknown. It often occurs in the setting of nonspecific immune dysfunction, many cases occur after a viral illness⁽¹²⁾. Although the diagnosis is based on the morphological characteristics, there are other disease entities with a predominance of histiocytes, as in certain cases of leukemia, lipid storage disease, and histiocytosis X. The classical findings of dilated

nodal sinuses filled with foamy histiocytes, phagocytosed lymph nodes (emperipolesis), and plasma cells make this disease easily distinguishable⁽⁴⁾. Emperipolesis is not a unique phenomenon to Rosai-Dorfman disease and has been seen in both normal and leukemic processes⁽¹¹⁾, but it appears to be a prerequisite for the diagnosis.

One of the largest series reported described 200 patients, of whom 3 had intracranial manifestations⁽⁶⁾. Nine other case reports described intracranial involvement (*Table 1*). The average age of these 12 patients was 35. The presenting symptoms depended on the location of the lesions and were manifested by cranial nerve deficits or nonlocalizing symptoms of raised intracranial pressure or seizures. The preoperative diagnosis was usually meningioma. More than half the patients had no clinical lymph node involvement. One other patient (Patient 9) also had more than one intracranial lesion. Most were treated with surgical excision, albeit subtotal. The follow-up period varied from 1 month to 8 years in the seven patients for whom this information is available. The lesion appears to have grown in only one patient (Patient 5). We know from information available about patients with nonintracranial Rosai-Dorfman disease, that the clinical course tends to be protracted and unaltered by treatment, including radiation and chemotherapy^(5,8,13). Some have complete resolution of the adenopathy, whereas in others the condition persists but is asymptomatic. The adenopathy is rarely intermittent and recurrent.

In conclusion, Rosai-Dorfman disease is a well-recognized clinicopathological entity, which rarely affects the central nervous system where it mimics the clinical and radiological appearance of meningiomas (as in our patient). Although enough follow-up information is not yet available, it appears that these are slow-growing lesions for which surgical excision of symptomatic lesions appears to be the appropriate treatment.

Received, August 5, 1994.

Accepted, November 16, 1994.

Reprint requests: Mark Bernstein, The Toronto Hospital-Western Division, Mc 2-405, 399 Bathurst Street, Toronto, Ontario, Canada M5T 2S8.

REFERENCES: ⁽¹⁻¹⁶⁾

- Asai A, Matsutani M, Kohno T, Fujimaki T, Tanaka H, Kawaguchi K, Koike M, Takakura K: Leptomeningeal and orbital benign lymphohistiocytic histiocytosis: Case Report. **J Neurosurg** 69:610-612, 1988.
- Bhattacharjee MB, Wroe SJ, Harding M: Sinus histiocytosis with massive lymphadenopathy-isolated suprasellar involvement. **J Neurol Neurosurg Psychiatry** 55:156-158, 1992.
- Carey MP, Case CP: Sinus histiocytosis with massive lymphadenopathy presenting as a meningioma. **Neuropathol Appl Neurobiol** 13:391-398, 1987.
- Foucar E, Rosai J, Dorfman RF: Sinus histiocytosis with massive lymphadenopathy: Current status and future directions. **Arch Dermatol** 124:1211-1214, 1988.
- Foucar E, Rosai J, Dorfman R: Sinus histiocytosis with massive lymphadenopathy (Rosai-Dorfman disease): Review of the entity. **Sem Diagn Pathol** 7:19-73, 1990.
- Foucar E, Rosai J, Dorfman RF, Brynes RK: The neurologic manifestations of sinus histiocytosis with massive lymphadenopathy. **Neurology** 32:365-371, 1982.
- Friedman MJ, Rossoff LJ, Aftalion B, Khan A, Decker R, Steinberg H: Sinus histiocytosis presenting as a mediastinal mass. **Chest** 86:266-267, 1984.
- Komp DM: The treatment of sinus histiocytosis with massive lymphadenopathy (Rosai-Dorfman disease) **Sem Diagn Pathol** 7:83-86, 1990 (review).
- Lopez P, Estes ML: Immunohistochemical characterization of the histiocytes in sinus histiocytosis with massive lymphadenopathy: Analysis of extranodal cases. **Hum Pathol** 20:711-715, 1989.
- Mir R, Aftalion B, Kahn LB: Sinus histiocytosis with massive lymphadenopathy and unusual extranodal manifestations. **Arch Pathol Lab Med** 109:867-870, 1985.
- Rosai J, Dorfman RF: Sinus histiocytosis with massive lymphadenopathy: A newly recognized benign clinicopathological entity. **Arch Pathol** 87:63-70, 1969.
- Rosai J, Dorfman RF: Sinus histiocytosis with massive lymphadenopathy: A pseudolymphomatous benign disorder: Analysis of 34 cases. **Cancer** 30:1174-1188, 1972.
- Sanchez R, Rosai J, Dorfman RF: Sinus histiocytosis with massive lymphadenopathy: An analysis of 113 cases with special emphasis on its extranodal manifestations. **Lab Invest** 36:349-350, 1977 (abstr).
- Shaver EG, Rebsamen SL, Yachnis AT, Sutton LN: Isolated extranodal intracranial sinus histiocytosis in a 5-year-old boy. **J Neurosurg** 79:769-773, 1993.
- Song SK, Schwartz IS, Strauchen JA, Huang YP, Sachdev V, Daftary DR, Vas CJ: Meningeal nodules with features of extranodal sinus histiocytosis with massive lymphadenopathy. **Am J Surg Pathol** 13:406-412, 1989.
- Trudel M: Dural involvement in sinus histiocytosis with massive lymphadenopathy: Case Report. **J Neurosurg** 60:850-852, 1984.

COMMENT

The authors present a patient with a rare disorder called Rosai-Dorfman disease. Magnetic resonance imaging was employed for the diagnosis. Given the increasing availability of high resolution imaging, I believe it is important for neurosurgeons to keep

clearly in mind that a number of lesions may mimic meningiomas. It is presumed that the appropriate treatment for these intracranial lesions is surgical resection, although there is little information regarding the natural history of these dural base lesions.

William F. Chandler
Ann Arbor, Michigan

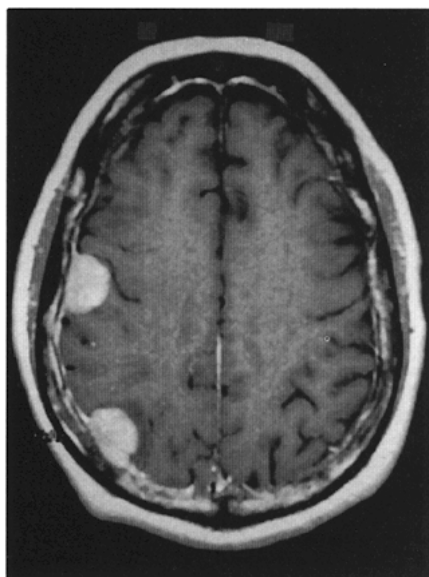


Figure 1. Gadolinium-enhanced magnetic resonance imaging scan showing two enhancing dural-based lesions with mild mass effect.

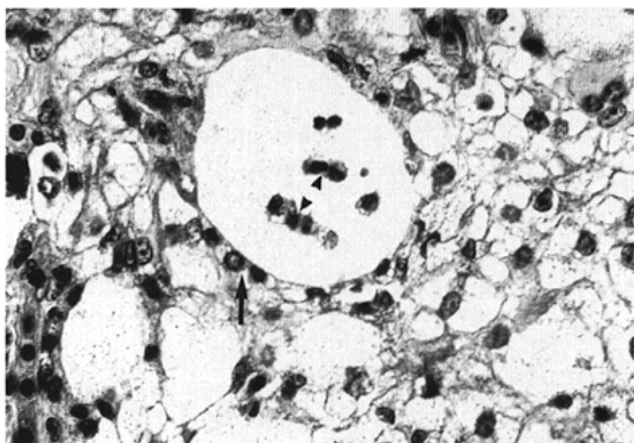


Figure 2. Population of large histiocytes with phagocytosed lymphocytes (emperipolesis) (*arrowheads*). Surrounding lymphocytes awaiting phagocytosis (*arrow*) (hematoxylin and eosin; original magnification, $\times 250$).

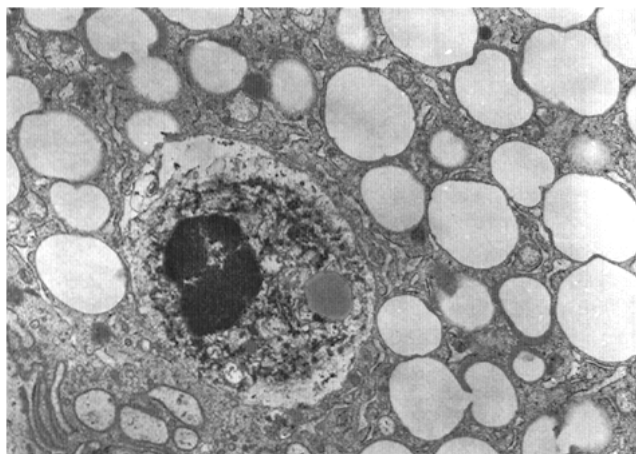


Figure 3. Cytoplasm of a histiocyte showing prominent lipid vacuolation and an emperipoletic lymphocyte (electron microscopy; original magnification, $\times 6000$).

Series (Ref. No.)	Patient	Age (yr)/sex	Symptom	Lymph Node	Location	Surgery	Follow-up
Foucar et al., 1982 (6)	1	55 F	ICP	No	Frontal epidural	N/A	N/A
Foucar et al., 1982 (6)	2	28 F	ICP	Yes	Parietal epidural	Yes	N/A
Foucar et al., 1982 (6)	3	21 M	LCN 7,8	No	Postfossa	Yes	N/A
Trudel, 1984 (16)	4	28 M	LCN 5,8	No	Temporal subdural	90% removed	14 mo, no growth
Friedman et al., 1984 (7)	5	32 M	h/a	Yes	Suprasellar	Biopsy	N/A
Mir et al., 1985 (10)	6	33 M	h/a	Yes	Suprasellar	Biopsy	N/A
Carey and Case, 1987 (3)	7	35 M	Seizure	Yes	Parasagittal	Partial	8 yr, growth
Asai et al., 1988 (1)	8	39 M	CNA II	No	Occipital	Total	3 yr, no recurrence
Song et al., 1989 (15)	9	30 M	Seizure	Yes	Multiple cranial base	Partial	N/A
Lopez and Estes, 1989 (9)	10	35 M	Facial pain	No	Cranial base	Partial	12 mo, no growth
Bhattacharjee et al., 1992 (2)	11	78 M	CNA II	No	Sellar	Partial	1 yr, no growth
Shaver et al., 1993 (14)	12	5 M	Multiple CN palsy	No	Cavernous sinus	Partial	1 mo, no growth
Present study	13	50 M	Seizure	No	Parietal convexity	Total	6 mo, no recurrence

* ICP, intracranial pressure; LCN, left cranial nerve; h/a, headache; CN, cranial nerve.

Table 1. Intracranial Rosai-Dorfman Disease^a