

Neurosurgery 1992-98

June 1995, Volume 36, Number 6

1210 Interhemispheric Subdural Hematoma in Adults: Case Reports and a Review of the Literature Case Report

AUTHOR(S): Bartels, Ronald H.M.A., M.D.; Verhagen, Wim I.M., M.D., Ph.D.; Prick, Mathé J.J., M.D., Ph.D.; Dalman, Johanna E., M.D.

Department of Neurology, Canisius Wilhelmina Hospital, Nijmegen, The Netherlands

Neurosurgery 36; 1210-1214, 1995

ABSTRACT: THE INTERHEMISPHERIC SUBDURAL hematoma is a relatively uncommon type of subdural hematoma, especially seen in patients with blood clotting disturbances. When its mass becomes sufficiently large, specific neurological abnormalities such as hemiparesis and signs of the falx syndrome are seen. Treatment can consist of conservative observation or craniotomy and is dictated by the clinical course. Conservative management is the treatment of choice for patients without disturbances of consciousness and for patients with stable clinical conditions. Surgical treatment is necessary in patients with progressive deterioration. Three case reports are presented, as well as a review of 64 cases described in the literature. The salient aspects of this clinical entity are discussed.

KEY WORDS: Blood coagulation; Computer-assisted tomography; Interhemispheric; Subdural hematoma

The interhemispheric subdural hematoma (ISH) in adults is a rare type of subdural hematoma. Since the first description by Aring and Evans in 1940⁽¹⁾, only 64 cases have been described in detail^(1-4,6-8,10-16,18-23,25-46,48-50). Zimmerman et al.⁽⁵²⁾ described the brain computed tomography (CT) findings, but not the clinical features, of 25 adult patients. Particularly because of its location, the ISH is considered to be a distinct entity. Recent experience with three patients prompted us to carefully review the literature.

CASE REPORTS

Patient 1

Four days before admission, a 78-year-old woman struck her head during a fall. One day later, she noticed difficulties with walking. Over the next 3 days, these complaints gradually progressed. Twelve hours before admission, she also noticed problems with talking and speech. These symptoms also worsened. She was using an oral anticoagulant agent and 0.125 mg of Lanoxin (Burroughs Wellcome, Research Triangle Park, NC) daily because of atrial fibrillation.

At admission, her consciousness was undisturbed. She had symptoms of nuchal rigidity and was suffering from dysphasia. Except for right central facial paresis, no other signs of cranial nerve

involvement were present. Her right arm and leg were equally paretic (motor strength = 1/5, Medical Research Council scale). Stretch reflexes were exaggerated on both sides with a right extensor plantar reflex.

Laboratory examinations were within normal values except for an International Normalized Ratio of 3.9. Electrocardiography showed atrial fibrillation.

CT revealed a left ISH extending over the falx toward the tentorium (*Fig. 1*). Two weeks after admission, this had completely resolved.

It was decided to conservatively manage the patient. Immediately after admission, she received medication to counteract the anticoagulant agent. No changes were observed for 2 weeks. After this period, gradual improvement was noticed in her speech and in her right arm strength. Three days later, there was also improvement in her right leg. Six weeks after admission, she was able to walk without any assistance. She was discharged to her own home and regained the ability to perform almost all of her normal activities.

Patient 2

A 70-year-old woman was recovering from an intracerebral hemorrhage in the right internal capsule 112 days before admission. Ten hours before admission, she fell out of bed and hit her head. She had amnesia regarding this event, but it was uncertain whether she had lost consciousness. Afterwards, she complained of right-sided headaches. She vomited several times and noticed progressive gait disturbance, which deteriorated so that she was no longer able to walk, even with assistance. Her medications were 100 mg of acetylsalicylic acid daily and 20 mg of isosorbide dinitrate thrice daily. At admission, she was fully alert. The cranial nerves were intact, except for a left central facial paresis and a slight deviation of the tongue to the left. She had left hemiparesis involving the leg (3/5) more than the arm (4/5), which was more pronounced than it was before the fall (arm and leg, 4/5). On both sides, brisk stretch reflexes and positive Hoffmann's, Trömner's, and extensor plantar reflexes were seen. There was no sensory loss.

The results of laboratory investigations were within normal limits. CT was compatible with a dense interhemispheric collection of fresh blood on the right side. A minimal amount of blood was also seen in the subarachnoid space (right sylvian fissure).

We decided to conservatively manage the patient. Three weeks after admission, the ISH had almost completely resolved; 2 weeks later, the results of the CT were unremarkable. In the meantime, the patient's muscle strength had gradually increased. After 3 months, she was able to walk with the assistance of two persons, and after 6 months, she was able to walk alone.

Patient 3

A 75-year-old man had been complaining of headaches for 2 weeks and was admitted because of a decreasing level of consciousness that had started the day before. On that day he had fallen twice. He had

been using an oral anticoagulant agent because of a myocardial infarction 6 weeks before. At admission, he was also suffering from nausea and vomiting and was stuporous. Cranial nerve functions were undisturbed. He had mild (4/5) hemiparesis on the right side. The arm stretch reflexes were symmetrical and normal, whereas the right patellar reflex was exaggerated. He had a flexor plantar response on the left side and an equivocal response on the right.

The results of laboratory examinations were within normal limits except for an International Normalized Ratio of 5.0. CT was compatible with an acute ISH on the left side within a more chronic subdural hematoma, because "pseudomembranes" were present (Fig. 2). The oral anticoagulant was stopped and antagonized immediately. His clinical condition very rapidly deteriorated. However, his relatives refused surgical treatment, and 22 hours after admission, he died. Autopsy was not permitted.

DISCUSSION

Incidence

The exact incidence of ISHs is unknown. Only 67 adult patients, including our patients, have been described in detail^(1-4,6-8,10-16,18-23,25-46,48-50). The male-to-female ratio in adult patients was 1.87:1. In both sexes, ISHs occurred most often in the 6th, 7th, and 8th decades (Fig. 3). The incidence in children might be much higher than in adults because of child abuse by shaking; Zimmerman et al.⁽⁵¹⁾ found ISHs in 17 of 28 children.

Pathogenesis

Preceding head trauma was mentioned in 61 ISH cases (91.0%). In two cases, the ISH occurred spontaneously; in two cases, it was caused by a ruptured intracranial aneurysm, and in the remaining two cases, no underlying mechanism was mentioned. The site of impact of the head trauma in 7 cases was frontal, in 18, occipital, in 3, vertex, and in 2, parietal, and it was not mentioned in the remaining cases.

In Table 1, accompanying factors or diseases are shown. One of the patients in whom the ISH spontaneously appeared had hemophilia B⁽⁴⁰⁾; the other had been using an oral anticoagulant agent for arteritis⁽²³⁾, whereas another patient had been using an anticoagulant agent for cardiological reasons⁽²²⁾.

The generally accepted causative mechanism for the development of ISHs is tearing of the fixed bridging veins between the medial cerebral cortex and the superior sagittal sinus. Torsion forces are known to be important, which is in accordance with the high incidence of frontal and occipital sites of impact. Tight connection of the arachnoid trabeculae between the brain and the parasagittal dura prevents further extension of a fresh clot to the ipsilateral subdural space over the convexity^(6,11,19,21,23,48,52). If a solid clot liquefies, it may migrate into the space over the convexity and behave like a chronic subdural hematoma, as has been demonstrated by Ogsbury et al.⁽³⁴⁾.

Signs and symptoms

The symptoms of the patients with ISHs included

disturbances of consciousness (38.8%), hemiparesis (55.2%), monoparesis of the contralateral leg (10.5%), epileptic manifestations (generalized, 11.9%, and focal seizures, 3.0%), gait ataxia (3.0%), dementia (6.0%), language disorders (4.5%), and oculomotor nerve dysfunction (3.0%). The characteristic falx syndrome, consisting of contralateral hemiparesis affecting the leg much more than the arm, was present in 62.2% of the patients with hemiparesis. None of the patients were symptom free.

Many patients (23 of 60) were admitted within 24 hours after the trauma or onset of symptoms; 53 patients were admitted within 1 week, and for 7 patients, the time interval was not reported.

Neuroradiology

Plain cranial radiographs were taken in 18 patients; a cranial fracture was detected in only 5 patients (27.8%). The frequency of cranial fractures in patients with subdural hematomas reported in the literature varies from 38 to 77%^(5,9,17).

For many years, cerebral angiography was the diagnostic tool of choice. Characteristic features on the anterior-posterior view are an avascular space between the falx and the medial surface of the brain and a separation of the right and left callosal marginal branches above the free edge of the falx, if both anterior cerebral arteries are opacified^(3,41). Cerebral arteriography was performed in 28 patients and suggested a space-occupying lesion in the interhemispheric subdural space.

CT has now replaced cerebral angiography. Angiography is mandatory only in nontraumatic ISHs⁽³⁵⁾. CT was performed on 55 patients (82.1%). In accordance with the series of Zimmerman et al.⁽⁵²⁾, hyperdensity in the interhemispheric fissure was seen in most patients (87.3%). Several conditions may cause hyperdensity in the interhemispheric fissure, including a normal falx, dural calcification, a subarachnoid hemorrhage, a subdural hematoma, and, in children, diffuse cerebral edema⁽⁵²⁾. Hypodensity and isodensity were each described once^(23,36). Pseudomembranes in an ISH, such as those observed in Patient 3, were described once⁽²³⁾. In three patients, the CT findings were not reported in detail.

The right and left interhemispheric subdural spaces were affected equally. Bilateral ISHs were rare. Only three cases have been described in detail^(6,28,48), although Zimmerman et al.⁽⁵²⁾ described the CT scans of another three cases.

Treatment and outcome

Surgical treatment, including craniotomies (30 of 46 patients) and burr holes (13 of 46 patients), was performed on 46 patients, and in 3 patients, the surgical treatment was not specified. The remaining 21 cases were conservatively managed (Table 2).

Conservative management and surgical intervention have been equally advocated. If the neurological condition of the patient is stable or if any accompanying diseases contraindicate surgery, conservative therapy is generally preferred. For the whole group of patients, the mortality rate after

conservative management was lower than that after surgical treatment (10.5% and 31.7%, respectively). The difference in outcome did not reach statistical significance ($\chi^2 = 5.8572$; $P = 0.1188$). However, the clinical conditions of the patients who were surgically treated were worse than those of the group who were conservatively treated. Twenty-five patients who underwent surgery experienced disturbed consciousness of fairly long duration preoperatively, whereas only five of the conservatively managed patients had clouded consciousness (Table 3). Similar proportions of patients without long-term clouding of the consciousness were treated conservatively or surgically. The outcomes were similar. The level of consciousness immediately after the traumatic event did not have any influence on the outcome of surgical or conservative treatment (Table 4). Craniotomies and burr holes resulted in similar outcomes. From these data, it is not possible to conclude which treatment is best for ISHs. It is clear that more patients with disturbed consciousness undergo operations. More detailed information on the level of consciousness of these patients is necessary to make a good comparison.

Some authors say that surgery is always warranted, irrespective of the clinical condition of the patient, whereas others only advocate surgery if the clinical condition deteriorates. On the basis of personal experience and our review of the literature, we advise conservative management for patients without consciousness disturbances and for patients in stable clinical conditions at admission. However, if there is any deterioration, especially in consciousness (Patient 3), surgery should be immediately performed.

The overall mortality was 15 of 61 patients, or 24.6% (in 6 patients, the outcome was not mentioned). When only acute and subacute ISHs (traumatic event within the past 10 days) were considered, the mortality increased to 15 of 56 patients or 26.8%. This is lower than the lowest mortality rate described for traumatic acute subdural hematoma, which ranged from 30 to 90%^(24,47). In the latter studies, the patients underwent aggressive surgical treatment. Acute and subacute ISHs seem to be more "benign" forms of acute subdural hematoma.

Received, June 3, 1994.

Accepted, November 11, 1994.

Reprint requests: W.I.M. Verhagen, M.D., Ph.D., Department of Neurology, Canisius Wilhelmina Hospital, Weg door Jonkerbos 100, 6532 SZ Nijmegen, The Netherlands.

REFERENCES: ⁽¹⁻⁵²⁾

1. Aring CD, Evans JP: Aberrant location of subdural hematoma. **Arch Neurol Psychiatry** 44:1296-1306, 1940.
2. Borzone M, Rivano C, Capuzzo T, Altomonte M: Interhemispheric subdural hematoma: Case report. **Zentralbl Neurochir** 47:354-361, 1986.
3. Campbell JA, Campbell RL: Angiographic diagnosis of traumatic head and neck lesions. **JAMA** 175:761-768, 1961.
4. Clein LJ, Bolton CF: Interhemispheric subdural haematoma: A case report. **J Neurol Neurosurg Psychiatry** 32:389-392, 1969.
5. Cooper PR, Ho V: Role of emergency skull x-ray films in the evaluation of the head-injured patient: A retrospective study. **Neurosurgery** 13:136-140, 1983.
6. Cronin TG, Shippey DU: Bilateral interhemispheric subdural hematoma: A case report. **AJNR Am J Neuroradiol** 8:909-910, 1987.
7. Delfini R, Santoro A, Innocenzi G, Ciappetta P, Salvati M, Zamponi C: Interhemispheric subdural hematoma (ISH): Case report. **J Neurosurg Sci** 35:217-220, 1991.
8. Drábek P, Kuba J, Woln< E: Interhemisferálnífi subdurálnífi hematom. **Cesk Neurol Neurochir** 47:268-272, 1984.
9. Echlin FA, Sordillo SVR, Garvey TQ Jr: Acute, subacute, and chronic subdural hematoma. **JAMA** 161:1345-1350, 1956.
10. Esposito DP, Devkota J, El Gammal T, Sullivan HG: Interhemispheric subdural hematoma. **South Med J** 77:379-381, 1984.
11. Fearnside MR, Hall K, Sengupta RP: Interhemispheric subdural haematoma following head injury. **Aust N Z J Surg** 49:678-680, 1979.
12. Fein JM, Rovit RL: Interhemispheric subdural hematoma secondary to hemorrhage from a callosal-marginal artery aneurysm. **Neuroradiology** 1:183-186, 1970.
13. Friedman MB, Brant-Zawadzki M: Interhemispheric subdural hematoma from ruptured aneurysm. **Comput Radiol** 7:129-134, 1983.
14. Fruin AH, Juhl GL, Taylon C: Interhemispheric subdural hematoma: Case report. **J Neurosurg** 60:1300-1302, 1984.
15. Fukamachi A, Wakao T, Kawafuchi J: Limitation of admission CT in acute head injury: Report of three autopsy cases. **No Shinkei Geka** 9:349-355, 1981.
16. Furui T, Iwata K, Usui K: Interhemispheric subdural haematoma complicated by intracerebral haematoma: Case report. **Acta Neurochir (Wien)** 91:139-141, 1988.
17. Galbraith S, Smith J: Acute traumatic intracranial haematoma without skull fracture. **Lancet** 1:501-503, 1976.
18. Gannon WE: Interhemispheric subdural hematoma: Case report. **J Neurosurg** 18:829-830, 1961.
19. Gartman JJ Jr, Atstupenas EA, Vollmer DG, Powers SK: Traumatic laceration of pericallosal artery resulting in interhemispheric subdural hematoma: A case report. **J Emerg Med** 7:603-610, 1989.
20. Gentile SL, Rivano C, Rosa M, Viale GL: Sugli ematomi sottodurali acuti interemisferici. **Rass Arch Chir** 7:165-170,

- 1969.
21. Glista GG, Reichman OH, Brumlik J, Fine M: Interhemispheric subdural hematoma. **Surg Neurol** 10:119-122, 1978.
 22. Ho SU, Spehlmann R, Ho HT: CT scan in interhemispheric subdural hematoma: Clinical and pathological correlation. **Neurology** 27:1097-1098, 1977.
 23. Houtteville JP, Toumi K, Theron J, Derlon JM, Benazza A, Hubert P: Interhemispheric subdural haematomas: Seven cases and review of the literature. **Br J Neurosurg** 2:357-367, 1988.
 24. Howard MA III, Gross AS, Dacey RG Jr, Winn HR: Acute subdural hematomas: An age-dependent clinical entity. **J Neurosurg** 71:858-863, 1989.
 25. Isfort A: Angiographische Befunde beim Hämatom und Empyem im Interhemisphärenspalt. **Fortschr Geb Röntgenstr** 107:127-130, 1967.
 26. Izawa M, Takahashi K, Sentoh S: A case of interhemispheric subdural hematoma associated with thrombocytopenia. **No Shinkei Geka** 10:557-560, 1982.
 27. Jacobsen HH: An interhemispherically situated haematoma: Case report. **Acta Radiol** 44:235-236, 1955.
 28. Kasdon DL, Magruder MR, Stevens EA, Paullus WS: Bilateral interhemispheric subdural hematomas. **Neurosurgery** 5:57-59, 1979.
 29. Koyama S, Nishimura T: A case of bilateral interhemispheric subdural hematoma. **No Shinkei Geka** 18:289-294, 1990.
 30. Kusunoki T, Nogaki H, Masurama M: Traumatic (para) interhemispheric hematoma. **Prog CT (Tokyo)** 2:433-435, 1980.
 31. Lusins JO, McChesney JD: Nonsurgical management of an isolated interhemispheric subdural hematoma sequentially followed by CT. **Mt Sin J Med** 56:68-70, 1989.
 32. Nagasawa S, Ohtsuki H, Nagayasu S, Kikuchi H: Acute interhemispheric subdural hematoma: A case report with good result by small craniotomy during the chronic stage. **No Shinkei Geka** 18:643-646, 1990.
 33. New PFJ, Scott WR, Schnur JA, Davis KR, Taveras JM: Computerized axial tomography with the EMI scanner. **Neuroradiology** 110:109-123, 1974.
 34. Ogsbury JS, Schneck SA, Lehman RAW: Aspects of interhemispheric subdural haematoma, including the falx syndrome. **J Neurol Neurosurg Psychiatry** 41:72-75, 1978.
 35. Pozzati E, Gaist G, Vinci A, Poppi M: Traumatic interhemispheric subdural hematomas. **J Trauma** 22:241-243, 1982.
 36. Pujadas F, Ricart C, Oliveras C, Pou A: Hematoma subdural agudo interhemisférico. **Rev Clin Esp** 179:70-71, 1986 (letter).
 37. Russell NA, del Carpio-O'Donovan R, Mallya KB, Benoit BG, Belanger G: Interhemispheric subdural hematoma. **Can J Neurol Sci** 14:172-174, 1987.
 38. Samii M, Schindler E, Hey O: Ein subdurales Hämatom des Interhemisphärenspalts. **Acta Neurochir (Wien)** 30:319-326, 1974.
 39. Satoh T, Yamamoto Y, Asari S, Sadamoto K: Traumatic interhemispheric subdural hematoma: Report of a case and analysis of 7 cases. **No Shinkei Geka** 10:667-672, 1982.
 40. Shigemori M, Kawaba T, Shirahama M, Tokutomi T, Hara K: Acute interhemispheric subdural hematoma: Report of 2 cases. **No Shinkei Geka** 10:647-652, 1982.
 41. Sibayan RQ, Gurdjian ES, Thomas LM: Interhemispheric chronic subdural hematoma: Report of a case. **Neurology** 20:1215-1218, 1970.
 42. Takeda N, Kurihara E, Matsuoka H, Kose S, Tamaki N, Matsumoto S: Three cases of acute interhemispheric subdural hematoma. **No Shinkei Geka** 16:87-92, 1988.
 43. Tietjen DP, Moore J Jr, Gouge SF: Hemodialysis-associated acute subdural hematoma: Interim management with peritoneal dialysis. **Am J Nephrol** 7:478-481, 1987.
 44. Tijssen CC, Tavy DLJ, Hekster REM, Bots GTAM, Endtz LJ: Aphasia with a left frontal interhemispheric hematoma. **Neurology** 34:1261-1264, 1984.
 45. Toffol GJ, Biller J, Adams HP Jr: Interhemispheric subdural hematoma. **J Emerg Med** 4:103-107, 1986.
 46. Vilalta J, Sahuquillo J, Rubio E: Hematoma subdural interhemisférico. **Rev Clin Esp** 180:410-411, 1987 (letter).
 47. Wilberger JE Jr, Harris M, Diamond DL: Acute subdural hematoma: Morbidity, mortality, and operative timing. **J Neurosurg** 74:212-218, 1991.
 48. Woimant F, Thurel C, Roux FX, Cremer F, Bertrand HJ, Haguenu M, Houdart R, Pépin B: Hématomes sous-duraux aigus interhémisphériques. **Rev Neurol (Paris)** 139:299-303, 1983.
 49. Wollschlaeger PB, Wollschlaeger G: The interhemispheric subdural or falx hematoma. **Am J Roentgenol** 92:1252-1254, 1964.
 50. Yamagami T, Handa H, Nagasawa S, Nagata H, Chung KJ: Acute interhemispheric subdural hematoma: Case report and review of literature. **Arch Jpn Chir** 56:69-75, 1986.
 51. Zimmerman RA, Bilaniuk LT, Bruce D, Schut L, Uzzell B, Goldberg HI: Interhemispheric acute subdural hematoma: A computed tomographic manifestation of child abuse by shaking. **Neuroradiology** 16:39-40, 1978.
 52. Zimmerman RD, Russell EJ, Yurberg E, Leeds NE: Falx and interhemispheric fissure on axial CT: Part II--Recognition and differentiation of interhemispheric subarachnoid and subdural hemorrhage. **AJNR Am J Neuroradiol** 3:635-642, 1982.

COMMENTS

The authors have provided three case reports of patients with interhemispheric subdural hematomas, as well as a comprehensive review of the current literature. The uniqueness of interhemispheric subdural hematomas in the general context of acute subdural hematomas is emphasized. Interhemispheric subdural hematomas primarily are a disease of the elderly. They primarily occur as a result of low velocity impacts, and in two-thirds of the reported cases, their occurrence has been associated with various bleeding disturbances (i.e., anticoagulation). Although a mortality rate of 25% as quoted by the authors would seem to be generally low for acute subdural hematomas, those patients with interhemispheric subdural hematomas and altered levels of consciousness actually had a 42% mortality rate. The authors' cogent review of the incidence, pathogenesis, signs and symptoms, neuroradiological features, treatments, and outcomes from interhemispheric subdural hematomas in adults should be of interest to all who treat head trauma.

Jack E. Wilberger

Pittsburgh, Pennsylvania

The authors have reported 3 cases of their own and have reviewed the reports to date on 64 other cases of interhemispheric subdural hematomas in adults. The article provides much useful information, including the high incidence of this condition in patients with bleeding disorders and in patients taking oral anticoagulants. The data show that many of these patients can be conservatively managed, although patients with clouding of consciousness or deteriorating neurological deficits require surgical treatment.

Charles H. Tator

Toronto, Ontario, Canada

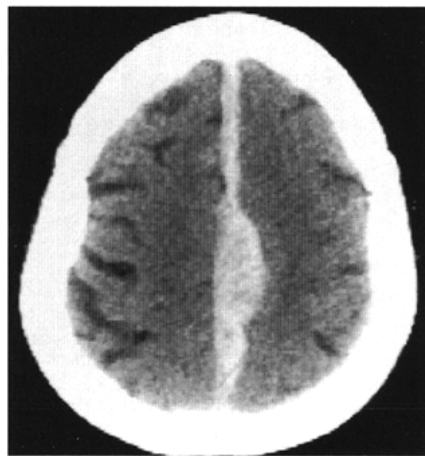


Figure 1. CT without contrast at admission showing an ISH on the left side.

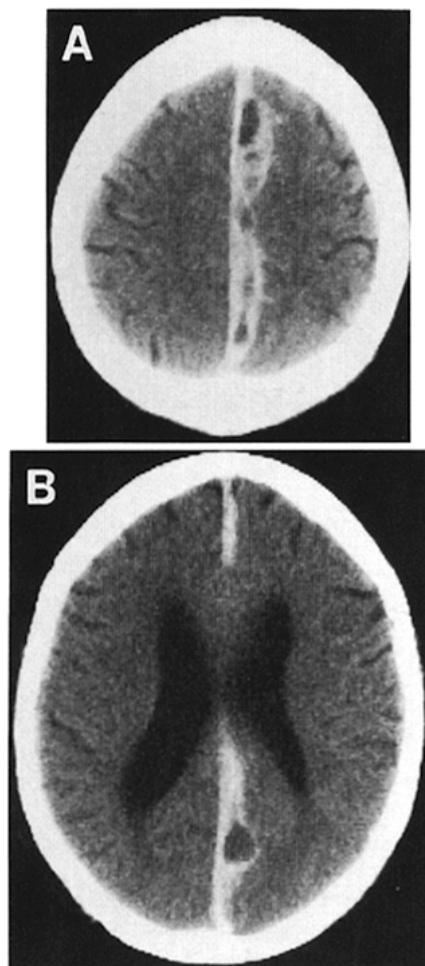


Figure 2. *A* and *B*, CT without contrast at admission disclosing a left-sided ISH with compartments of various densities and "pseudomembranes" compatible with a recent hemorrhage in a more chronic ISH.

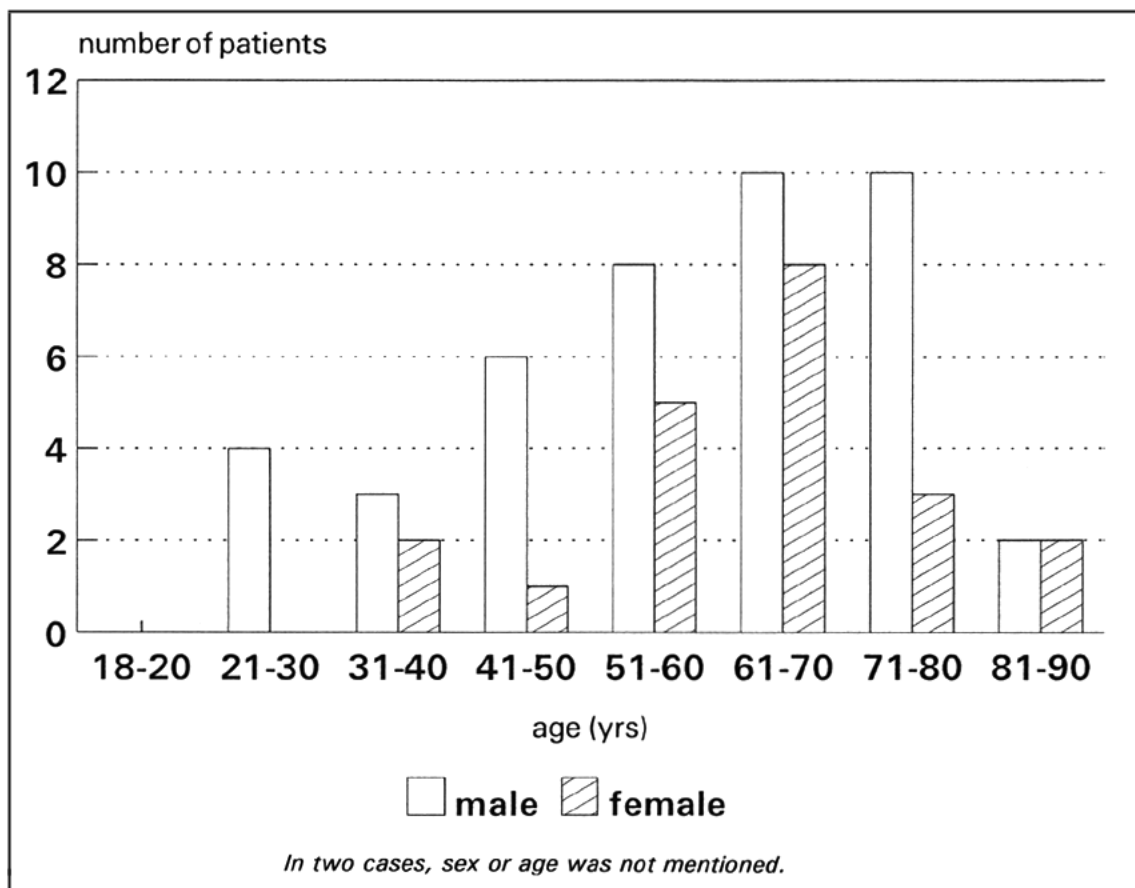


Figure 3. Distribution of age related to sex.

Disease or Factor	No. of Cases
Alcoholism	7
Bleeding diathesis	
von Willebrand's disease	1
Hemophilia B	1
Thrombocytopenia	1
Oral anticoagulants	14
Hydrocephalus caused by aqueduct stenosis	2
Hypertension	4
Chronic renal failure	2
Total	32

Table 1. Accompanying Diseases or Factors in 67 Patients with Interhemispheric Subdural Hematoma

Treatment	Recovery		Dead	Total
	Complete	Incomplete		
Surgery				
Craniotomy	16	2	9	27
Burr holes	7	2	4	13
Unspecified	2			2
Subtotal	25	4	13	42
Conservative	14	3	2	19
Total	39	7	15	61
(%)	63.9%	11.5%	24.6%	100%

^a Outcome not mentioned in six cases.

Table 2. Treatment versus Outcome^a

	Outcome			Total
	Complete Recovery	Incomplete Recovery	Dead	
Clouding				
Surgery	12	2	10	24
Conservative	1	2	2	5
No clouding				
Surgery	13	2	2	17
Conservative	13	1		14
Total	39	7	14	60

^a In six cases the outcome was unknown, whereas in one case clouding was unknown.

Table 3. Outcome in Relation to Long-term Clouding of the Consciousness and Therapy^a

	Outcome			Total
	Complete Recovery	Incomplete Recovery	Dead	
Loss of consciousness				
Surgery	11	2	2	15
Conservative	6	2	1	9
No loss of consciousness				
Surgery	11	2	8	21
Conservative	7	1	1	9
Total	35	7	12	54

^aIn six cases the outcome was unknown, whereas in another seven cases loss of consciousness was unknown.

Table 4. Correlation between Loss of Consciousness at the Event Responsible for the Development of Interhemispheric Subdural Hematoma (Initial Loss of Consciousness) and the Outcome of Therapy^a