

Adrenal tumour, congestive heart failure and hemiparesis in an 18-year-old male. A clinical-pathological conference

Ravinder Goswami^a, Nikhil Tandon^a, Balbir Singh^b, N. Kochupillai^{*a}

^a*Department of Endocrinology, All India Institute of Medical Sciences, New Delhi 110029, India*

^b*Department of Cardiology, All India Institute of Medical Sciences, New Delhi 110029, India*

Abstract

A case of a young male presenting with mild hypertension, congestive cardiac failure, stroke in the distribution of the left middle cerebral artery and a right suprarenal mass is discussed. Diagnostic and therapeutic strategies are presented.

Keywords: Pheochromocytoma; Catecholamines; Cardiomyopathy; Hypertension; Stroke

1. Case presentation

Patient I.S., an 18-year-old male, was referred to the endocrine services of the hospital for evaluation of sudden onset right side hemiparesis of 2 months duration and recently detected right suprarenal mass on radiological imaging.

Detailed history and records of past treatment revealed that he was detected to be hypertensive (blood pressure 150/100 mmHg) 1 month prior to the onset of neurological complaints when he was examined for a transient febrile illness which responded to treatment with antipyretics alone. No detailed investigation or treatment was advised and the patient returned to his usual work schedule involving farming. However, he started having dyspnoea on exertion, although he could continue working, and next received medical attention only after he suffered sudden onset right

hemiparesis and motor dysphasia. Blood pressure was recorded to be 150/96 mmHg. His serum electrolytes were within the normal range. Computerised tomography (CT) revealed a low density region in the left parietal area suggestive of infarct. Abdominal ultrasonography and CT imaging was undertaken. Following detection of a 4 × 4 cm right suprarenal mass with areas of central necrosis and peripheral enhancement, the patient was referred to us for further management. The patient denied past history of headache, palpitation, sweating and weight loss. There was no family history suggestive of thyroid swelling, neurofibromatosis or systemic hypertension.

Examination on the day of admission revealed an orthopneic patient with a regular pulse rate of 112/min, respiratory rate of 24/min and blood pressure of 150/100 mmHg. There was minimal ankle oedema. Jugular venous pressure was 10 cm above the sternal angle with no definite wave prominence. Fundus examination revealed features of

* Corresponding author.

grade II hypertensive retinopathy. Bi-basilar moist rales were auscultated on chest examination. Cardiovascular examination revealed apex beat in the fifth intercostal space and in the anterior axillary line. On auscultation, first and second heart sounds were normal, a left ventricular third heart sound was heard at the apex. However, there were no audible murmurs. Central nervous examination revealed right sided hemiparesis with muscle power of four/five and motor dysphasia. Abdominal examination was unremarkable and no fluctuations in the blood pressure were noticed during and after the palpation. No features of Cushing's syndrome were observed. Investigations revealed hemoglobin of 12 g%, total leukocyte count of $14\,300/\text{mm}^3$ with 64% neutrophils, hematocrit of 32, blood urea of 52 mg%, serum creatinine of 1.6 mg%, serum Na^+ of 140 mEq/l and serum K^+ of 3.7 mEq/l. X-ray chest PA view revealed gross cardiomegaly with cardiothoracic ratio of 0.60 and moderate degree of pulmonary venous hypertension. Electrocardiogram demonstrated sinus tachycardia and left ventricular hypertrophy. Urinary Na^+ and K^+ was 33 and 37 mEq/l, respectively. Twenty-four hour urinary VMA was 5.6 mg (normal range 1.8–7.1 mg) and values for bioassayed urinary catecholamines, collected on different days, were 23, 17, and 12.5 $\mu\text{g}\%$ (normal $<30\,\mu\text{g}/24\,\text{h}$). Assay for antinuclear factor and antineutrophil cytoplasmic antibodies were negative. Sera was preserved for paired viral titre estimation.

The patient was put on bed rest and decongested with furosemide and digoxin. Mild hypertension was treated with nifedipine.

2. Differential diagnosis

Dr N. Kochupillai: To summarise, patient is a young male who had suffered hemiparesis due to infarct in the territory of left middle cerebral artery and presented to us with congestive heart failure and mild hypertension. In addition he had an im-
agable lesion of the right adrenal gland in absence of electrolyte abnormalities and repeatedly normal urinary catecholamines and VMA levels. To explain the clinical presentation of hypertension, congestive heart failure, hemiparesis and adrenal

mass with a single diagnosis, we would strongly consider secondary hypertension based heart failure and embolic stroke. Hypertension in presence of an adrenal mass could be because of adrenocortical lesions such as a cortisol producing tumour or Conn's syndrome, or it may be due to a medullary tumour such as pheochromocytoma. Rarely, cardiac involvement may be because of the direct impact of the excess catecholamines secreted by the pheochromocytoma. Minimal impairment in kidney functions could be due to long standing hypertension or secondary to renovascular spasm because of local high concentration of catecholamines. In view of the persistently normal serum electrolytes and urinary catecholamines observed in this patient, possibility of adrenal incidentaloma (nonfunctioning inconsequent, benign adrenal lesion visible on imaging in up to 10% of the normal population) may be considered [1]. Rheumatic heart disease with embolic stroke is another possibility in view of its common occurrence in our country. Also the possibility of viral myocarditis cannot be ruled out, particularly in view of the antecedent history of febrile illness. However, the last two diagnoses would leave the hypertension observed in this patient unexplained.

Considering the young age of the patient with features of long standing and severe hypertension on fundoscopy and electrocardiogram, I would like to investigate further before dismissing the adrenal lesion as an incidentaloma. Colour Doppler echocardiography and more reliable investigation for pheochromocytoma such as high pressure liquid chromatography (HPLC) based catecholamines assay may give the clue.

Dr Balbir Singh: Two dimensional colour Doppler echocardiography revealed enlarged left ventricle and left atrium without any clot (Fig. 1). The left ventricular dimensions were: end diastolic and end systolic, 65 mm/m² and 50 mm/m², respectively. The left ventricular volumes as estimated by area length method were: end diastolic and end systolic, 194 and 125 ml, respectively. All four valve leaflets were normal and left ventricular wall thickness was not increased. Global hypokinesia was seen and calculated ejection fraction was 32%. Radioangiocardiology also confirmed global hypokinesia and poor ejection fraction (30%). On

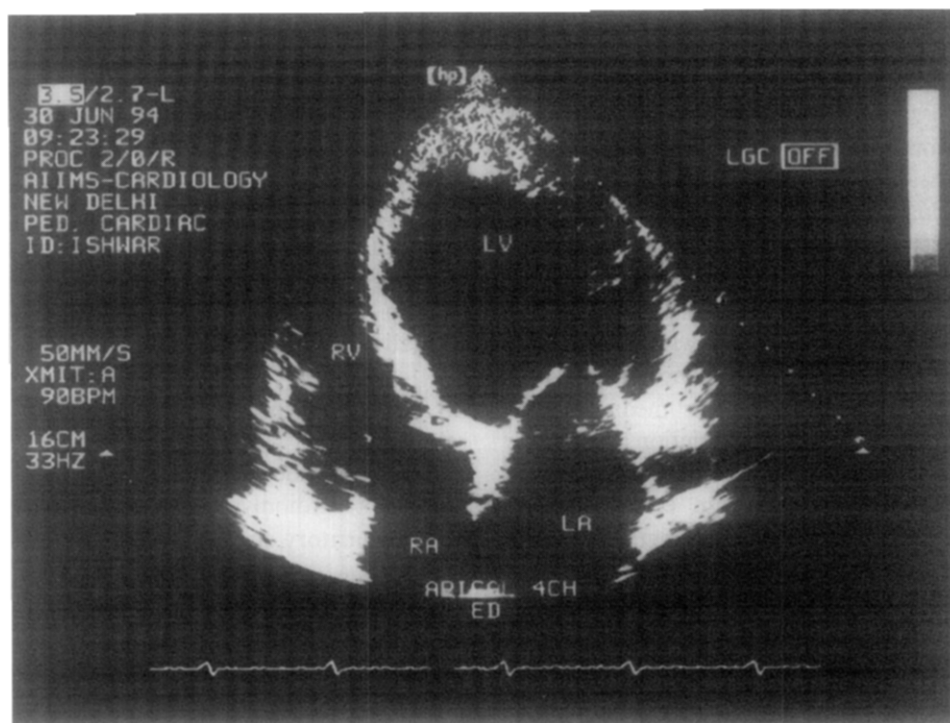


Fig. 1. Two-dimensional echocardiography, apical four chamber view showing end diastolic frame with markedly dilated and clear left ventricular cavity.

colour flow imaging mild mitral regurgitation was detected. Normal valve morphology makes rheumatic etiology unlikely. However, these features of dilated cardiomyopathy do not exclude causes such as catecholamine cardiomyopathy and viral myocarditis.

Dr Kochupillai: Dr Tandon, would you like to comment regarding the diagnostic possibilities in this case?

Dr Nikhil Tandon: I agree with the suggestions of Dr Balbir Singh. Though rare, pheochromocytoma with catecholamine induced cardiomyopathy is a more likely possibility in this case rather than hypertensive heart disease, in view of the dilated ventricles and absence of ventricular wall thickness on echocardiography. Echocardiographic studies in patients with pheochromocytoma have reported both dilated and hypertrophic ventricles [2,3] and ejection fraction

as low as 16% [4]. In this clinical setting, infarct in the territory of left middle cerebral artery could be either consequent to a detached cardiac thrombus, or as a result of vasospasm of the cerebral vessels. Cerebral vasospasm can be either due to excess catecholamines or secondary to the other secretory products of the adrenal tumour such as neuropeptide-Y [5]. In fact, cerebral infarct and gangrene of the extremities secondary to vasospasm has been reported in some patients with pheochromocytoma [6,7].

Hypertension per se can also result in infarct in patients with pheochromocytoma. However, such lesions are more widespread, unlike the infarct restricted to distribution of middle cerebral artery noticed in the presented case. Moreover, such hypertension is usually of malignant severity. Only mild hypertension was recorded in the presented case. Surprisingly mild hypertension noticed in

presence of fundus and electrocardiogram changes of severe and long standing hypertension is in all probability related to dysfunctions in cardiac contractility. Here, I would also like to add that certain pheochromocytomas may have normotension unrelated to cardiac dysfunction.

Dr Kochupillai: It is true that few workers have reported normotension and even hypotension in patients with pheochromocytoma due to mechanisms different from cardiac involvement. Hypotension is characteristically noticed with predominantly adrenaline producing pheochromocytomas [8,9]. This hypotensive effect is mediated by excessive beta adrenergic stimulation, reduced peripheral resistance and vasodilation. In addition tumour tissue may also secrete certain other vasodilator substances such as vaso-active intestinal peptide and calcitonin gene related peptide [10,11]. However, such production of abnormal vasodilators is often associated with watery diarrhea, achlorhydria and hypokalemia [10,11].

Dr Balbir Singh: Dr Goswami, may we have the report of the HPLC based catecholamine assay and its significance with reference to the earlier obtained catecholamine values (bio-assay based)?

Dr R Goswami: The patient's 24-h urinary VMA and catecholamine values were within the normal range. Such normal catecholamine levels however, do not exclude pheochromocytoma from the list of diagnostic possibilities. Large tumours may metabolise a substantial amount of catecholamines and secrete less in the biologically active form in the urine. Tumour necrosis can also result in spontaneous remission of the clinical symptoms and normal urinary catecholamines in patients with pheochromocytoma. Such necrosis could be either haemorrhagic or avascular. Eight such patients have been reported in the literature up to 1993 [12]. Necrosis is often preceded by a clinical picture of acute abdominal emergency, hypertensive crisis, hypotension and cardiac dysfunction. In the presented case CT image of the tumour demonstrated central necrosis. This may well be the cause of his normal urinary catecholamines. Other factors which can explain normal urinary catecholamines include episodic secretion of the pheochromocytoma and different sensitivity and specificity of assay methods. Fractionated

catecholamines assay using HPLC [13] has the highest sensitivity (>95% at norepinephrine cut-off levels of 170 µg /24 h). In the presented case when the estimation was done using HPLC, 24-h urinary noradrenaline was 390 µg/g creatinine (normal range 8.9–61.6 µg/g creatinine). Urinary adrenaline and dopamine values were within the normal range.

Microimmunofluorescence test for Cosackie B group virus antibodies in the paired sera was negative.

3. Clinical diagnosis

Pheochromocytoma with catecholamine-induced cardiomyopathy and middle cerebral artery territory stroke.

4. Clinical discussion

Dr Nikhil Tandon: Dr Balbir, could you please let us know the cardiac involvement in pheochromocytoma, more specifically the entity of catecholamine cardiomyopathy?

Dr Balbir Singh: A large number of patients dying with pheochromocytoma demonstrate changes in the myocardium on autopsy. However, clinical evidence of myocardial dysfunction is rarely observed [7]. In fact, susceptibility to develop such changes seems unpredictable as there are cases with normal cardiac function even in presence of ectopically located tumours found well inside the heart chambers [14].

Occurrence of cardiomyopathy consequent to the elevated level of catecholamines has been noticed since 1907 [15]. Since then, several cases of dilated and hypertrophic type of cardiomyopathy have been reported in literature.

Endomyocardial biopsy and autopsy studies of patients dying with pheochromocytoma have revealed histopathological features mimicking viral myocarditis. Gross examination of the heart in such studies have revealed subendocardial and intramyocardial haemorrhages [16]. Early lesions are characterised by infiltration with neutrophils, lymphocytes and histiocytes, with small haemorrhages and oedema. Later changes consist of focal degeneration, myofibril necrosis and fibrosis. Elec-

tronmicroscopically hypercontracted sarcomeres, swollen mitochondria and endoplasmic reticulum are observed [17].

Congestive heart failure associated with the cardiomyopathy may present as acute pulmonary oedema [7,18] or it may be mild and have insidious onset. Such a manifestation has been reported even in a patient as young as 12 years of age [4]. Elevated blood pressure may normalise in presence of cardiac dysfunction [8].

Echocardiographic and gated blood pool study after intravenous injection of ^{99m}Tc often show dilatation of the four chambers and hypokinesia of the ventricular walls especially at the apical region. Such changes could also be localized with ^{111}In antimyosin antibody scan and SPECT (single photon emission computed tomography) imaging. These reveal intense uptake at the cardiac apex and diffuse uptake in the remaining position of the left ventricle [6].

Patients presenting with acute cardiogenic pulmonary oedema have significantly high mortality [7]. However, those presenting with slow onset cardiac dysfunction can be successfully managed preoperatively and intraoperatively even with ejection fraction as low as 16% [4].

Dr Goswami: Dr Tandon, could you please comment on the pathogenesis of the catecholamine cardiomyopathy?

Dr Tandon: The pathogenesis of catecholamine induced cardiomyopathy is multifactorial. Depressed myocardial functions are caused by a combination of down regulated beta receptors and a net reduction in viable myofibres [19]. A possible role for catecholamine induced vasospasm of the coronary arteries at the periphery is supported by the fact that the most prominent dysfunction is observed at the apex of the heart [7,18]. In addition, excess catecholamines also induce increased sarcolemmal membrane permeability and calcium influx [20]. Excess calcium ion has a direct toxic effect on myocytes leading to necrosis. Reperfusion injury mediated by free oxygen radicals may occur following vasospasm induced ischemia [21]. Lastly, oxidised intermediate products of catecholamines such as adrenochrome [22] may also injure the myocardium.

Dr Kachupillai: Dr Goswami, could you please

review the preoperative management of the patients with pheochromocytoma especially in a setting of catecholamine cardiomyopathy?

Dr Goswami: Management of these patients involves stabilising congestive heart failure, improving cardiac dysfunction and finally putting them on adrenergic blockade. Adrenergic blockade could be with alpha adrenergic blockers alone or a combination of alpha and beta blockers.

Congestive heart failure is managed by diuretics and digoxin therapy in the usual dosages [4,8]. These drugs are continued in the post-operative period also. No increase in the incidence of arrhythmias has been observed with these drugs. Normotensive patients with dilated cardiomyopathy may demonstrate a hypertensive response after successful management of the congestive state [8].

In an effort to improve cardiac function preoperatively, treatment with a tyrosine hydroxylase inhibitor such as metyrosine has been reported in such patients [4]. Though such treatment improves ejection fraction and reduces circulating catecholamine levels, troublesome side-effects such as oculogyric crises and nephrolithiasis are the limiting factors.

Once the congestive heart failure is stabilised, the patient is usually put on phenoxybenzamine or prazosin, and betablocker is added under careful supervision [6,8].

Dr B. Singh: Dr Tandon, could you please let us know the management undertaken in the presented case?

Dr Tandon: In this patient congestive heart failure was managed with furosemide 20 mg i.v. twice daily and digoxin 0.25 mg once a day orally (5/7 days). Mild hypertension was treated with nifedipine. Angiotensin converting enzyme inhibitors were avoided in view of mild renal dysfunction. The patient had marked diuresis of 5 l over a period of 5 days. However, ejection fraction remained unchanged at 35%. Under careful blood pressure monitoring, tablet prazosin was substituted for nifedipine. Dose of the prazosin was built up to 1 mg twice daily over a period of 1 week.

Patient was referred for surgery 4 weeks after admission. The right adrenal gland containing the tumour was completely resected. An encapsulated

mass weighing 20 g was found with areas of central necrosis. Microscopic examination confirmed the diagnosis of pheochromocytoma. Post-operatively, blood pressure normalised and all drugs except digoxin were withdrawn. One month post-operatively, the patient's impaired kidney function normalised completely. Repeat measurement of 24-h urinary catecholamine (HPLC) revealed values within the normal range (30 µg/g creatinine).

The patient's general well-being improved. However, his neurological deficit persisted. Repeat chest X-ray continued to show an enlarged heart albeit without any perihilar pulmonary congestion. Repeat echocardiography showed an unchanged ejection fraction of 35%. The patient was discharged with advice for monthly follow-up.

Dr Goswami: Dr Kochupillai, what prognosis would you like to give to this patient with regard to the cardiac function?

Dr Kochupillai: In only four of the reported cases of pheochromocytoma with dilated cardiomyopathy, cardiac function has been evaluated before and after surgery. All four reported complete normalisation of cardiac size and ejection fraction after 6, 8, 12 and 18 months respectively [2,4,18,23]. On the basis of these reports it can be said that catecholamine cardiomyopathy is a potentially reversible condition, although recovery is gradual.

References

- [1] Gross MD, Shapiro B. Clinically silent adrenal masses. *J Clin Endocrinol Metab* 1993; 77: 885–888.
- [2] Lam JB, Shub C, Sheps SG. Reversible dilatation of hypertrophied left ventricle in pheochromocytoma: serial two dimensional echocardiographic observations. *Am Heart J* 1985; 109: 613–615.
- [3] Shub C, Williamson MD, Tajik AJ, Eubanks DR. Dynamic left ventricle outflow tract obstruction associated with pheochromocytoma. *Am Heart J* 1981; 102: 286–290.
- [4] Imperato-McGinley J, Gautier T, Ehlers K, Zullo MA, Goldstein DS, Vaughan Jr. ED. Reversibility of catecholamine-induced dilated cardiomyopathy in a child with pheochromocytoma. *N Engl J Med* 1987; 316: 793–796.
- [5] Gray TS, Morley JE. Neuropeptide Y: anatomical distribution and possible function in mammalian nervous system. *Life Sci* 1986; 38: 389–401.
- [6] Samuels MA, Southern JF. A 26-year-old woman with cardiomyopathy, multiple strokes and an adrenal mass. *N Engl J Med* 1988; 318 (15): 970–981.
- [7] Sardesai SH, Maurant AJ, Sivathandon Y, Farrow B, Gibbons DO. Pheochromocytoma and catecholamine-induced cardiomyopathy presenting as heart failure. *Br Heart J* 1990; 63: 234–237.
- [8] Baxter MA, Hunter P, Thompson GR, London DR. Pheochromocytomas as a cause of hypotension. *Clin Endocrinol* 1992; 37: 304–306.
- [9] Smircic L, Suskovic T, Ferencic Z. Pheochromocytoma without hypertension. *J Intern Med* 1994; 235: 373–374.
- [10] Nigawara K, Suzuki T, Tazawa H et al. A case of recurrent malignant pheochromocytoma complicated by diarrhea, hypokalemia achlorhydria syndrome. *J Clin Endocrinol Metab* 1987; 65: 1053–1056.
- [11] Viale G, Dell'Orto P, Moro P, Moro E et al. Vasoactive intestinal polypeptide, somatostatin and calcitonin producing adrenal pheochromocytoma associated with the watery diarrhea (WDHH) syndrome. First case report with immunohistochemical findings. *Cancer* 1985; 55: 1099–1106.
- [12] Zanin L, Rossi G, Poletti A, Chiesura CM, Pessina AC. Necrosis of a pheochromocytoma associated with spontaneous remission of diabetes and hypertension. *Clin Endocrinol* 1993; 39 (5): 613–617.
- [13] Sheps SG, Jiang NS, Klee GG. Diagnostic evaluation of pheochromocytoma. *Endocrinol Metab Clin North Am* 1988; 17: 397–414.
- [14] Jonsson A, Hallengren B, Manhem P, Lilja B, Stavenow L, Stahl E, Tornquist C. Cardiac pheochromocytoma. *J Intern Med* 1994; 236: 93–96.
- [15] Josue O. Hypertrophie cardiaque causee par l'adrenaline et la toxine typhique. *CR Soc Biol (Paris)* 1907; 63: 285–286.
- [16] Haft J. Cardiovascular injury induced by sympathetic catecholamine. *Prog Cardiovasc Dis* 1974; 17: 73–86.
- [17] Ferrans VJ, Hibbs RG, Walse JJ, Burch GE. Histochemical and electron microscopical studies on cardiac necrosis produced by sympathomimetic agents. *Ann NY Acad Sci* 1969; 156: 309–332.
- [18] Elian D, Harpaz D, Sucher E, Kaplinsky E, Motro M, Vered Z. Reversible catecholamine-induced cardiomyopathy presenting as acute pulmonary edema in a patient with pheochromocytoma. *Cardiology* 1993; 83: 118–120.
- [19] Fripp RR, Lee JC, Downing SE. Inotropic responsiveness of the heart in catecholamine cardiomyopathy. *Am Heart J* 1981; 101: 17–21.
- [20] Bloom S, Davis DL. Calcium as mediator of isoproterenol induced myocardial necrosis. *Am J Pathol* 1972; 69: 459–470.
- [21] Singal PK, Kapur N, Dhillion KS, Beamish RE, Dhalla NS. Role of free radicals in catecholamine induced cardiomyopathy. *Can J Physiol Pharmacol* 1982; 60: 1390–1397.
- [22] Rona G. Catecholamine cardiotoxicity. *J Mol Cell Cardiol* 1985; 17: 291–306.
- [23] Wood R, Commerford PJ, Rose AG, Tooke A. Reversible catecholamine-induced cardiomyopathy. *Am Heart J* 1991; 121: 610–613.