

## Vertebral Artery Injury Presenting with Signs of Middle Cerebral Artery Occlusion

### A Case Report

George Sternbach, M.D.  
Michael Cohen, M.D.\*  
and David Goldschmid, M.D.

DALY CITY, CALIFORNIA

---

#### ABSTRACT

Therapeutic manipulation of the neck has been shown to produce injury to the vertebral artery. The clinical syndromes produced by this arterial insufficiency generally reflect dysfunction of the brainstem or cerebellum. The authors present a case of such injury that presented with clinical findings, namely, hemiparesis and aphasia, suggestive of involvement of the dominant middle cerebral artery. These findings may have been the result of disruption of flow through the posterior cerebral artery to the thalamus, internal capsule, and cerebral peduncles.

---

From the Departments of Emergency Medicine and \*Neurology, Seton Medical Center, Daly City, California.

©1995 Westminster Publications, Inc., 708 Glen Cove Avenue, Glen Head, NY 11545, U.S.A.

## Introduction

Vertebral artery injury caused by therapeutic neck manipulation is a well-described syndrome. We recently encountered such a case in which the patient presented with signs suggestive of obstruction of the middle cerebral artery.

### Case Report

The patient was a thirty-year-old right-handed woman who presented to the emergency department with a chief complaint of inability to move the right side of her body. The patient was brought to the hospital by paramedics after having experienced the weakness immediately following a chiropractic manipulation of her neck.

Two weeks prior to this presentation, she had undergone chiropractic manipulation for myofascial neck pain. On that occasion, she had experienced severe neck pain radiating to the back of the head, vertigo, and a general feeling of weakness during the manipulation. These symptoms were transient except for the neck pain, lasting a few minutes after the manipulation was terminated. The persistence of neck pain ultimately caused her to return to the chiropractor on the day of presentation. Cervical manipulation performed by that individual resulted in severe dizziness and right-sided weakness.

The patient had no other history of significant prior medical illness or injury. She had been taking oral contraceptives but was taking no other medications.

On physical examination the vital signs were as follows: blood pressure: 121/85 mm Hg; pulse: 77/minute; respirations: 24/minute; temperature: 36.8°C. The patient was awake and alert. Findings from the initial physical examination were entirely normal except for the following findings on neurologic examination: a dense right hemiparesis involving the upper and lower extremity equally, aphasia, a left gaze preference, and ocular nystagmus to the right. There was no sensory deficit. Deep tendon reflexes were symmetrical throughout, with flexor plantar responses bilaterally.

Radiographs of the cervical spine and non-contrast computed tomographic (CT) scan of the brain appeared normal. An echocardiogram and carotid artery ultrasound examination were also unremarkable. A selective left vertebral and left common carotid arteriogram was performed. This

demonstrated that the distal portion of the left vertebral artery was irregular, this irregularity beginning at the C2 level and extending into the intracranial portion. There were high-grade stenoses in the vicinity of the left posterior inferior cerebellar artery origin, with reduced flow into that vessel (Figure 1). The mid and distal basilar artery vascular distribution was normal. The left carotid artery also was normal in appearance.

The patient's neurologic signs fluctuated dramatically over the following several hours. She displayed periods of complete resolution of findings, which were followed by recurrence of right hemiparesis, aphasia, and a right central facial nerve paralysis. The time frame of appearance and resolution of neurologic signs was dramatic, sometimes occurring in the space of several minutes. On one examination, the patient also displayed transient skew deviation of the eyes, upbeating nystagmus with attempts at upward gaze, and downward gaze paresis.

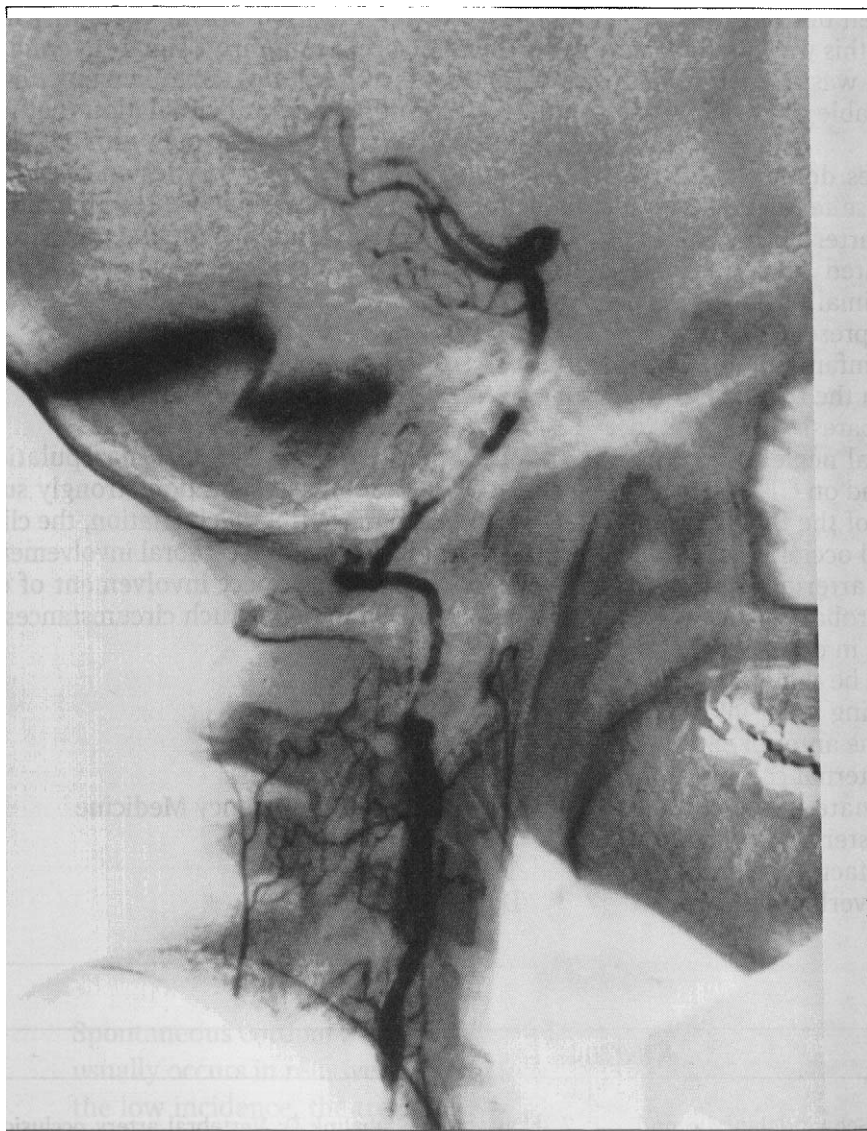
The patient was admitted to the hospital. Anticoagulation was instituted, with the initial intravenous administration of 3,000 units of heparin followed by a continuous intravenous heparin infusion. Her neurologic findings resolved completely over the following twenty-four hours. She was subsequently given a regimen of oral anticoagulation and discharged from the hospital without neurologic deficit five days after her admission.

### Discussion

The first instances of cerebrovascular accident associated with manipulation of the cervical spine were reported in 1927.<sup>1</sup> In 1947, 2 cases of death due to cerebellar necrosis following chiropractic manipulation were reported.<sup>2</sup> In the four decades that followed, 52 cases, in total, were reported in which vertebral arterial flow was impaired following therapeutic cervical manipulation.<sup>3</sup>

Vertebral artery injury has also been described following neck trauma, athletic injury, yoga, calisthenics, overhead work, and cervical traction.<sup>4-8</sup> The common feature of these activities is the application of hyperextension and rotation forces to the neck. This is also the mechanism considered to be responsible for vertebral artery injury following therapeutic manipulation.

The vascular injuries described have resulted in a variety of neurologic deficits. Reported



**Figure 1.** Vertebral arteriogram revealing diffuse narrowing and irregularity of the vertebral artery.

deficits have included those of Wallenberg's lateral medullary infarction syndrome (ipsilateral loss of pain and temperature sensation of the face, contralateral loss of such sensation on the body, Horner's syndrome, paralysis of the soft palate), "locked-in" syndrome (quadriplegia with preservation of blinking, vertical eye movements, and respiration), sixth nerve and other gaze palsies, visual field deficits, Horner's syndrome, and quadriplegia.<sup>9</sup> Symptoms typically include vertigo, slurred speech, diplopia, weakness, paresthesias, tinnitus, or ataxia.

The pathophysiology of the injury has been variously postulated to involve vascular intimal tearing, thrombus and intramural hematoma

formation, vasospasm, aneurysmal dissection, and embolization.<sup>9</sup> Where postmortem vascular evaluation has been performed, this has demonstrated intimal dissection with distal thrombus propagation.<sup>10</sup> The usual site of injury is in the extracranial portion of the vertebral artery at the C2 level.

Although the production of various brain stem syndromes in conjunction with cervical manipulation is well documented, the distinctive aspect of our case was the presentation with signs suggestive of dominant-hemisphere middle cerebral artery occlusion (aphasia and contralateral hemiparesis). Although internal carotid artery dissecting hematoma complicating cervical chiro-

practic manipulation has been described,<sup>11</sup> arteriography demonstrated that this was not the case here. The carotid circulation was free of lesions, whereas there was considerable abnormality of the vertebral system.

Chambers and colleagues described 12 patients with acute stroke whose features were indicative of middle cerebral artery occlusion but who in fact were demonstrated to have experienced occlusion of the proximal posterior cerebral artery.<sup>12</sup> These patients presented with clinical syndromes indicative of infarction of the opposite cerebral hemisphere in the territory of the middle cerebral artery (hemiparesis, hemisensory loss, hemianopsia, hemispatial neglect). However, all were subsequently found on CT scan or autopsy to have had infarction of the thalamus, inferomesial temporal lobe, and occipital lobe. The 3 patients who underwent arteriography also demonstrated severe vertebrobasilar occlusive disease. The cause of aphasia in dominant-hemisphere lesions was thought to be thalamic infarction, with hemiparesis resulting from infarction of the cerebral peduncles or the anterior segment of the posterior limb of the internal capsule.

Chambers' study illuminated the clinical overlap existing between posterior and middle cerebral arterial occlusion, a fact not commonly recognized. This circulatory overlap may explain

the clinical presentation of our case, in which there were predominantly signs of middle cerebral artery territory involvement, even though it was the vertebral circulation that was involved. Clinical signs that may provide clues that a posterior cerebral artery lesion is responsible for findings ordinarily produced by middle cerebral artery occlusion include the presence of Horner's syndrome, oculomotor palsy, or vertical gaze paresis.

### Conclusion

Although the history of cervical manipulation prior to this patient's presentation strongly suggested injury to the vertebral circulation, the clinical signs pointed to middle cerebral involvement. The clinician should suspect involvement of either vascular system under such circumstances.

George Sternbach, M.D.  
Department of Emergency Medicine  
Seton Medical Center  
1900 Sullivan Avenue  
Daly City, CA 94025

### References

1. Dekleyn D, Nieuwenhuys P: Schwindelanfalle und Nystagmus bei einer bestimmten Stellung des Kopfes. *Acta Otolaryng (Stockholm)* 11:155-157, 1927.
2. Pratt-Thomas HR, Berger KE: Cerebellar and spinal injuries after chiropractic manipulation. *JAMA* 133:600-603, 1947.
3. Sherman MR, Smialek JE, Zane WE: Pathogenesis of vertebral artery occlusion following cervical spine manipulation. *Arch Pathol Lab Med* 111:851-853, 1987.
4. DeBehnke DJ, Brady W: Vertebral artery dissection due to minor neck trauma. *J Emerg Med* 12:27-31, 1994.
5. Hanus SH, Homer TD, Harter DH: Vertebral artery occlusion complicating yoga exercises. *Arch Neurol* 34:574-575, 1977.
6. Nagler W: Vertebral artery obstruction by hyperextension of the neck. *Arch Phys Med Rehabil* 54:237-240, 1973.
7. Okawara S, Nibbelink D: Vertebral artery occlusion following hyperextension and rotation of the head. *Stroke* 5:640-642, 1974.
8. Suechting RL, French LA: Posterior inferior cerebellar artery syndrome following a fracture of the cervical vertebra. *J Neurosurg* 12:187-189, 1955.
9. Schellhas KP, Latchaw RE, Wendling LR: Vertebrobasilar injuries following cervical manipulation. *JAMA* 244:1450-1453, 1980.
10. Raskind R, North CM: Vertebral artery injuries following chiropractic cervical spine manipulation—case reports. *Angiology* 41:445, 1990.
11. Beatty RA: Dissecting hematoma of the internal carotid artery following chiropractic cervical manipulation. *J Trauma* 17:248-249, 1977.
12. Chambers BR, Brooder RJ, Donnan GA: Proximal posterior cerebral artery occlusion simulating middle cerebral artery occlusion. *Neurology* 41:385-390, 1991.