

Transient Cortical Blindness and Bioccipital Brain Lesions in Two Patients with Acute Intermittent Porphyruria

Hugo Kupferschmidt, MD; Adriano Bont, MD;
Hans Schnorf, MD; Theodor Landis, MD;
Eike Walter, MD; Jürg Peter, MD;
Stephan Krähenbühl, MD, PharmD;
and Peter J. Meier, MD

Ann Intern Med. 1995;123:598-600.

The most common neurologic manifestations of acute intermittent porphyria are autonomic visceral neuropathy, peripheral motor neuropathy, and central nervous system dysfunctions, including seizures and neuropsychiatric disturbances (1). In rare instances, however, patients with acute intermittent porphyria have presented with acute cortical blindness (2-5), for which deleterious vasospasm in both posterior cerebral arteries has been inferred (3,6).

We describe two patients in whom cortical blindness was the first symptom of acute intermittent porphyria. Magnetic resonance imaging showed extensive lesions involving primarily white matter of both occipital lobes consistent with vasospasm-induced ischemic lesions. However, the pathogenesis of the suspected vasospasm in acute intermittent porphyria is unknown. Because the enzyme nitric oxide synthase is a hemoprotein (7) and nitric oxide is a major vascular dilator (8), we hypothesize that severe heme deficiency during acute attacks may cause unopposed cerebral vasoconstriction due to a decrease in cerebral nitric oxide production.

From University Hospital, Zürich; University Hospital, Basel; and University Hospital, Geneva, Switzerland. For current author addresses, see end of text.

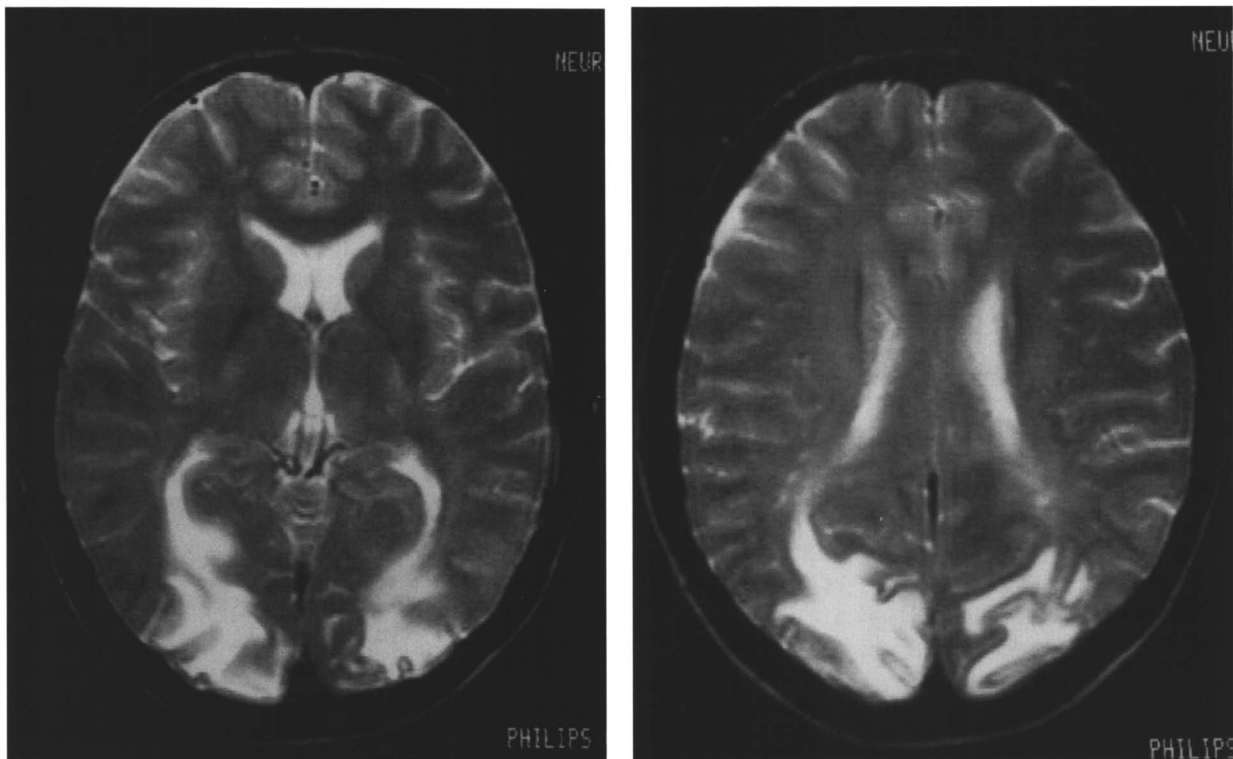


Figure 1. T₂-weighted axial magnetic resonance images in Patient 1. Large confluent areas of signal hyperdensities are present in the occipital cortex, including the calcarine cortex, and in the adjacent white matter.

Case Reports

Patient 1

A 35-year-old woman was hospitalized because of sudden loss of vision. With the exception of a brother with partial porphobilinogen deaminase deficiency, she had no family history of porphyria, and she had no known exposure to porphyrinogenic drugs. At admission, she appeared to be blind, was unable to see or fixate on any target (although she reacted to large moving targets), and could not see colors. The remainder of the neurologic examination was normal.

During the patient's first day in the hospital, she had two tonic-clonic seizures and was treated with carbamazepine and phenytoin. Computed tomography and magnetic resonance imaging showed multifocal lesions primarily in both occipital lobes (Figure 1). During the next 14 days, her vision was completely restored, but she developed flaccid tetraplegia. Electroneuromyography showed a pure axonal motor neuropathy. Routine biochemical assessments of serum and cerebrospinal fluid were normal. Urinary excretions of (δ -aminolevulinic acid (788 $\mu\text{mol/d}$; normal, $<50 \mu\text{mol/d}$), porphobilinogen (1346 $\mu\text{mol/d}$; normal, $<8 \mu\text{mol/d}$), uroporphyrin (369 nmol/d; normal, $<60 \text{nmol/d}$) and coproporphyrin III (701 nmol/d; normal, $<200 \text{nmol/d}$) were markedly increased. A diagnosis of acute intermittent porphyria was made and was confirmed by decreased porphobilinogen deaminase activity in lysed erythrocytes (51 pmol/h per mg protein; normal range, 60 to 150 pmol/h per mg protein). Plasma lead level was not elevated. She was treated with intravenous glucose (500 g/d) and heme-arginate (4 mg/kg body weight per day; three 6-day courses of daily infusions over a 7-week period),

and the biochemical and clinical signs of acute intermittent porphyria improved during the following 2 months. However, 6 months after the initial presentation, magnetic resonance imaging showed residual ischemic lesions in the bioccipital white matter. One year after the initial presentation, the patient had completely recovered.

Patient 2

A 32-year-old woman with no family history of acute intermittent porphyria and with no known exposure to porphyrinogenic drugs had abdominal hysterectomy because of a myoma. No known porphyrinogenic drugs were used for anesthesia. After this surgery, she had severe persisting abdominal pain and developed arterial hypertension (170/100 mm Hg), tachycardia (110 beats/min) and three generalized tonic-clonic seizures, for which she received phenytoin. She suddenly became blind but was unaware of her blindness (Anton syndrome [9]) and could correctly guess the direction of moving lights (Riddoch phenomenon [10]).

Axial T₁-weighted magnetic resonance images were compatible with cortical swelling, and T₂-weighted images showed several, probably ischemic, lesions in the white matter of both occipital lobes and the right frontal lobe (Figure 2). On the basis of increased urinary excretion of δ -aminolevulinic acid (526 $\mu\text{mol/d}$) and porphobilinogen (698 $\mu\text{mol/d}$), a diagnosis of acute intermittent porphyria was made. Plasma lead level was not measured. After the patient received treatment with intravenous glucose (300 g/d) and heme-arginate (3 mg/kg per day; two 6-day courses of daily infusions over a period of 3 weeks), visual disturbances improved, but peripheral motor neuropathy

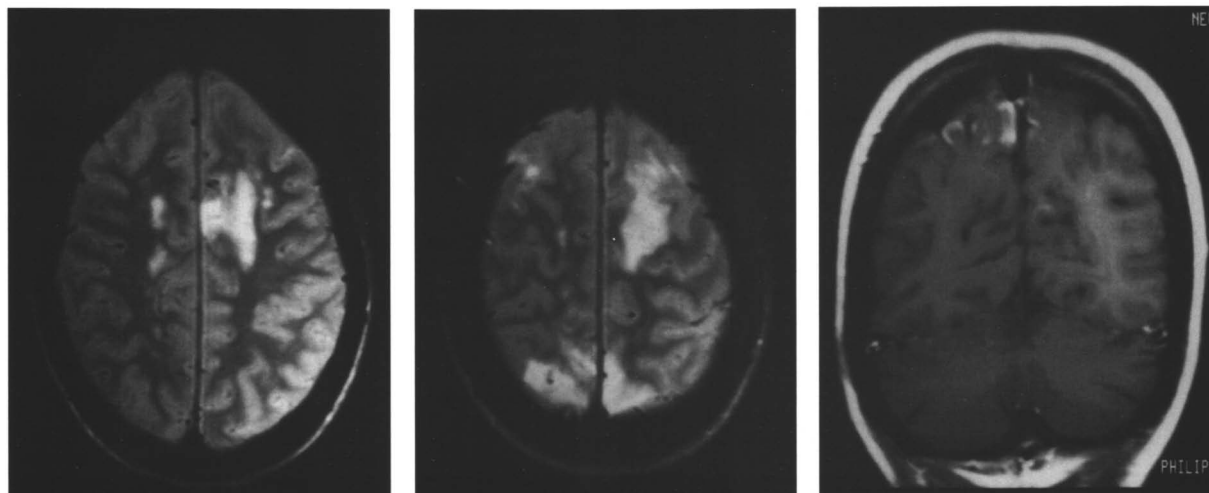


Figure 2. T₂-weighted axial magnetic resonance images in Patient 2. Patchy hyperdensities are present in both occipital lobes and in the precentral and frontal subcortical white matter. Additionally, right paracentral white matter hyperdensities are present (*left and middle panels*). T₁-weighted coronal sections show gadolinium enhancement along cortical gyri and sulci in the occipital paracentral cortex. Slight contrast enhancement of the left calcarine cortex is also present (*right panel*).

developed, progressing rapidly to flaccid tetraparesis. Urinary excretion of porphyrin precursors returned to normal after 3 weeks of therapy with intravenous heme-arginate and high-dose glucose. However, 4 weeks later, magnetic resonance imaging showed only minimal improvement. Vision returned to normal within 3 weeks, and the tetraparesis improved within 8 months to the point that the patient was able to resume an independent lifestyle.

Discussion

During the last 10 years, we have seen 18 patients with severe attacks of acute intermittent porphyria. Of these, the 2 patients described here were the only ones who presented with transient cortical blindness, repetitive tonic-clonic seizures, and a severe peripheral motor neuropathy. Furthermore, magnetic resonance imaging in both patients showed cerebral abnormalities consistent with bioccipital ischemic brain lesions. These observations support the concept that multifocal ischemia and cerebral microinfarctions, possibly resulting from porphyria-induced vasospasms, may be important causes of cerebral dysfunction during acute attacks of acute intermittent porphyria (3, 5, 6).

That bilateral spreading cerebral hypoperfusion (11) and occipital magnetic resonance imaging (12) are found in patients with migraine-associated visual disturbances supports the idea that the magnetic resonance imaging abnormalities seen in our two patients may have resulted from vasospasm-induced ischemia. However, the pathogenesis of the suspected cerebral vasoconstriction in acute intermittent porphyria is unknown. Interestingly, the recently characterized enzyme nitric oxide synthase is a cytochrome P-450 type hemoprotein (7) whose activity may be reduced in situations of decreased heme production such as acute intermittent porphyria. Because nitric oxide is an established and important vasodilator in the central nervous system (8), decreased cerebral nitric oxide production in patients with acute intermittent porphyria

may be associated with unopposed cerebral vasoconstriction, potentially leading to lesions in brain areas that are particularly vulnerable to hypoxia.

Requests for Reprints: Peter J. Meier, MD, Division of Clinical Pharmacology and Toxicology, Department of Medicine, University Hospital CH-8091, Zurich, Switzerland.

Current Author Addresses: Drs. Kupferschmidt, Krähenbühl, and Meier: Division of Clinical Pharmacology and Toxicology, Department of Medicine, University Hospital, CH-8091, Zürich, Switzerland.

Dr. Bont: Neurologische Universitätsklinik, Kantonsspital, Petersgraben 4, CH-4031, Basel, Switzerland.

Drs. Schnorf and Landis: Hôpital Cantonal de Gève, Service de Neurologie, Rue Hicheli du Crest 24, 1211, Genève, 14, Switzerland.

Dr. Walter: Medizinische Universitätsklinik, Abt. Innere Medizin II, Hugstetter Straße 55, D-79106, Freiburg, Germany.

Dr. Peter: Spital Limmattal, 8952 Schlieren, Medizinische Abteilung, Switzerland.

References

1. Bonkowsky HL, Schady W. Neurologic manifestations of acute porphyria. *Semin Liv Dis.* 1982;2:108-24.
2. Goldstein NP, Martin WJ, Brunsting LA, Kirby TJ. Blindness of cerebral origin in porphyria: report of a case. *Mayo Clin Proc.* 1957; 32:82-7.
3. Lai CW, Hung TP, Lin WS. Blindness of cerebral origin in acute intermittent porphyria. Report of a case and postmortem examination. *Arch Neurol.* 1977;34:310-2.
4. Sato M, Tomizaki Y. A case of transient cerebral blindness in acute intermittent porphyria. *Folia Ophthalmol Jpn.* 1992;4:1378-81.
5. King PH, Bragdon AC. MRI reveals multiple reversible cerebral lesions in an attack of acute intermittent porphyria. *Neurology.* 1991;41: 1300-2.
6. Hierons R. Changes in the nervous system in acute porphyria. *Brain.* 1957;80:176-92.
7. White KA, Marletta MA. Nitric oxide synthase is a cytochrome P-450 type hemoprotein. *Biochemistry.* 1992;31:6627-31.
8. Lowenstein CJ, Snyder SH. Nitric oxide, a novel biologic messenger. *Cell.* 1992;70:705-7.
9. Anton G. Ueber Herderkrankungen des Gehirns, welche vom Patienten selbst nicht wahrgenommen werden. *Wiener Klin Wochenschr.* 1898;11:227-9.
10. Riddoch G. Dissociation of visual perceptions due to occipital injuries, with special reference to appreciation of movement. *Brain* 1917;40:15-57.
11. Woods RP, Iacoboni M, Mazzotta JC. Brief report: bilateral spreading cerebral hypoperfusion during spontaneous migraine headache. *N Engl J Med* 1994;331:1689-92.
12. Kuhn MJ, Shekar PC. A comparative study of magnetic resonance imaging and computed tomography in the evaluation of migraine. *Comput Med Imaging Graph.* 1990;14:149-52.