

Stroke Following Injection of a Melted Suppository

Saad Bitar, MD, and Camilo R. Gomez, MD

Background and Purpose: Stroke following the intravenous injection of drugs may be secondary to the direct effect of the substance itself or from embolization by the inert vehicle used in the manufacturing process of the drug.

Case Description: We describe a 39-year-old man who developed a left homonymous hemianopia after intravenous injection of a melted suppository.

Conclusions: Paradoxical fat embolism should be added to the possible list of stroke mechanisms in intravenous drug abusers. (*Stroke* 1993;24:741-743)

KEY WORDS • embolism • substance abuse

Cases of stroke secondary to the intravenous injection of various substances, particularly cocaine and other sympathomimetic drugs, continue to be reported in the literature.¹⁻⁷ In general, these patients are believed to suffer the direct effects of the drug being injected. In a minority of instances, however, the inert vehicle used in the manufacture of medications may cause embolization and stroke.^{5,6} We report a case of ischemic stroke following intravenous injection of a melted suppository by a young drug addict.

Case Report

A 39-year-old man arrived at the ophthalmology clinic of Saint Louis University Medical Center exhibiting "vision changes" approximately 20 hours after injecting himself intravenously with two melted hydromorphone hydrochloride (Dilaudid; Knoll Pharmaceuticals, Whippany, N.J.) suppositories. Examination disclosed a left homonymous hemianopia, and he was transferred for neurological evaluation.

The patient, a registered nurse by profession, had been an intravenous opiate addict for many years and had recently been injecting himself intravenously with crushed hydromorphone tablets diluted in water. The day before admission, not having any more tablets, he melted two suppositories in hot water and injected them into his right antecubital vein. Retrospectively, he recalled observing a "layer of fat" floating in the syringe. Immediately after the injection, he noticed a burning sensation in his palms and soles, numbness around his lips, substernal chest pain, abdominal cramps, and "tunneling" of vision. These symptoms were followed by severe emesis that ceased when he went to sleep. The

next morning, he remained nauseated and noted an inability to see to his left with either eye. The nausea improved over a few hours, but the persistence of his visual difficulty prompted him to seek medical attention. His past medical history was significant for Wolff-Parkinson-White syndrome and hyperlipidemia type IV. There was no history of previous neurological disorders. His medications included digoxin, trazodone, and verapamil, and he was receiving methadone as part of a detoxification program.

When first seen, his blood pressure was 150/92 mm Hg in the supine position, and his pulse was 80 beats per minute and regular. His heart examination revealed a I/VI systolic murmur at the apex without radiation. The rest of his general examination was normal. Neurological examination revealed normal mental status. Cranial nerve examination was remarkable only for a congruous left homonymous hemianopia. Motor, sensory, and coordination examinations were intact. Muscle stretch reflexes were normally active, symmetrical, and accompanied by flexor plantar responses. The patient was able to walk on heels, toes, and tandem without difficulty.

A head computed tomographic scan without contrast (Figure 1) was obtained approximately 24 hours after the suppository injection, and the results were thought to be consistent with a right occipital infarction. The patient's serum cholesterol level was 194 mg/dL, triglycerides were 193 mg/dL, and erythrocyte sedimentation rate was 40 mm/hr, but the rest of the laboratory studies were normal. Transthoracic contrast echocardiography, including injection of microbubbles during Valsalva maneuver and coughing, failed to demonstrate an intracardiac right-to-left shunt. Repeated blood cultures were negative. The patient refused to have many laboratory studies, including spinal fluid examination, immunologic blood tests, transesophageal echocardiography, and cerebral angiography. Four days after admission, he left the hospital, discharging himself against medical advice. He was seen in the outpatient clinic approximately 9 months later; he continued to

From The Souers Stroke Institute, Department of Neurology, Saint Louis University Medical Center, St. Louis, Mo.

Address for correspondence: Camilo R. Gomez, MD, The Souers Stroke Institute, 3635 Vista at Grand Avenue, St. Louis, MO 63110.

Received August 28, 1992; final revision received February 1, 1993; accepted February 1, 1993.

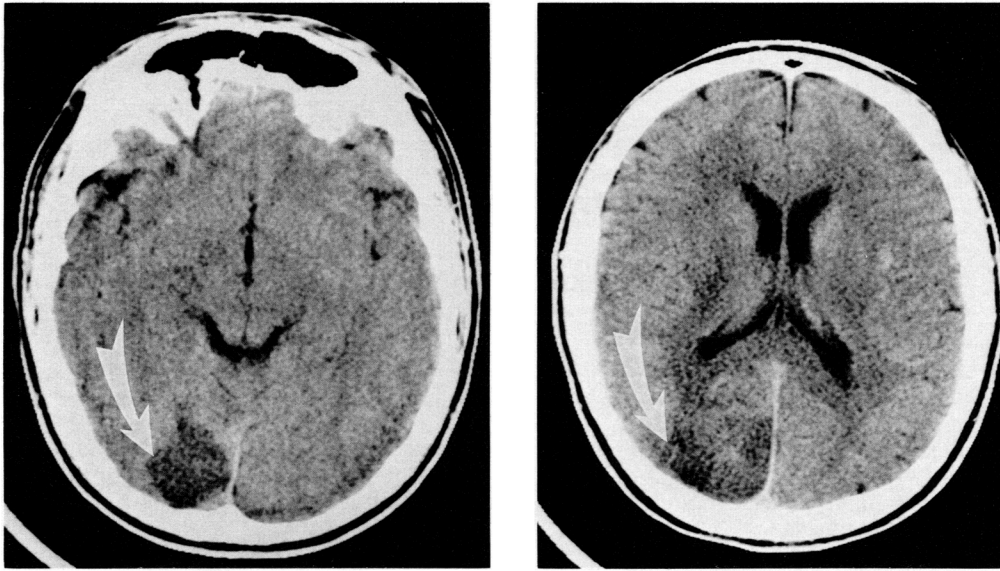


FIGURE 1. Admission computed tomographic scan of patient showing evidence of a right occipital infarction (arrow).

refuse further evaluation and denied any additional symptoms. The homonymous hemianopia persisted.

Discussion

Stroke is a well-known complication of intravenous drug abuse,¹⁻⁴ and several possible mechanisms may explain the clinical picture of our patient. First, the elevation of the erythrocyte sedimentation rate suggests the coexistence of an infectious, inflammatory, or autoimmune process. The lack of echocardiographic or microbiological evidence for bacterial endocarditis practically discards this as the possible source of embolism. Ideally, transesophageal echocardiography would have assisted in documenting the absence of vegetations and other potential sources of cardiogenic embolism.⁸ Unfortunately, owing to the patient's refusal, this could not be done. Hypersensitivity vasculitis could also explain the elevated erythrocyte sedimentation rate, while being a potential cause of the stroke. Angiitis reported in the context of amphetamine abuse⁹ has been shown to affect the central nervous system but with an inherent predilection for involvement of arterioles, capillaries, and venules. However, patients affected by hypersensitivity vasculitis usually exhibit a protracted clinical course that includes many systemic and neurological symptoms.⁹ In our patient, the rapid occurrence of the stroke after the injection, the restricted involvement of a large cerebral artery, and the lack of recurrent or progressive symptomatology make vasculitis an unlikely cause of the stroke.

A second possibility is that during melting of the suppository, chemical changes of its components occurred, and the newly formed substances induced a systemic chemical reaction that affected the brain. Hydromorphone is a hydrogenated ketone of morphine, formulated in 3-mg rectal suppositories that include cocoa butter as the main inactive ingredient.¹⁰ An extensive search of the literature failed to provide information about the effects of heating any of these substances. Finally, direct consultation with an expert in toxicology revealed that neither hydromorphone nor cocoa butter was likely to be changed into a different chemical com-

pound by the temperature required for melting the suppository (A. Poklis, personal communication).

A third possible explanation for the mechanism of stroke is the induction of vasospasm by the substances being injected. Rumbaugh et al, following their own findings of segmental arterial constrictions in drug abusers,¹¹ induced similar angiographic changes in monkeys within 10 minutes of intravenous injection of methedrine.¹² It is unclear whether these changes represented the direct effect of the drug or a response to the concurrent systemic hypertension in the animals. Vasospasm cannot be completely excluded as the cause of our patient's stroke because his evaluation was incomplete. The lack of angiographic and transcranial Doppler assessments, either of which may have helped probe this hypothesis, cannot be overcome.

Finally, although drug abusers usually suffer the direct toxic effects of the drug injected, embolization of the brain by foreign material mixed with the primary substance has been documented at autopsy.⁵⁻⁷ An example of this, common across the United States in the 1970s and 1980s, was the use of pentazocine hydrochloride (Talwin) and tripeleminamine hydrochloride (Pyribenzamine), also known as "Ts and blues." The oral tablets were crushed, suspended in water, filtered (usually with cotton), and injected intravenously. Pulmonary arteriolar occlusion by microcrystalline cellulose¹³ or particulate magnesium silicate (talc),¹⁴ often associated with production of pulmonary granulomata,¹⁵ was a common autopsy finding in these individuals. Cerebral infarction and hemorrhage were also reported in relation to repeated intravenous injections of Ts and blues.¹⁶

In our patient, we postulate the occurrence of a paradoxical fat embolism of the right posterior cerebral artery. This could have resulted from emulsification of the cocoa butter contained in the suppository, or its separation into lipid and nonlipid components, after intravenous injection. Fat embolization of the lung is extremely common after traumatic injuries of long bones, even though there may be no symptomatology.¹⁷ In the absence of an intracardiac right-to-left shunt, it is possible for multiple microemboli to reach the brain after passage through the lungs,¹⁸ especially if they induce

pulmonary hypertension leading to the opening of functional arteriovenous shunts.¹⁹ Although we have no direct evidence, it is possible that some of the systemic symptoms (e.g., chest pain and nausea) may have reflected acute pulmonary hypertension, thus permitting paradoxical embolization through an occult pulmonary arteriovenous shunt and occipital lobe infarction.

It is impossible to be sure which of these mechanisms was responsible for our patient's stroke because he was not fully evaluated. However, this case underscores the complexity of stroke occurring in the setting of intravenous drug abuse and the need for intensive diagnostic evaluation to clarify mechanisms.

Acknowledgment

The authors wish to express their appreciation to Dr. Alphonse Poklis, Department of Pathology and Toxicology, Medical College of Virginia, for his invaluable expert assistance.

References

- Sloan MA, Kittner SJ, Rigamonti D, Price TR: Occurrence of stroke associated with use/abuse of drugs. *Neurology* 1991;41:1358-1364
- Kaku DA, Lowenstein DH: Emergence of recreational drug abuse as a major risk factor for stroke in young adults. *Ann Intern Med* 1990;113:821-827
- Jensen R, Olsen TS, Winther BB: Severe non-occlusive ischemic stroke in young heroin addicts. *Acta Neurol Scand* 1990;81:354-357
- Diaz-Tejedor E, Tejada J, Frank A: Neurologic complications caused by use of cocaine, amphetamines and sympathomimetics. *Arch Neurobiol* 1989;52:162-182
- Atleel W: Talc and cornstarch emboli in eyes of drug abusers. *JAMA* 1972;219:49-51
- Mizutami T, Lewis R, Gonatae N: Medial medullary syndrome in a drug abuser. *Arch Neurol* 1980;37:425
- Sapira JD: The narcotic addict as a medical patient. *Am J Med* 1968;45:555-588
- Gomez CR, Labovitz AJ: Transesophageal echocardiography in the etiologic diagnosis of stroke. *J Stroke Cerebrovasc Dis* 1991;1:81-87
- Citron BP, Halpern M, McCarron M, Lundberg GD, McCormick R, Pincus IJ, Tatter D, Haverbeck BJ: Necrotizing angitis associated with drug abuse. *N Engl J Med* 1970;283:1003-1011
- Ellenhorn MJ, Barceloux DG: *Medical Toxicology: Diagnosis and Treatment of Human Poisoning*. New York, Elsevier Science Publishing Co Inc, 1988
- Rumbaugh CL, Bergeron RT, Fang HCH, McCormick R: Cerebral angiographic changes in the drug abuse patient. *Radiology* 1971;101:335
- Rumbaugh CL, Bergeron RT, Scanlon RL, Teal JS, Segall HD, Fang HC, McCormick R: Cerebral vascular changes secondary to amphetamine abuse in experimental animals. *Radiology* 1971;101:345
- Houck RJ, Baily G, Caroca P, Brazda F, Johnson FB, Klein RC: Pentazocine abuse. *Chest* 1980;77:227-230
- Szwed JJ: Pulmonary angiothrombosis caused by "blue velvet" addiction. *Ann Intern Med* 1970;73:771-774
- Poklis A, Case MES, Ridenour GC: Abuse of pentazocine/tripelenamine combination: T's and Blues in the city of St. Louis, Missouri. *Medicine* 1983;80:21-23
- Caplan LR, Thomas C, Bauer G: Central nervous system complication of addiction to "T's and Blues." *Neurology* 1982;32:623-628
- Szabo G: The syndrome of fat embolism and its origin. *J Clin Pathol* 1970;23(suppl 4):123-131
- Watson AJ: Genesis of fat emboli. *J Clin Pathol* 1970;23(suppl 4):132-142
- Caplan LR, Hier DB, Bantes G: Stroke and drug abuse. *Stroke* 1982;13:869-872

Stroke following injection of a melted suppository.
S Bitar and C R Gomez

Stroke. 1993;24:741-743

doi: 10.1161/01.STR.24.5.741

Stroke is published by the American Heart Association, 7272 Greenville Avenue, Dallas, TX 75231

Copyright © 1993 American Heart Association, Inc. All rights reserved.

Print ISSN: 0039-2499. Online ISSN: 1524-4628

The online version of this article, along with updated information and services, is located on the
World Wide Web at:

<http://stroke.ahajournals.org/content/24/5/741>

Permissions: Requests for permissions to reproduce figures, tables, or portions of articles originally published in *Stroke* can be obtained via RightsLink, a service of the Copyright Clearance Center, not the Editorial Office. Once the online version of the published article for which permission is being requested is located, click Request Permissions in the middle column of the Web page under Services. Further information about this process is available in the [Permissions and Rights Question and Answer](#) document.

Reprints: Information about reprints can be found online at:
<http://www.lww.com/reprints>

Subscriptions: Information about subscribing to *Stroke* is online at:
<http://stroke.ahajournals.org/subscriptions/>